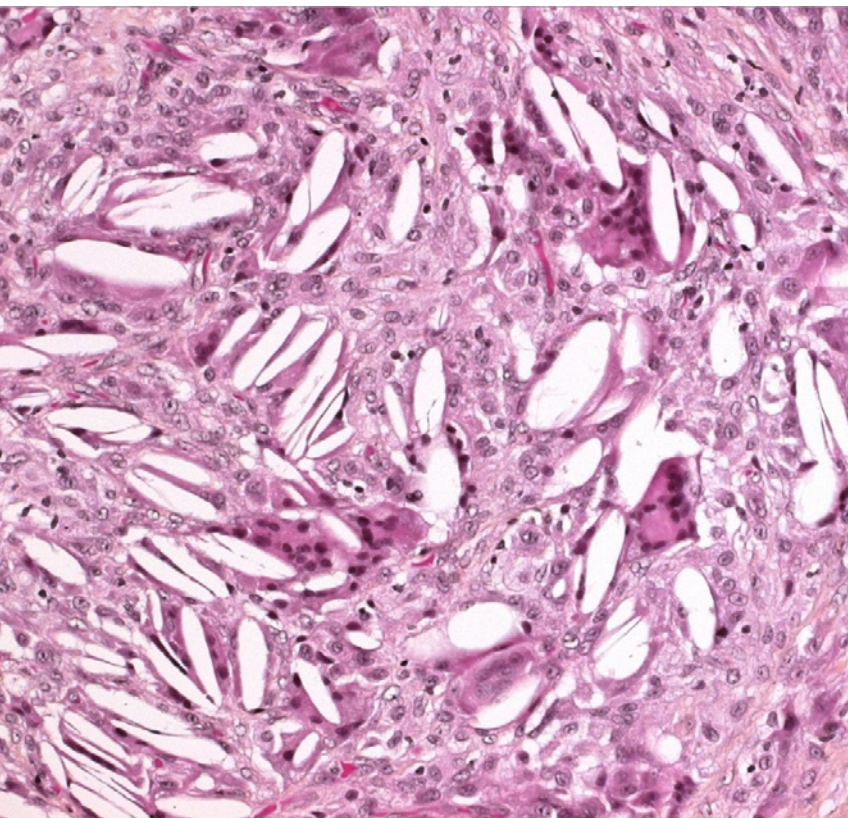


Subcutaneous fat necrosis:
clinical presentation and
pathophysiological aspects
of altered calcium
homeostasis

April 2017



Juvet C, Aijjou A, Diebold P, Service de Pédiatrie (JC, AA, DP), Hôpital d'Aigle, Hôpital Riviera-Chablais, Aigle, Switzerland

Title figure:

Cholesterol crystals (clefts) and multinucleated giant cells
(Source: www.humpath.com)

This female infant was born after an uncomplicated pregnancy at 41 5/7 weeks of gestation to a 31-year-old mother. Screening examinations had been unremarkable except for positive GBS cultures for which the mother was treated with 3 doses of antibiotics prior to delivery. Membranes had ruptured 9 hours before birth and amniotic fluid was noted to be meconium-stained. Vaginal delivery was vacuum-assisted because of failure to progress and shoulder dystocia. Her birth weight was 4220 g (P 90–95).

Initially, she had no spontaneous breathing, was hypotonic and non-reactive. She was stimulated, suctioned and bag-mask ventilated, first with an FiO_2 of 21%, then up to 100% for 5 minutes. Apgar scores were 2, 4 and 6 at 1, 5 and 10 minutes, respectively. Arterial and venous umbilical cord pH values were 7.16 and 7.21, respectively. At 5 minutes of life, there was spontaneous breathing, and CPAP treatment was initiated with a PEEP of 5 cmH_2O . At 10 minutes of life, she still presented respiratory distress, with suprasternal, intercostal and subcostal retractions, as well as nostril flaring; SpO_2 was 89–92% in room air. She was hypotonic with a diminished reactivity, but her heart rate always remained above 100 beats per minute and blood pressure was normal.

At 30 min of life, there was marked mixed acidosis with a pH of 6.93, a pCO_2 of 10.7 kPa (80 mmHg), a bicarbonate of 9.5 mmol/l, a BE of -14.8 mmol/l,

and a lactate of 10.7 mmol/l. Because of hypoglycemia (blood glucose 1.9 mmol/l) dextrose 10% was started. Arterial hypotension (MAP 29 mmHg) responded to a single fluid bolus.

On physical examination, right-sided upper brachial plexus palsy was noted. In addition, a discrete indurated lesion on the distal part of the left arm appeared 48 hours later. A chest X-ray showed no signs of pneumothorax or meconium aspiration. She rapidly recovered and was discharged home at 7 days of life with a prescription for Vitamin D3 400 UI/day.

One week later, she was referred to the hospital by her pediatrician because of numerous indurated skin lesions, similar to the one noted initially on her left arm. On admission, several indurated, red-purplish subcutaneous lesions, located predominantly on the trunk and the arms were noted (Fig. 1 – 3). A diagnosis of a subcutaneous fat necrosis was made.

Laboratory examinations were normal except for thrombocytosis (736 G/l). Serum calcium levels were elevated, but with a significant discrepancy between measured and calculated ionized calcium concentrations (Table 1). 25-OH-vitamin D2/D3 was normal (63.9 mmol/l), whereas parathyroid hormone was markedly decreased (0.7 pmol/l, normal 1.3-6.8 pmol/l). Alkaline phosphatase was within the normal range.

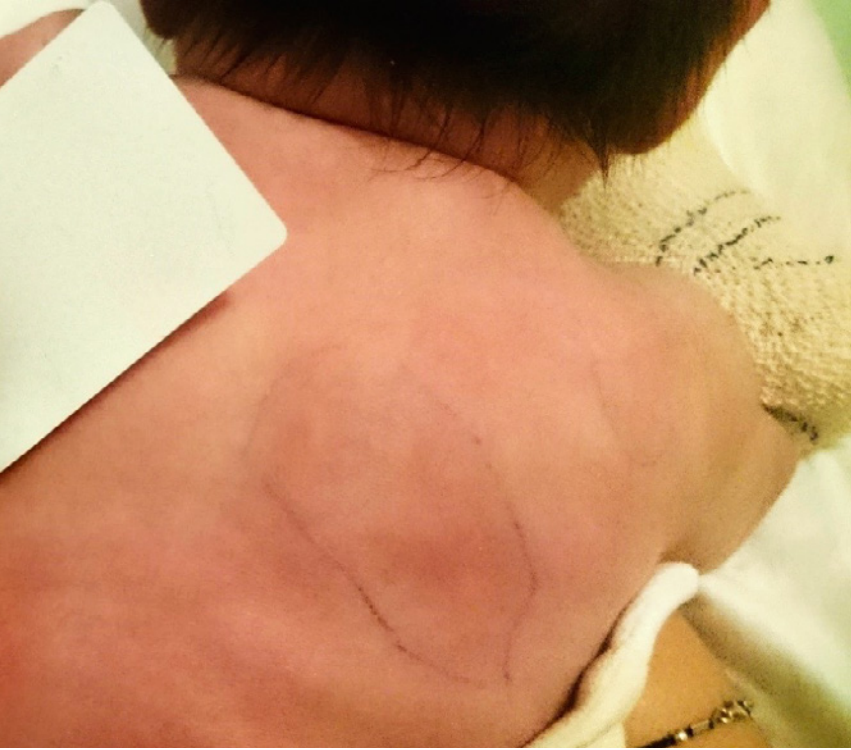

Fig. 1

Indurated, red to purplish skin lesions on the trunk at 14 days of life.

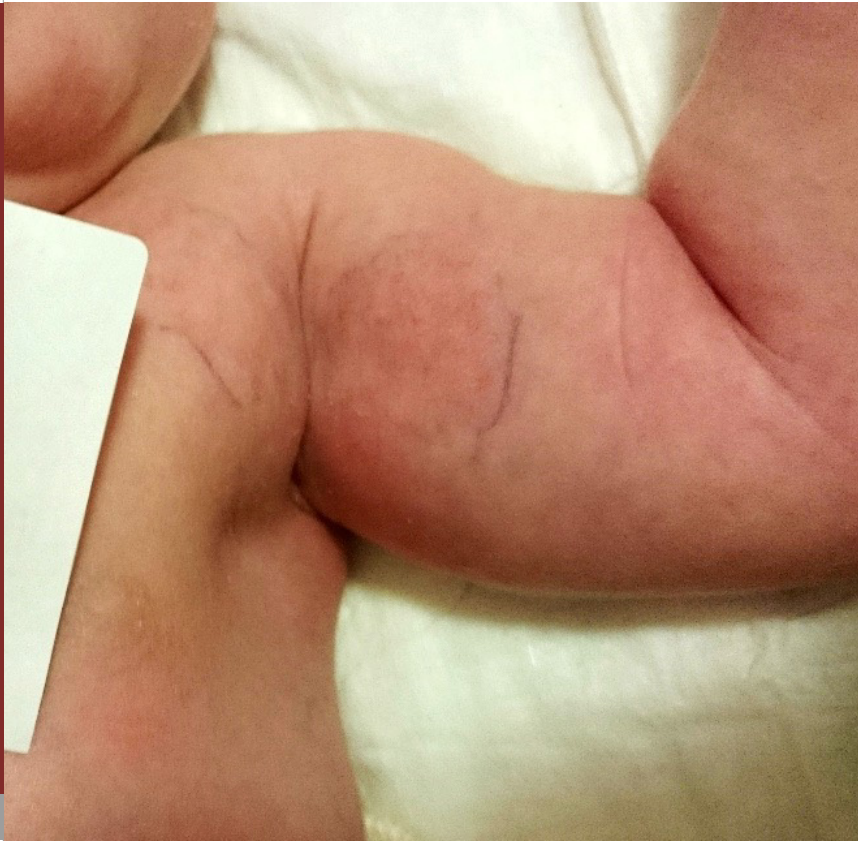

Fig. 2

Indurated, red to purplish skin lesions on the left arm and axilla at 14 days of life.

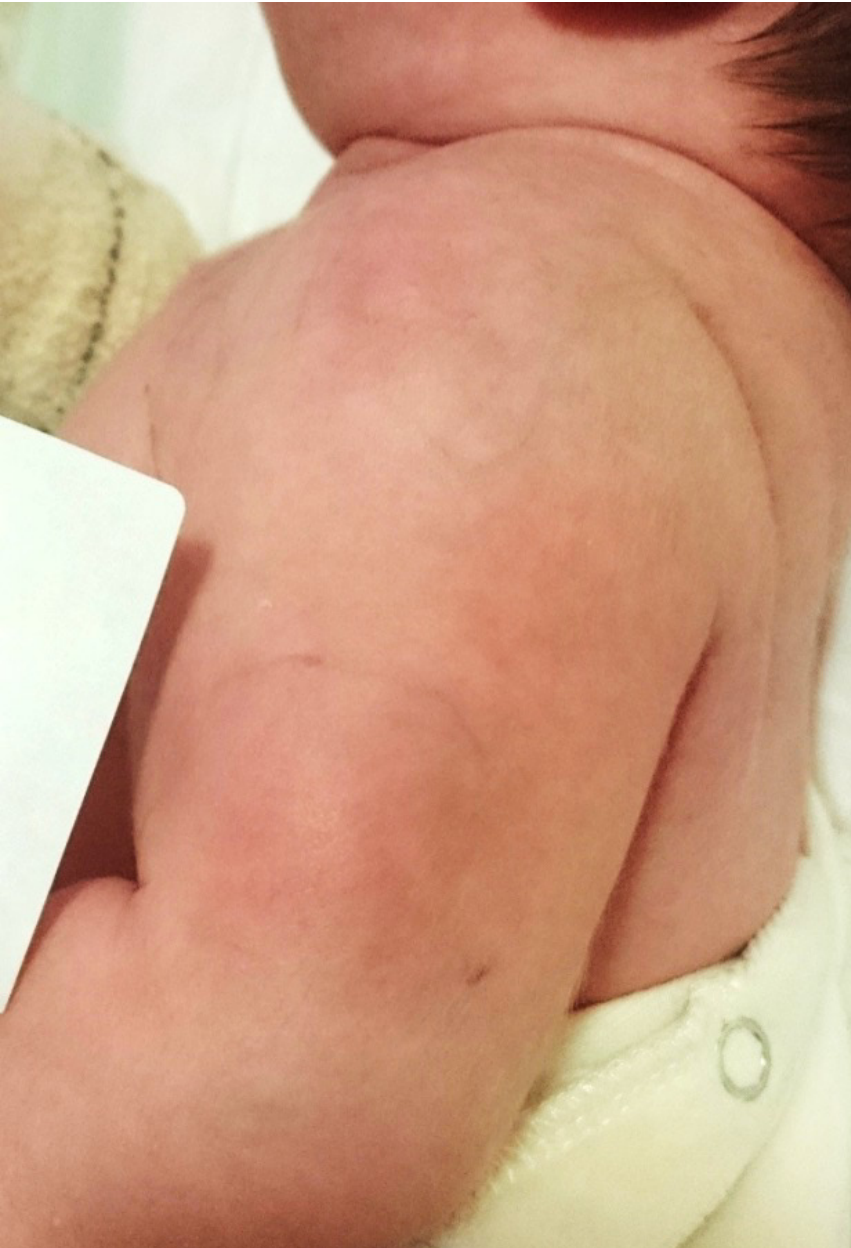

Fig. 3

Indurated, red to purplish skin lesions on the left arm at 14 days of life.

	Measured ionized calcium (mmol/l) (normal 1.17–1.32)	Calculated ionized calcium (mmol/l) (normal 1.17–1.32)	Albumin (g/l)	pH
DOL 14	1.33	1.94	35.7	7.41
DOL 15	1.40	1.87	36.8	7.47

Table 1. *Measured and calculated ionized calcium concentrations and parameters with influence on ionized calcium level.*

On ultrasound examination, the subcutaneous lesions were hypoechogetic, homogeneous without any evidence of calcification, hypervascularization or abscess formation.

Based on the measured ionized calcium concentrations, which were felt to be more relevant than calculated values (see discussion), hypercalcemia was considered to be mild; treatment consisted of volume expansion and interruption of vitamin D supplementation. Measured ionized calcium was monitored regularly and showed no significant changes over the course of several months (Fig. 4).

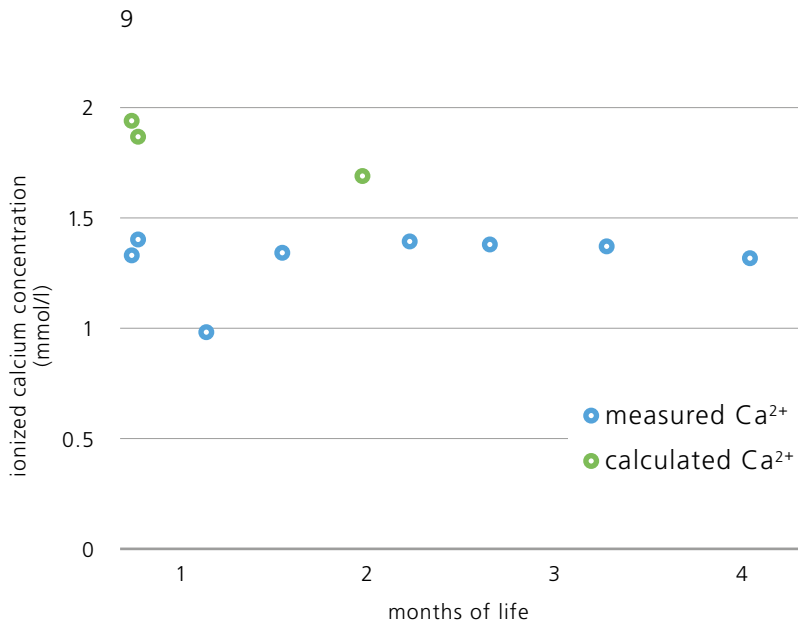


Fig. 4

Evolution of blood calcium concentrations over the first months of life.

DISCUSSION

Subcutaneous fat necrosis (SFN) is a rare form of panniculitis presenting with purplish-erythematous indurated nodules and plaques in the first weeks of life; it is typically located on the face, bottom, arms, thighs and trunk. It is usually seen in term or near term infants (1). Several risk factors have been reported in the literature, including macrosomia, perinatal trauma, asphyxia, (therapeutic) hypothermia, gestational diabetes, preeclampsia and hypoglycemia (1–9). The incidence of SFN in children undergoing therapeutic hypothermia is about 1%, and thus much higher than in the general neonatal population (5). It is very likely that hypothermia favors SFN as it facilitates fat crystallization (see below). Notably, many of these risk factors can occur simultaneously, and, given the low incidence of SFN, it is difficult to assess whether they are independent of each other.

The diagnosis of SFN mostly relies on its clinical presentation. However, histological examination is sometimes performed when lesions are not unequivocal. It typically shows fat cell necrosis, along with needle-shaped crystals or clefts and inflammatory cell infiltration, including multinucleated giant cells. These crystals are mostly found in fat cells (1), but occasionally described in multinucleated giant cells (6). Calcium deposition is inconsistently being reported (3, 6). Interestingly, Tran et al. reported on calcifications found incidentally at 1 month of life in the context of marked hypercalcemia, while SFN lesions had resolved and biopsy in the ini-

tial phase had failed to show calcium depositions. This indicates that calcification could be a later event, possibly linked to hypercalcemia (3).

The differential diagnosis of SFN includes sclerema neonatorum (SN), lipogranulomatosis and cold panniculitis (4). Like SFN, SN appears in the first few days of life, but it is always associated with severe disorders and bad outcome (1). Histological findings also differ: while crystals are usually present, necrosis, inflammation and giant cells are usually absent (2, 3).

Hypercalcemia is the most feared complication of SFN and can occur up to 6 months after the resolution of the skin lesions. Clinically, patients may present with lethargy, hypotonia and poor feeding. Persistent hypercalcemia can lead to nephrocalcinosis with subsequent renal failure. This complication has predominantly been described in the most severely affected children; it usually resolves over a period of several months (9).

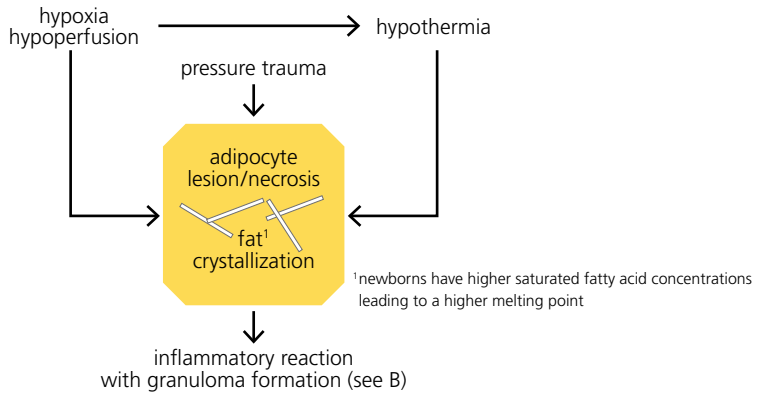
Other complications that have been described in patients with SFN include thrombocytopenia, hypertriglyceridemia, hypoglycemia, and late subcutaneous lipoatrophy (3–6, 9). Thrombocytopenia usually appears before or concomitantly with the skin lesions (3), and, given the fact that bone marrow examinations are usually unremarkable, is thought to be of peripheral origin, such as sequestration (10). Dysli-

pidemia is inconsistently observed. While changes in fat composition in newborns are an element in the current understanding of SFN, as will be discussed below, it is unclear whether dyslipidemia is a cause or a consequence of SFN, or even an unrelated finding. In a case series of 16 patients with SFN, 9 patients (56%) developed hypercalcemia, 1 patient (6%) renal failure, and 1 patient (6%) dyslipidemia. Notably, all of the 6 children available for long-term follow-up had developed subcutaneous atrophy (9).

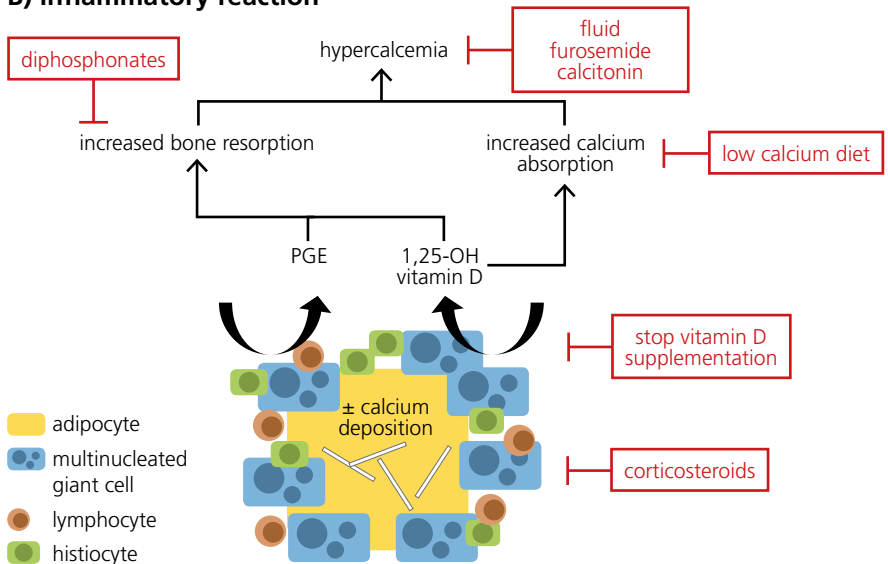
The pathophysiology SFN is only incompletely understood (Fig. 5). However, the fatty acid composition of neonatal adipocytes may play an important role: higher saturated fatty acid concentrations result in a higher melting point, and therefore facilitate crystallization in conditions of hypothermia (either in the context of asphyxia and hypoperfusion or induced (i.e., therapeutic) hypothermia) (3, 5, 7, 8, 10).

Necrosis and crystal formation lead to the formation of granulomatous tissue with multinucleated giant cells. These cells are also present in other diseases, such as sarcoidosis, tuberculosis or silicone-induced granulomas. In these conditions, they are known to 1-hydroxylate and therefore activate 25-OH vitamin D (3, 6), potentially leading to hypercalcemia. Published data on 1,25-OH vitamin D are not unequivocal as both high and normal levels have been described. However, considering the PTH suppression observed in

A) primary insult



B) inflammatory reaction



Principal hypotheses of SFN pathophysiology and potential treatment options (red boxes):

*A) primary insult with adipocyte lesions and necrosis;
B) inflammatory reaction with multinucleated giant cells, lymphocytes and histiocytes.*

Fig. 5

this context, even normal levels can be considered as elevated, (3, 4, 6, 7, 11).

Another hypothesis to explain hypercalcemia relates to enhanced prostaglandin E (PGE) production, causing increased bone resorption (3, 4, 6).

Vitamin D levels were normal in our patient, but only 25-OH-vitamin D₂-D₃ was measured, which does not represent the most active form, which is 1,25-OH vitamin D. Decreased PTH levels measured in our patient suggest that the increase in calcium concentration was mediated by another molecule than PTH (1,25-OH vitamin D and/or PGE). An increased tubular phosphate reabsorption rate of 99.85% (normal 78–97%) with normal serum phosphate levels might indicate increased 1,25-OH vitamin D activity.

We observed marked differences between measured and calculated ionized calcium (Table 1). The calculated ionized calcium concentration is derived from the measured total calcium concentration and albumin concentration. Notably, automated calculations use the higher adult albumin norms (therefore considering normal neonatal albumin levels as hypoalbuminemia), and consequently overestimate ionized calcium concentrations. Furthermore, this method does not correct for pH deviations. Alkalosis and acidosis, however, have a significant impact on calcium-protein binding. For these reasons, measured ionized calcium

concentrations are likely to be more reliable than calculated ionized calcium concentrations.

CONCLUSION

SFN is a rare form of neonatal panniculitis, which should be kept in mind when evaluating a child with indurated skin lesion and history of perinatal asphyxia and/or trauma. SFN can frequently be diagnosed based on clinical presentation alone. In cases of atypical presentation, a skin biopsy can confirm the diagnosis. The most important complication of SFN is hypercalcemia, which requires monitoring over several months, as it can occur up to 6 month of age. Prognosis of these skin lesions is very good as they usually resolve spontaneously without sequelae, except for possible lipoatrophy.

See also **COTM 02 2003**: subcutaneous fat necrosis of the newborn.

1. Burden AD, Krafchik BR. Subcutaneous fat necrosis of the newborn: a review of 11 cases. *Pediatr Dermatol* 1999;16:384–387 (*Abstract*)
2. Parvathidevi GK, Vijayashankar MR, Belagavi CS, et al. Cytological diagnosis of subcutaneous fat necrosis of newborn: a case report. *Dermatol Online J* 2005;11:20 (*Abstract*)
3. Tran JT, Sheth AP. Complications of subcutaneous fat necrosis of the newborn: a case report and review of the literature. *Pediatr Dermatol* 2003;20:257–261 (*Abstract*)
4. Barbier C, Cneude F, Deliège R, El Kohen R, Kremy O, Leclerc F. Subcutaneous fat necrosis in the newborn: a risk for severe hypercalcemia. *Arch Pediatr* 2003;10:713–715 (*Abstract*)
5. Martins J, Maxaud A, Bah AG, Prophette B, Maillard H, Bénétou N. Subcutaneous fat necrosis after moderate therapeutic hypothermia in two newborns of African origin. *Arch Pediatr* 2015;22:191–194 (*Abstract*)
6. Cook JS, Stone MS, Hansen JR. Hypercalcemia in association with subcutaneous fat necrosis of the newborn: studies of calcium-regulating hormones. *Pediatrics* 1992;90:93–96 (*Abstract*)
7. Karochristou K, Siahaniidou T, Kakourou-Tsivitanidou T, Stefanaki K, Mandyla H. Subcutaneous fat necrosis associated with severe hypocalcaemia in a neonate. *J Perinatol* 2006;26:64–66 (*Abstract*)
8. Vonk J, Janssens PM, Demacker PN, Folkers E. Subcutaneous fat necrosis in a neonate, in association with aberrant plasma lipid and lipoprotein values. *J Pediatr* 1993;123:462–464 (*Abstract*)

9. Mahé E, Girszyn N, Hadj-Rabia S, Bodemer C, Hamel-Teillac D, De Prost Y. Subcutaneous fat necrosis of the newborn: a systematic evaluation of risk factors, clinical manifestations, complications and outcome of 16 children. *Br J Dermatol* 2007;156:709–715 (*Abstract*)
10. Wolach B, Raas-Rothschild A, Vogel R, Choc L, Metzker A. Subcutaneous fat necrosis with thrombocytopenia in a newborn infant. *Dermatologica* 1990;181:54–55 (*Abstract*)
11. Kruse K, Irle U, Uhlig R. Elevated 1,25-dihydroxy vitamin D serum concentrations in infants with subcutaneous fat necrosis. *J Pediatr* 1993;122:460–463 (*Abstract*)

SUPPORTED BY  **Vifor Pharma**

CONTACT Swiss Society of Neonatology
www.neonet.ch
webmaster@neonet.ch