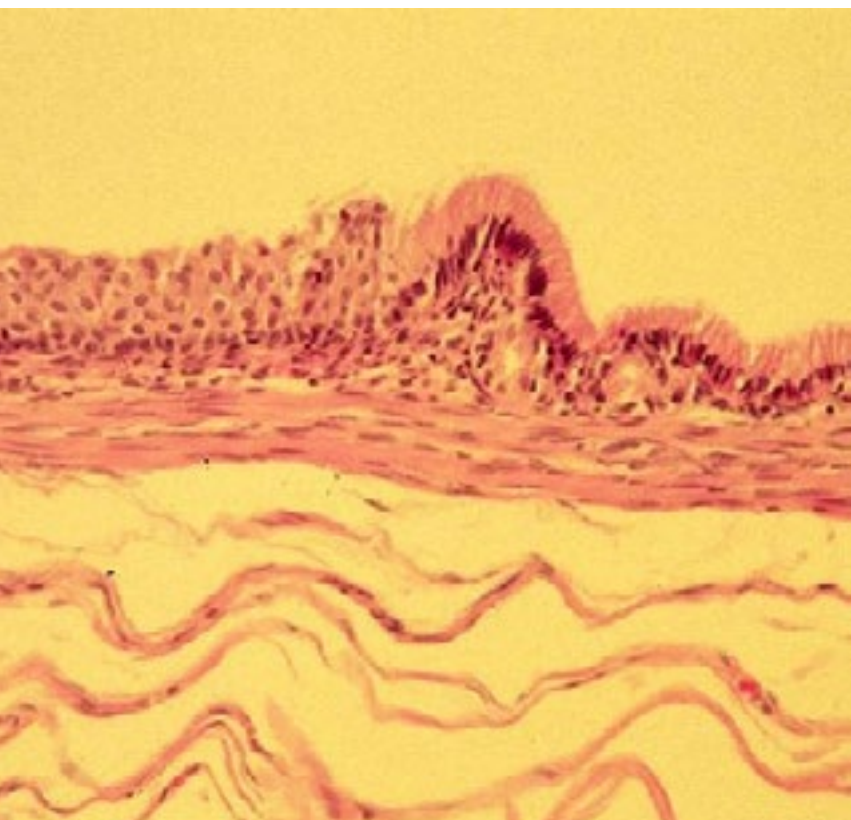


SWISS SOCIETY OF NEONATOLOGY

Mediastinal cyst as a rare
cause of respiratory distress
in a previously healthy
newborn

August 2003



Jourdan-Moser S, Hammer J, Probst C, UKBB (JMS, HJ), and
the Department of Anaesthesia (PC), University Hospital of
Basel, Switzerland

A 4-week-old male infant was referred to our emergency department because of increasing respiratory distress and poor feeding. The past medical and birth history of the patient were unremarkable (vaginal term delivery).

On arrival, the infant was tachypneic with a respiratory rate of 60/min, had a peripheral oxygen saturation of 87% in room air and showed marked chest retractions. Decreased breath sounds on the left were found on auscultation. There was no fever. Capillary blood gas analysis revealed a respiratory acidosis with a pH of 7.26 and a pCO₂ of 8.3 kPa.

The chest X-ray revealed hyperinflation of the left lung causing a marked shift of the mediastinum to the right and right upper lobe atelectasis (Fig. 1). Laboratory investigations showed no signs of an acute bacterial or viral infection. The child was then admitted to the neonatal/pediatric ICU.

High resolution CT of the chest was performed the next morning and showed a cystic mass (44x23x20 mm) with compression of the trachea and left main bronchus at the level of the carina (Fig. 2). Because of impending respiratory failure the child was transferred to the operating room for immediate surgical resection of the cystic mass. Prior to intubation, a rigid bronchoscopy was performed to visualize the airways. This demonstrated complete compression of the left main stem bronchus at the level of the carina.

The cystic mass had no connection to the trachea or the oesophagus (Fig. 3) and was removed without problems (Fig. 4). Histopathologically, the cyst was composed of tissue arising from both respiratory and intestinal tissue consistent with the entity of a cyst arising from the foregut (Fig. 5 and 6). These foregut cysts develop at an early embryonic stage at the time when the ventral diverticulum separates from the primitive foregut.

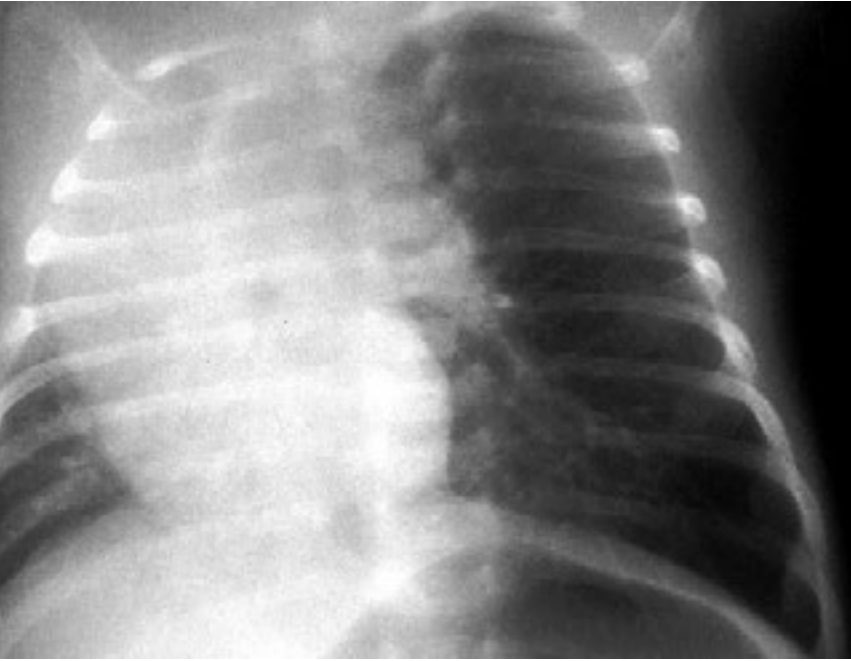


Fig. 1

CXR on admission: Hyperinflation of the left lung with mediastinal shift.

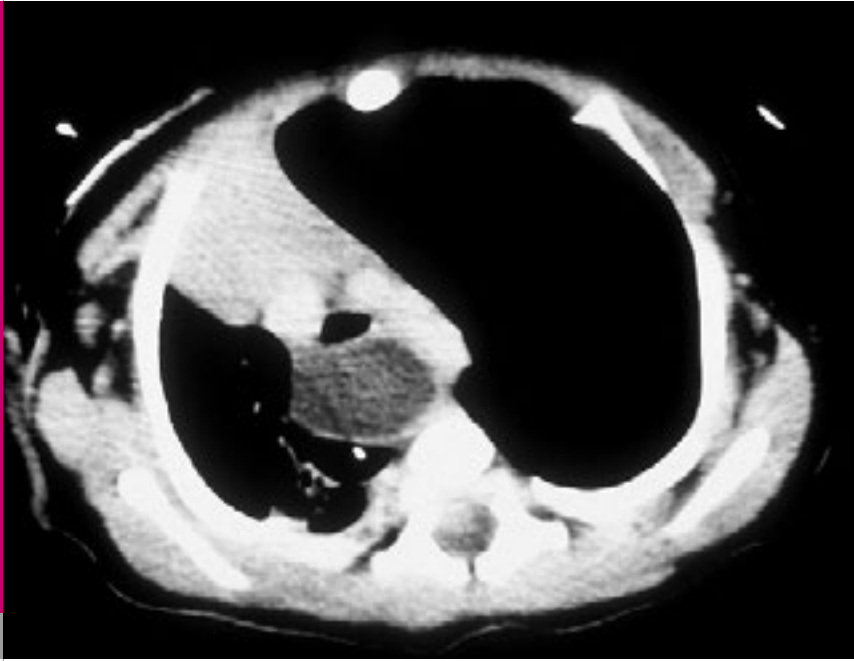


Fig. 2

High resolution CT scan of the chest demonstrating a mediastinal cyst.

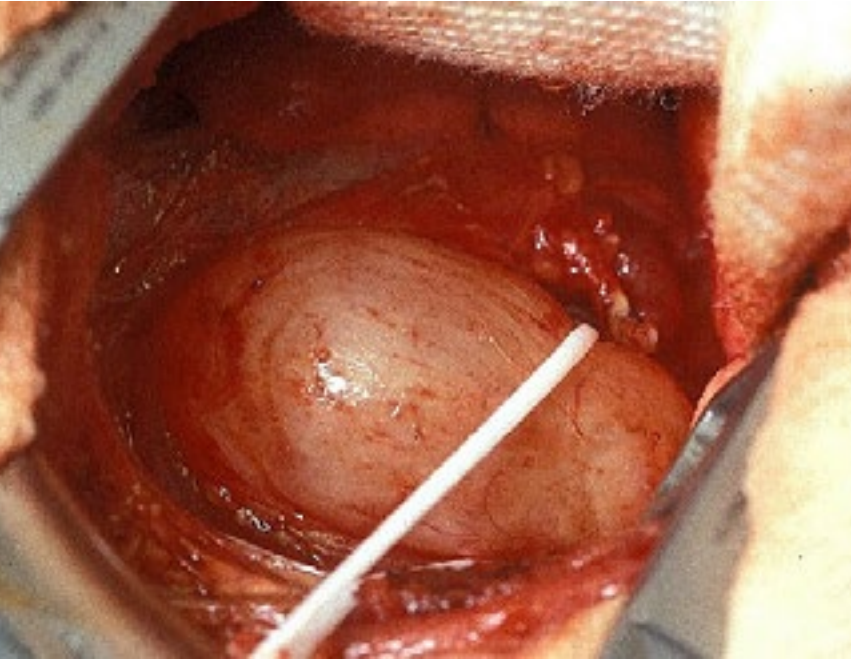


Fig. 3

Intraoperative findings.

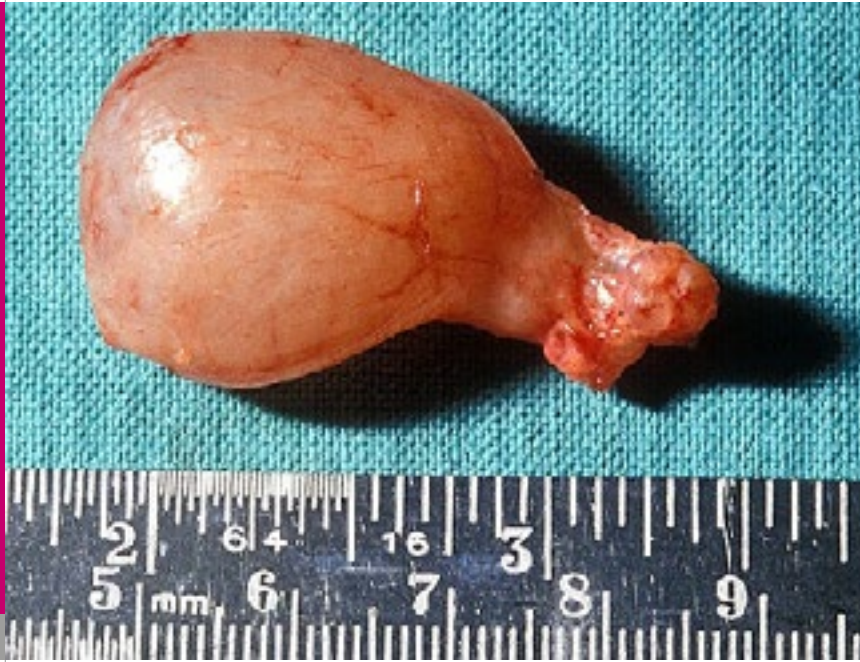

Fig. 4

Cyst after removal.

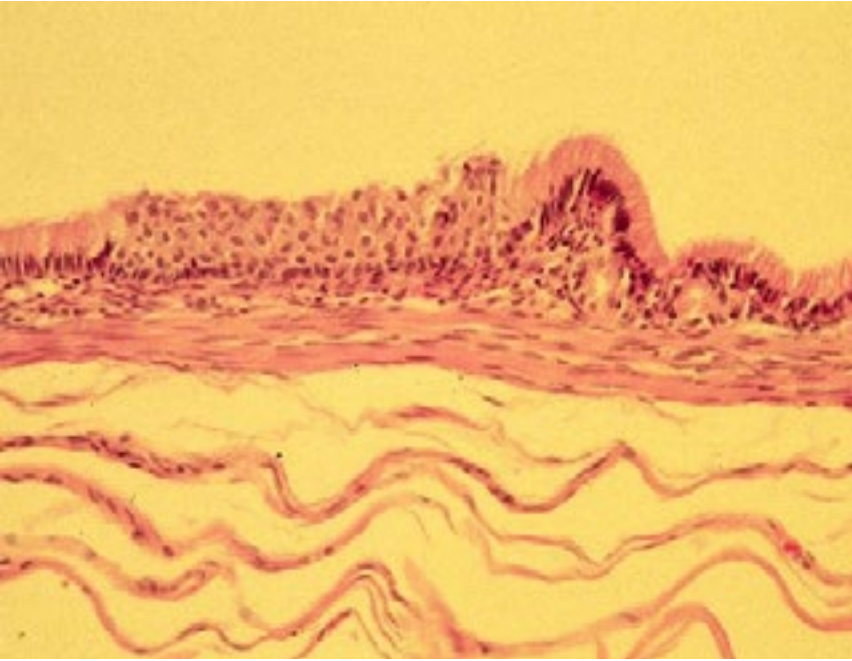


Fig. 5

Histopathology: respiratory epithelium.

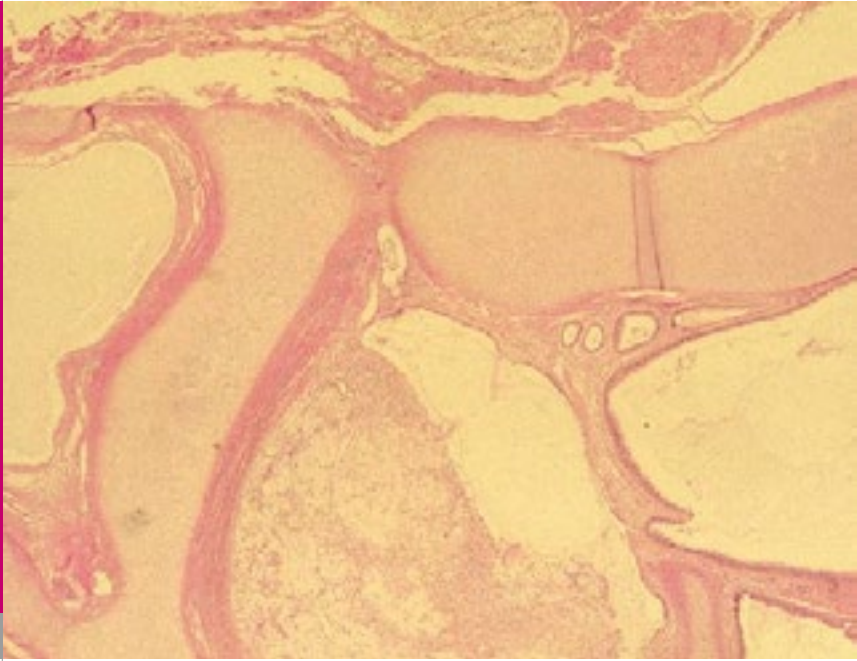


Fig. 6

Histopathology: muroid material.

Congenital mediastinal cysts may cause symptoms at any time in life and - except for lymphangiomas and pericardial cysts – are embryologically foregut duplications. If such malformations cause tracheobronchial obstruction, life-threatening respiratory distress, stridor or asthma-like symptoms can occur in newborns.

Abnormalities of ventral foregut budding during embryonic development (3rd to 6th week of gestation) can present as a variety of malformations. Structures that arise from the foregut are the pharynx, thyroid, parathyroid, thymus, respiratory tract, esophagus, stomach, upper part of the duodenum, liver, and pancreas. Thus, abnormal development at this stage may give rise to bronchogenic cysts, esophageal duplication cysts and gastroenteric cysts.

Bronchogenic cysts are usually located in the mid-mediastinum close to the tracheobronchial tree and classified according to their location as tracheal, hilar, carinal, esophageal or miscellaneous. They contain mucoid material and have usually no communication to the airways or the intestine. They are often asymptomatic, however carinal cysts are most likely to produce respiratory problems. These cysts are potentially fatal in neonates causing severe respiratory distress due to compression of either one or both major bronchi.

Esophageal cysts (duplication) are located in the posterior mediastinum, usually situated on the right side,

and are intimately associated to the wall of the esophagus. They are mostly asymptomatic. Thoracic CT satisfactorily establishes the diagnosis of these malformations. Surgical removal remains the treatment of choice.

1. Chernick and Boat. Kendig's Disorders of the respiratory tract in children. Sixth edition; pages 305-307 and 766-771
2. Lazar RH, Younis RT, Bossila MN.. Bronchogenic Cysts: A cause of stridor in the neonate. Am J Otolaryngol 1991;12:177-121 (*Abstract*)
3. Eichmann D, Engler S, Oldiger HD, Schroeter H, Partsch CJ. Radiological case of the month. Denouement and discussion: congenial esophagela duplication cyst as a rare cause of progressive neonatal stridor. Arch Pediatr Adolesc Med 2001;155:1067-1068
4. Cohen LF. Stridor and upper airway obstruction in children. Pediatrics in Review 2000;21:1-4

SUPPORTED BY



CONTACT

Swiss Society of Neonatology
www.neonet.ch
webmaster@neonet.ch