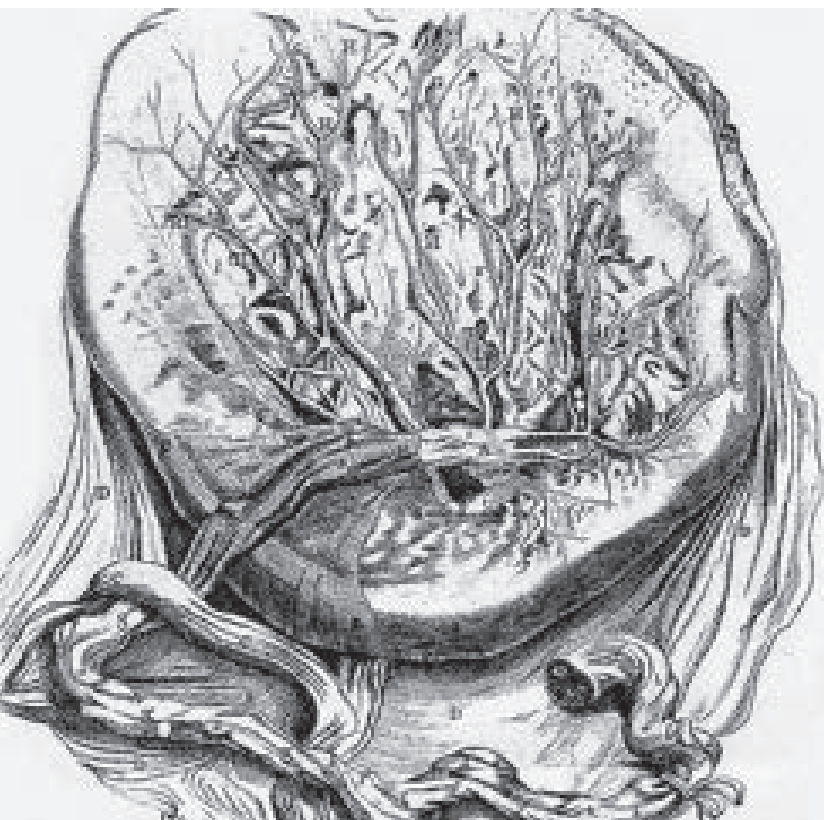


SWISS SOCIETY OF NEONATOLOGY

## Non-immune hydrops fetalis

February 2001





Hydrops fetalis, which is estimated to occur in 1:3000 births/stillbirths and is associated with a high morbidity and a mortality of over 50%, presents a major challenge to obstetricians and neonatologists. Since the decline of rhesus sensitization and hemolytic disease of the newborn, non-immune conditions are responsible for most cases seen today.

A female infant born at 36 6/7 weeks gestation was admitted to our neonatal intensive care unit with hydrops fetalis. The mother was a 21-year-old G1/P1 in good health. Both parents originated from Sudan and their family history was unremarkable.

Pregnancy had been complicated by hyperemesis requiring hospitalisation in the 12th week. Fetal ultrasound examinations in the 12th and 20th weeks had been normal. At 34 weeks, however, when the mother had gained 3.5 kg over the past two weeks, ultrasound showed massive hydrops of fetus and placenta. In addition, the CTG was pathological and an emergency caesarian section was performed.

The amniotic fluid was meconium-stained. Apgar scores were 1, 3, and 3 at 1, 5 and 10 minutes, respectively. Umbilical arterial pH was 7.25. The baby had massive generalized edema and was orally intubated during the first minute of life. Following initial stabilization,

## BACKGROUND

## CASE REPORT

which involved bilateral thoracentesis and removal of 160 ml straw-colored fluid, paracentesis and a single volume exchange transfusion for a hemoglobin of 93 g/l, the child was transferred to the neonatal intensive care unit.

On admission, the birth weight was 3160 g (P 50–90), and the head circumference 34.6 cm (> P 90); there was massive generalized edema, no organomegaly, and contractures of all extremities (Fig. 1). Pleural drains were placed bilaterally, which drained 120-400 ml/day for the first 5 days; losses were replaced with human albumin, immunoglobulins and fresh frozen plasma.

Extended maternal TORCH serologies were negative. Blood type of mother and infant were identical (B positive), and the direct Coombs' test was negative. Blood counts for both parents were normal with normal erythrocyte morphology. On admission, the infant's hemoglobin was 93 g/l the platelet count: 84 G/l, the white cell count: 2.9 G/l with a normal I:T ratio. In addition, her karyotype was 46, XX. She had normal thyroid function tests, a normal Guthrie test and a negative screening result for mucopolysaccharidosis. On echocardiography, there was transient mitral and tricuspid incompetence with resolution over time.

The placenta weighed 631 g and had multiple chorioangiomas involving more than 50% of the placenta with the largest having a diameter of 4 cm.

The drains were removed on the 7th and 10th day and she could be extubated on the 11th day of life (Fig. 2). After initial feeding difficulties she could be discharged home at the age of 1 month, at a corrected gestational age of 41 weeks. Discharge weight was 2320 g (840 g below birth weight).

The baby was regularly seen at the neurodevelopmental follow-up clinic. Transient increased tone in the extremities was noted at 9 months. At the age of 16 months, she had mild generalized decrease in muscle tone and slight delay in motor and personal/social development.

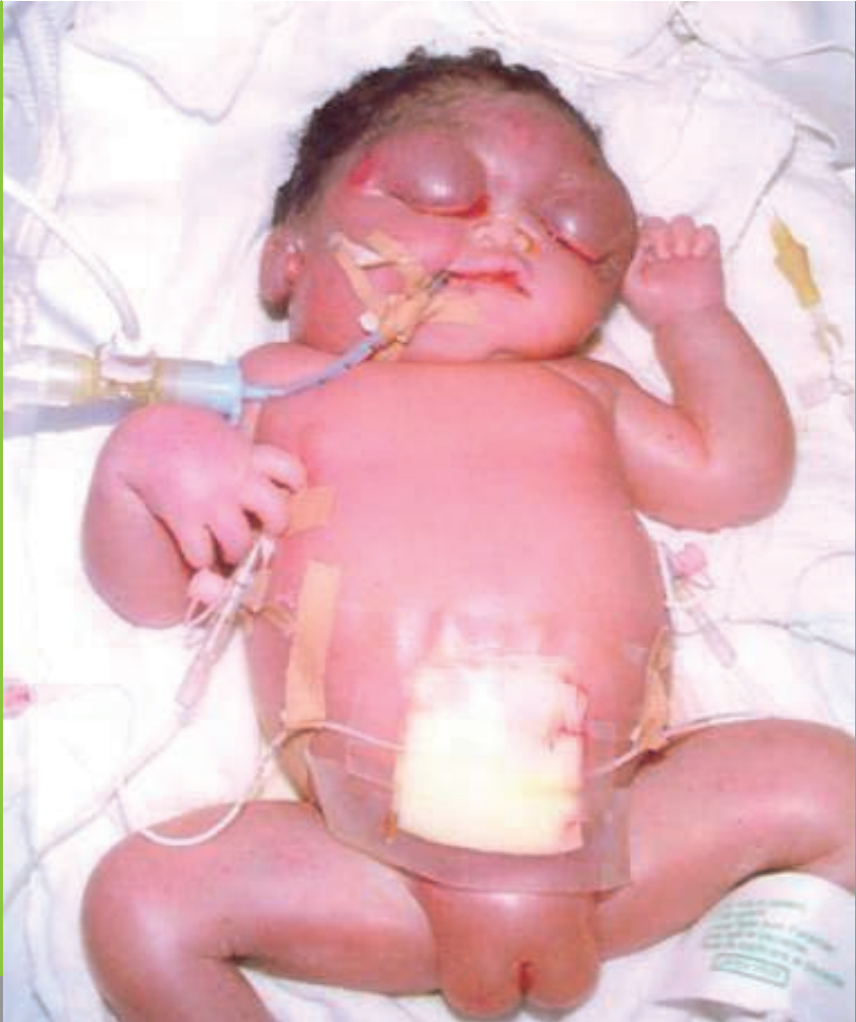

Fig. 1

*Appearance of the infant on admission to the NICU.*

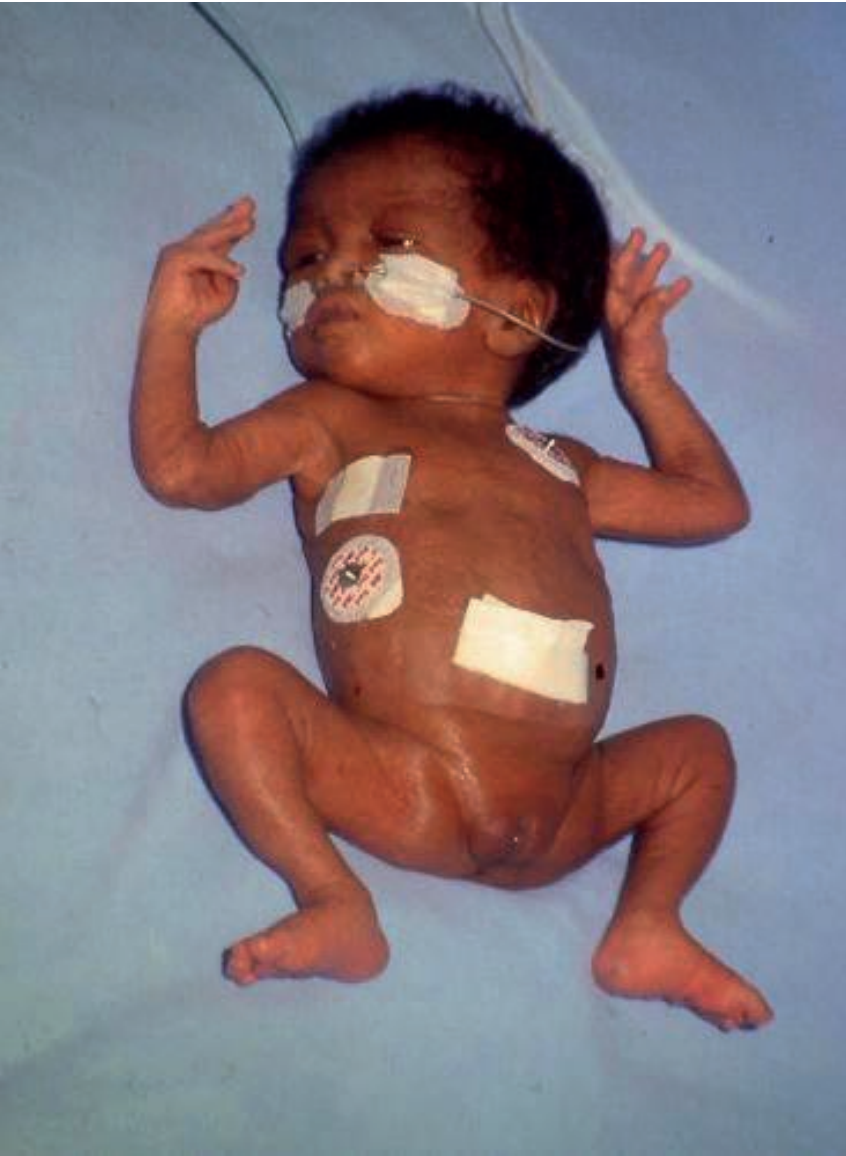

Fig. 2

*Appearance of the infant on DOL 11.*

## DISCUSSION

In 22–24% of hydrops cases, the etiology cannot be determined. Cardiac, chromosomal abnormalities, thoracic lesions, twin-to-twin transfusion syndrome and anemia (for example a thalassemia) account for the majority of cases of non-immune hydrops. In the case presented here, these causes could be excluded.

Chorioangiomas, which are relatively common benign tumors of the placenta, have been associated with hydrops, polyhydramnios, growth retardation and fetal anemia. The pathophysiologic mechanism may be related to arteriovenous shunts or vascular shunts within the chorioangioma, leading to circulatory overload and fetal congestive cardiac failure. In the absence of other causes it is likely that the chorioangiomas, which involved more than 50% of the placenta surface, were the cause for the hydrops in this case.



1. Machin Geoffrey A: Hydrops revisited: literature review of 1414 cases published in the 1980s. *Am J Med Genet* 1989;34:366–390 (*Abstract*)
2. Hadi Hamid A, Finley James, Strickland Diana: Placental Chorioangioma: prenatal diagnosis and clinical significance. *Am J Perinatol* 1993;10:146–149 (*Abstract*)
3. Haak MC, Oosterhof H, Mouw RJ, Oepkes D, Vandenbussche FP: Pathophysiology and treatment of fetal anemia due to placental chorioangioma. *Ultrasound Obstet Gynecol* 1999;14:68-70 (*Abstract*)
4. Chazotte C, Girz B, Koenigsberg M, Cohen WR: Spontaneous infarction of placental chorioangioma and associated regression of hydrops fetalis. *Am J Obstet Gynecol* 1990;163:1180-1 (*Abstract*)
5. Hülkamp G, Debus O, Marquardt T, Koch HG, Hörnig-Franz I, Rellensmann G, Rabe H, Harms E: Nicht immunologischer Hydrops fetalis: Diagnostik und Prognose bei 38 Patienten 1994/99. Jahrestagung GNPI Berlin 7.-10.Mai 2000. *Z Geburtsh Neonatol* 2000;204:26
6. Polin and Fox: *Fetal and Neonatal Physiology*. 2nd Edition. WB Saunders Company, 1998. pp 1730– 1736.

SUPPORTED BY



CONTACT

Swiss Society of Neonatology

[www.neonet.ch](http://www.neonet.ch)

[webmaster@neonet.ch](mailto:webmaster@neonet.ch)