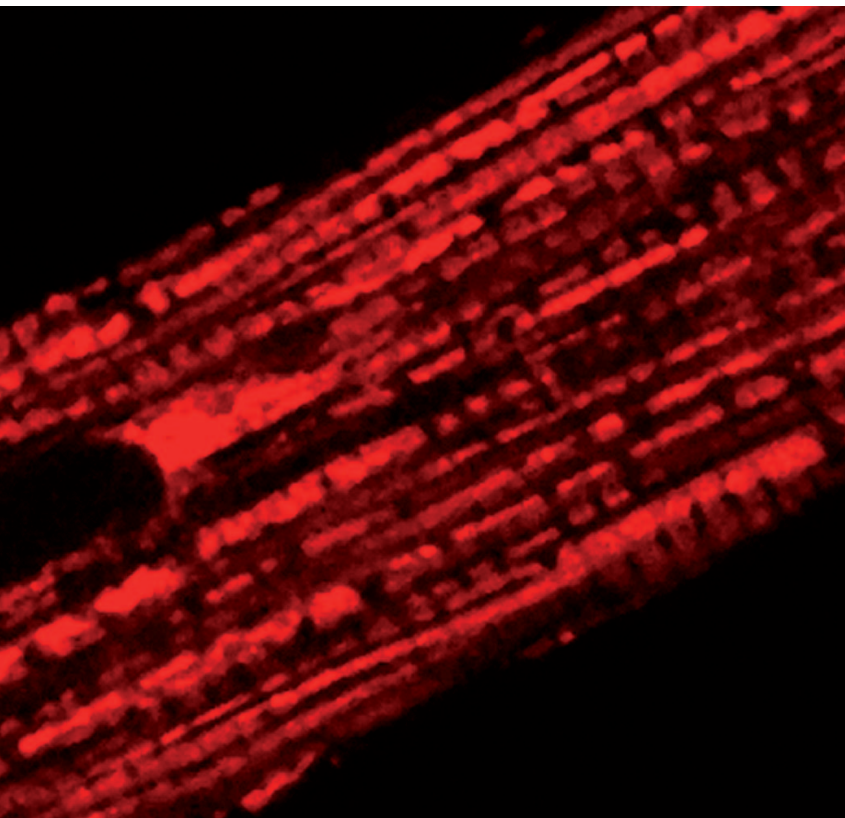


SWISS SOCIETY OF NEONATOLOGY

Severe neonatal manifestation  
of centronuclear myopathy:  
X-linked myotubular  
myopathy

MARCH 2011





The term „floppy infant“ is used to describe an infant who presents with generalized hypotonia at birth or in early infancy. The differential diagnosis is broad and the use of a diagnostic algorithm is therefore extremely helpful. Such an algorithm has previously been described in the June 2007 COTM (1-3). The case presented here illustrates the importance of a thorough family history.

This male infant was born to a 31-year-old Turkish G2/P1 by spontaneous vaginal delivery at 34 2/7 weeks of gestation following premature rupture of membranes. Pregnancy had been uneventful until the 32 week when polyhydramnios was noted. No other abnormalities were detected, and the mother reported that she had felt normal fetal movements.

Immediately after delivery, the infant was very floppy with no respiratory effort. Umbilical cord pH values were 7.16 (arterial) and 7.20 (venous). Apgar scores were 2, 4, 4 at 1, 5 and 10 minutes, respectively. Bag mask ventilation was initiated and, after 3 minutes, there were some spontaneous respiratory movements. However, when the boy failed to stabilize on nasal CPAP, he was intubated at 25 minutes of age and transferred to the NICU.

After admission to the NICU, a CXR revealed a right-sided pneumothorax (Fig. 1) and a chest tube was

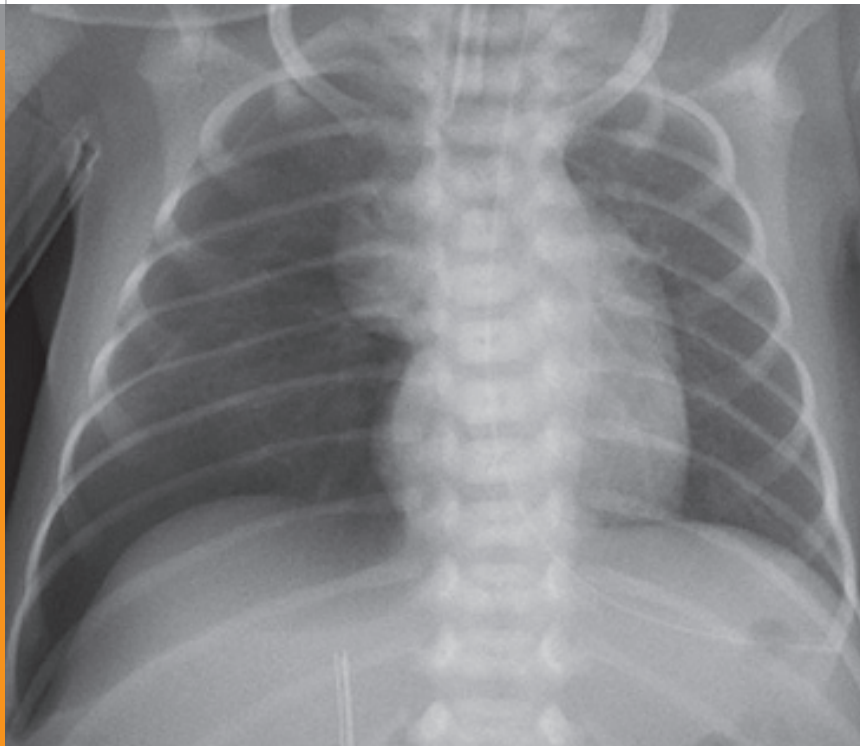
## INTRODUCTION

## CASE REPORT

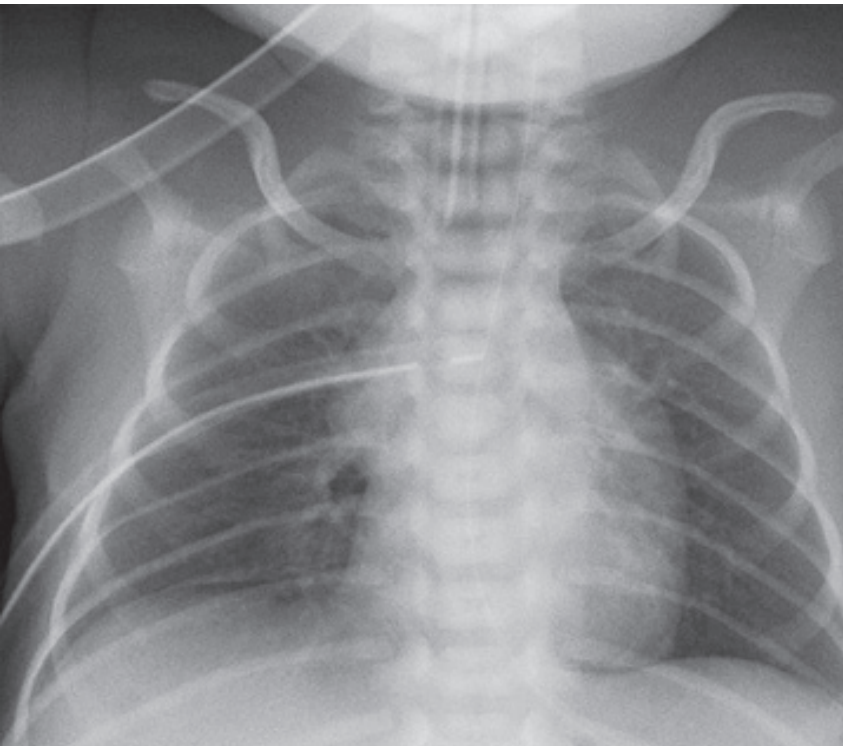
placed (Fig. 2). In addition, the ribs appeared to be very thin, particularly in the posterior region (Fig. 1, 2). A few hours later, while the infant was on low ventilator settings (peak inspiratory pressure of 15 mbar, PEEP of 5 mbar), a second pneumothorax occurred on the left side (Fig. 3). The lung rapidly re-expanded following thoracocentesis (Fig. 4).

*CXR on DOL 1: right-sided pneumothorax and very thin ribs.*

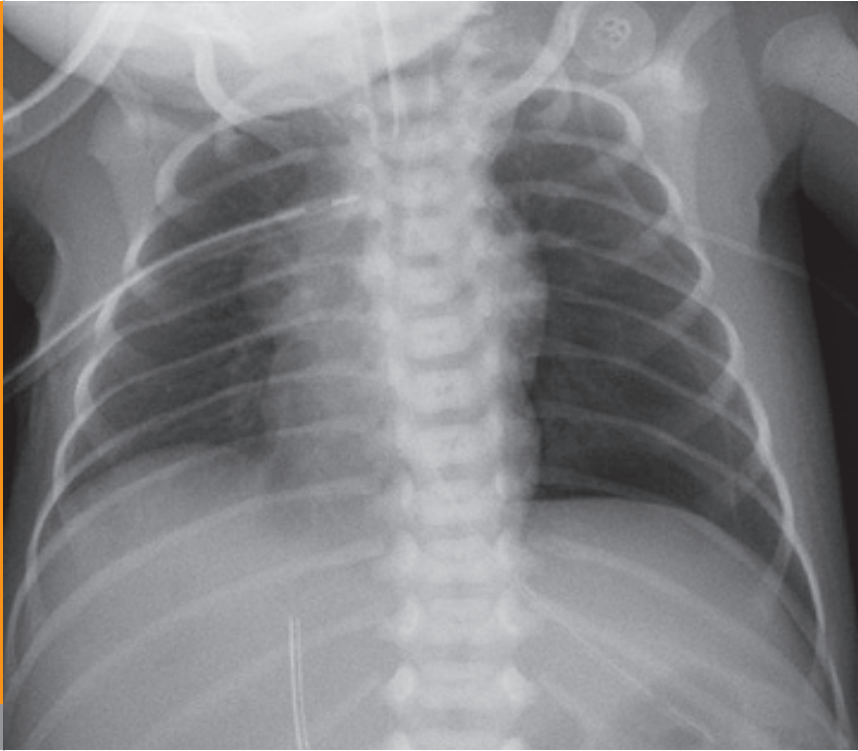
**Fig. 1**



*CXR on DOL 1: resolution of pneumothorax after chest tube insertion.*



**Fig. 2**



**Fig. 3**

*CXR on DOL 1: left-sided pneumothorax.*

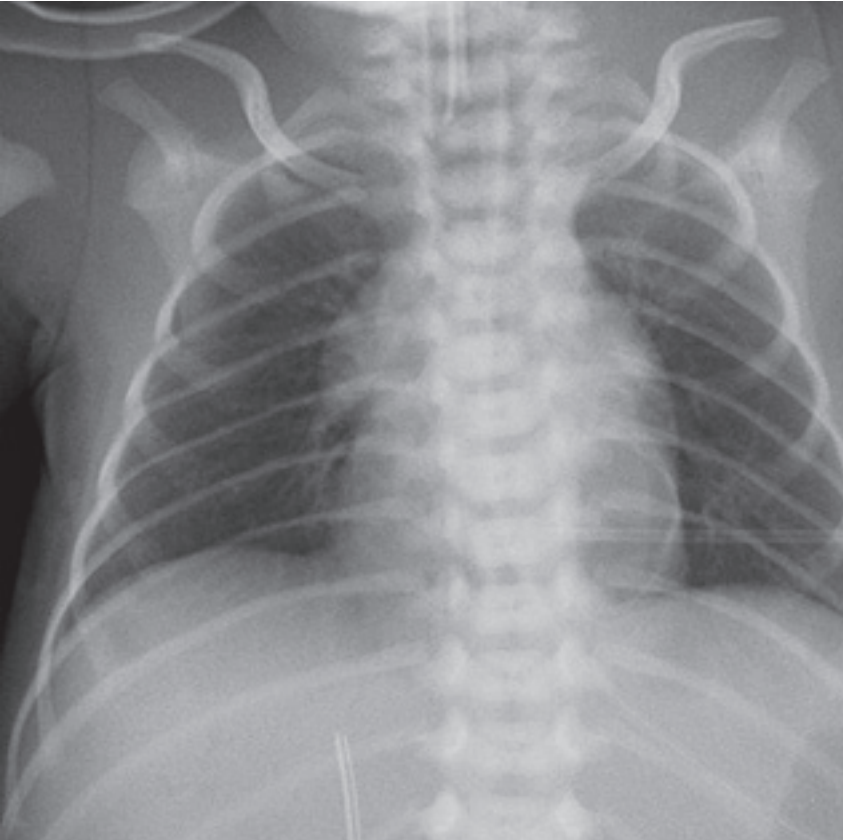


Fig. 4

*CXR on DOL 1: left-sided pneumothorax evacuated following thoracocentesis.*

Over the next days, the infant continued to be extremely floppy with minimal respiratory effort. Cerebral ultrasound examination, EEG and echocardiography were all normal. More detailed history taking revealed a remarkable family history. Almost fifteen years earlier, a son of the mother's sister had died from complications of „weak muscles“ at the age of one month. The parents of our patient were able to obtain a copy of this child's medical record which showed that based on a muscle biopsy a diagnosis of centronuclear myopathy had been made. In addition, there were several early deaths of male infants in the family's pedigree (Fig. 5).

At the age of 5 days, a muscle biopsy was performed. The findings were consistent with a centronuclear myopathy (Fig. 6, 7), and, based on the family history, a likely diagnosis of X-linked myotubular myopathy (XLMTM) was made. At that time, DNA mutation screening of the MTM1 gene, however, failed to reveal a disease causing mutation and analysis of RNA isolated from cultured fibroblasts was also without abnormality.

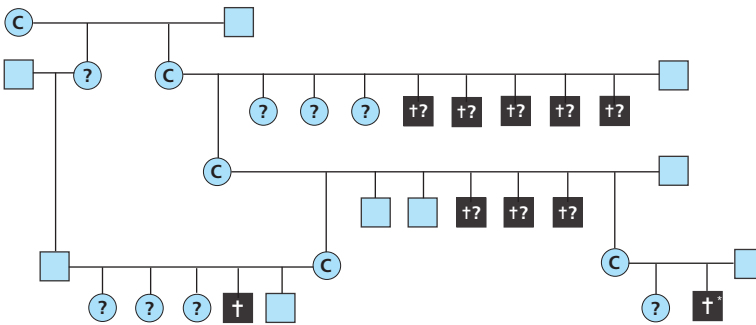
On day of life nine, the patient developed progressive chylothoraces (Fig. 8). Because the patient's prognosis was felt to be dismal, no chest tubes were inserted and, on day of life 16, he was extubated and died in the arms of his parents. At the request of the parents, no autopsy was performed.



More than a year after the death of our patient, repeat genetic testing did reveal a mutation on the MTM1 gene in the two patients of this family with biopsy-proven centronuclear myopathy, thus ultimately confirming the suspected diagnosis of XLMTM.

*Family pedigree: apart from two confirmed cases of XLMTM, at least eight other male infants that have died in the neonatal period (details not available).*

Fig. 5



Legend

- healthy males
- † male deaths from XLMTM myopathy (asterisk: our patient)
- †? early male deaths (no details available)
- C likely female carriers
- ? female with unclear carrier status

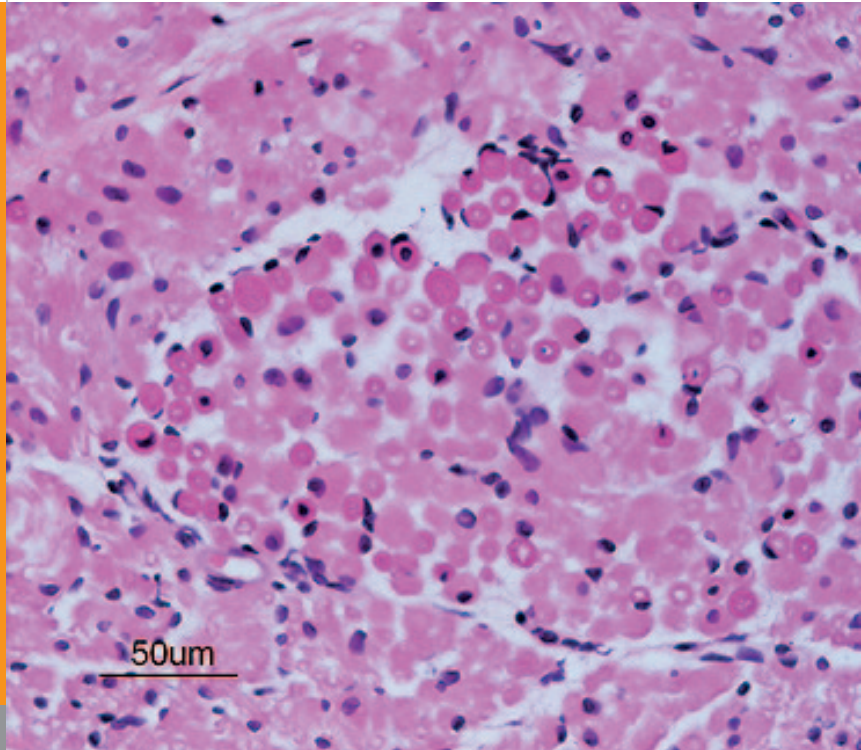
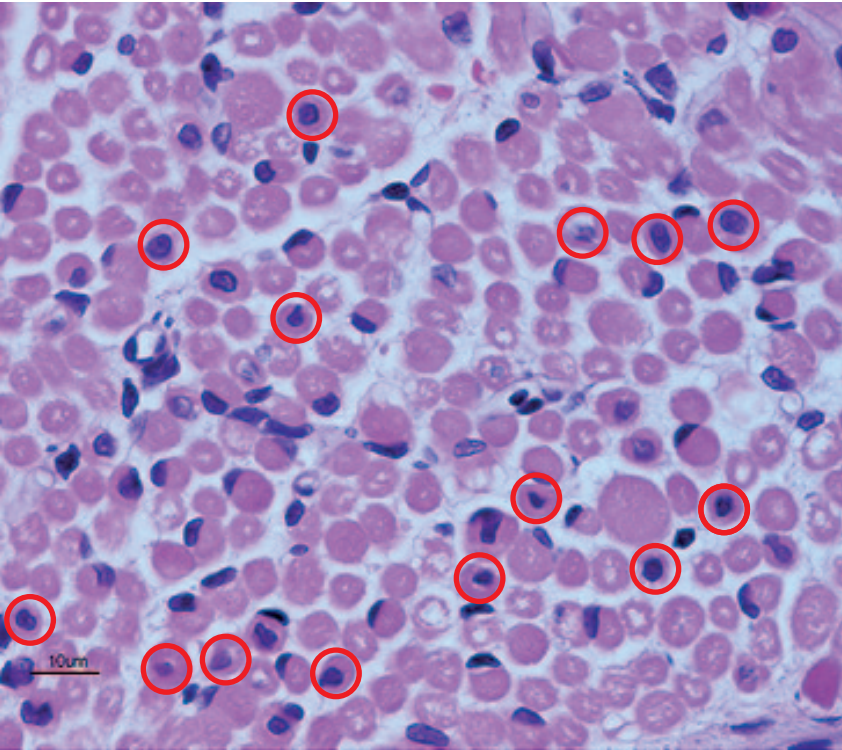
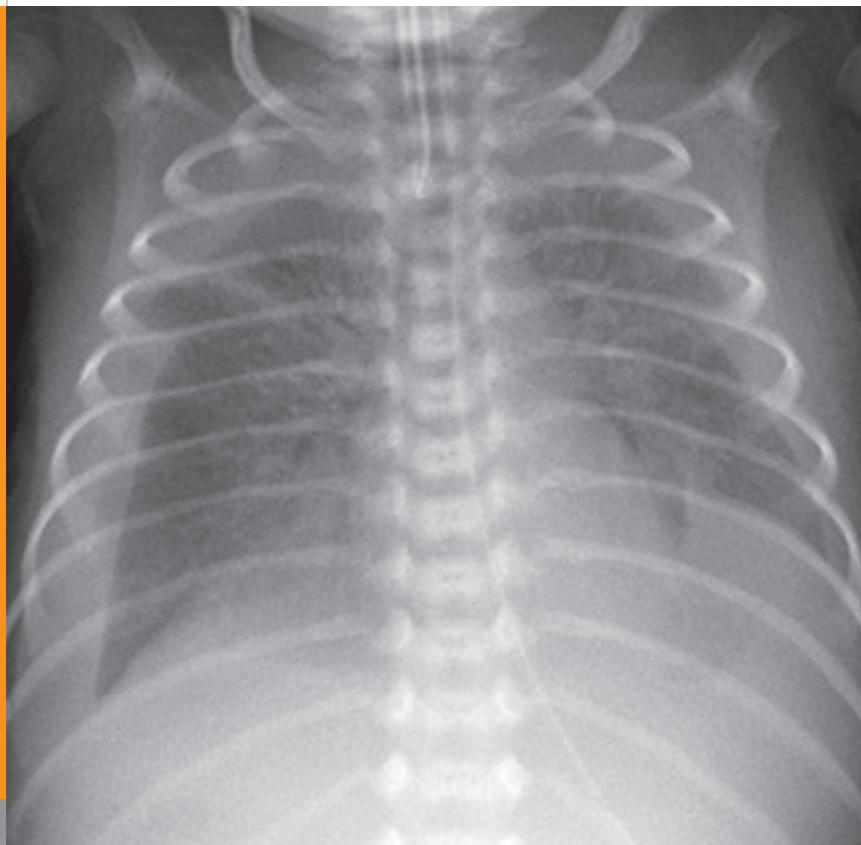


Fig. 6

*Muscle biopsy (quadriceps muscle): atrophic muscle fibres and numerous centrally located nuclei.*

**Fig. 7**

*Muscle biopsy (quadriceps muscle): atrophic muscle fibres and numerous centrally located nuclei (examples highlighted by red circles).*



**Fig. 8**

*CXR on DOL 9: bilateral pleural effusions (right > left), identified as chylothoraces.*

The term centronuclear myopathy (CNM) is used to describe an inherited neuromuscular disorder characterized by clinical features of a congenital myopathy and centrally placed nuclei on muscle biopsy. This abnormality was first described by Spiro et al. in 1966 in an adolescent boy (4). Because the appearance reminded the authors of the centrally located nuclei during the myotubular stage of embryonic development, the term myotubular myopathy (MTM) was coined. When in 1990 a genetic abnormality on the X chromosome was found to be involved in a substantial proportion of patients with the above described histology, the affected gene segment was named MTM1. This gene encodes for a phosphatase called myotubularin that is highly preserved throughout evolution. The incidence of XLMTM is estimated at 1:50'000 male births.

Mutations in the MTM1 gene are usually associated with very severe forms of CNM but milder phenotypes have been described (5, 6). Although most patients are male, there have been reports of severely affected female carriers with skewed X-inactivation (7). Apart from the XLMTM, there are CNM which are inherited as autosomal recessive (amphiphysin 2 (BIN1) gene affected) and autosomal dominant (dynamamin 2 (DNM2) gene affected) disorders.

Our patient's presentation (polyhydramnios, extreme hypotonia and neonatal onset of respiratory failure,

thinning of the ribs) and muscle biopsy findings, coupled with a highly remarkable family history of early deaths in male neonates and infants (Fig. 5) was strongly suggestive of XLMTM. Initial genetic analyses were negative, and a disease causing mutation was only identified upon repeat testing. If no mutation is found in a male proband, the diagnosis of XLMTM cannot be completely excluded. The failure to detect mutations in males in whom the diagnosis of XLMTM was suspected, is approximately 10%-40% (8). This could reflect the presence of mutations in MTM1 regulatory sequences that may have been missed by the mutation detection protocols or either an autosomal dominant or an autosomal recessive myotubular myopathy.

See also: **COTM 07/2007**: Floppy neonate and **COTM 02/2005**: Congenital hypomyelination neuropathy.

1. Paro-Panjan D, Neubauer D. Congenital hypotonia: is there an algorithm? *J Child Neurol* 2004;19:439-442
2. Prasad AN, Prasad C. The floppy infant: contribution of genetic and metabolic disorders. *Brain Dev* 2003;25:457-476
3. Johnston HM. The floppy weak infant revisited. *Brain Dev* 2003;25:155-158
4. Spiro A, Shy G, Gonatas N. Myotubular myopathy. Persistence of fetal muscle in an adolescent boy. *Arch Neurol* 1966;14:1-14
5. Chanzy S, Routon MC, Moretti S, de Gennes C, Mselati JC. Unusual good prognosis for X-linked myotubular myopathy. *Arch Pediatr* 2003;10:707-709
6. Yu S, Manson J, White S, Bourne A, Waddy H, Davis M, Haan E. X-linked myotubular myopathy in a family with three adult survivors. *Clin Genet* 2003;64:148-152
7. Kristiansen M, Knudsen GP, Tanner SM, et al. X-inactivation patterns in carriers of X-linked myotubular myopathy. *Neuromuscul Disord* 2003;13:468-471
8. GeneReviews: <http://www.ncbi.nlm.nih.gov/books/NBK1432/>

SUPPORTED BY



CONTACT

Swiss Society of Neonatology

[www.neonet.ch](http://www.neonet.ch)

[webmaster@neonet.ch](mailto:webmaster@neonet.ch)