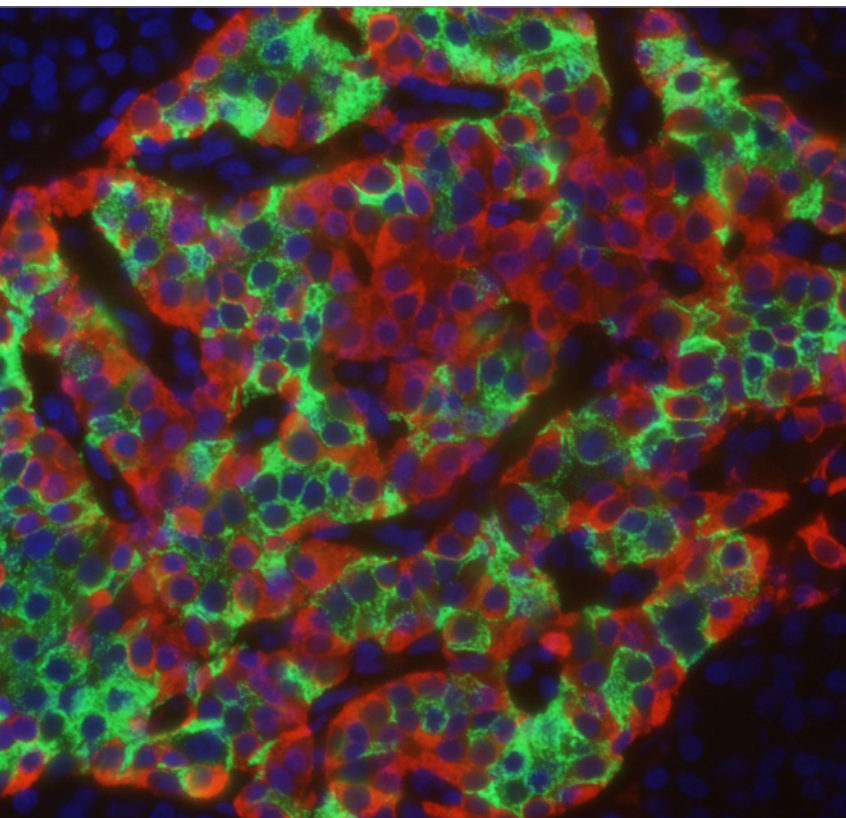


Early neonatal death caused
by severe euglycemic
ketoacidosis in a pregnant
woman with type 1 diabetes
mellitus

July 2017



Diabetic ketoacidosis (DKA) is one of the most serious acute complications of diabetes mellitus and is characterized by uncontrolled hyperglycemia, metabolic acidosis and ketosis. The reported incidence of diabetes mellitus in pregnancy ranges from 6 to 7% with 90% occurring among women affected by gestational diabetes mellitus (GDM) (1). The overall incidence of DKA occurrence during pregnancy is difficult to ascertain but some articles have reported an incidence between 1 and 3% (2, 3). Although it is a rare condition, DKA in pregnancy is an urgent complication which can compromise both fetus and mother.

DKA is the result of an absolute or relative deficiency of insulin which causes a state of starvation of cells accompanied by an increased secretion of the counter-regulatory hormones (cortisol, glucagon, epinephrine). The metabolic characteristics of DKA can trigger a chain of events that will self-perpetuate in a vicious cycle. Hyperglycemia gives rise to an osmotic gradient resulting in an excessive diuresis, which leads to severe dehydration and hypervolemia. This further aggravates the hyperglycemia and acidosis due to the activation of other stress hormones (growth hormone and cortisol), and osmotic diuresis causes low sodium levels (4).

Pregnant women with GDM are at greater risk for DKA than non-pregnant diabetic women (5). Factors that predispose the pregnant patient to DKA include accelerated starvation (especially in the second and

third trimesters), dehydration, decreased caloric intake (e.g., nausea or hyperemesis gravidarum), decreased buffering capacity (compensated respiratory alkalosis of pregnancy), stress, and increased production of insulin antagonists (human placental lactogen, prolactin, and cortisol) (6).

Euglycemic ketoacidosis is defined as severe ketoacidosis in the absence of pronounced hyperglycemia. Euglycemic ketoacidosis has been reported in women with both pre-gestational diabetes mellitus (type 1 and type 2), and GDM. Guo et al. (7) demonstrated that DKA in pregnancy tends to occur at lower blood glucose levels than DKA in nonpregnant diabetic women and sometimes as euglycemic ketoacidosis. They hypothesized that low blood glucose levels are associated with an increase in glucose uptake by the fetoplacental unit as well as a decrease in glycogenolysis and hepatic glucose production. In addition, pregnancy predisposes the mother to accelerated starvation characterized by the switch from use of hepatic glycogen to lipolysis during fasting and associated with development of hypoglycemia, raised plasma levels of free fatty acids and increased plasma and urinary ketones (8).

A 27-year-old G2/P1 was admitted to our delivery room at 32 3/7 weeks with preterm labor. Type-1 diabetes mellitus had been diagnosed three years ago. Blood glucose levels were subsequently well controlled with insulin therapy. She had a history of vomiting for two days, as did her husband and other family members. Tocolysis with hexoprenaline had already been initiated at the referring hospital. On admission, she was unwell with nausea, vomiting, frontal headache and painful contractions. She was tachycardic but normotensive.

Urine dipstick revealed proteinuria and ketonuria. Blood glucose concentration was 7.5 mmol/l. There were no signs of preeclampsia other than headache. Transabdominal ultrasound revealed a normal amount of amniotic fluid, female sex, an estimated birth weight of 2600 g and cardiomegaly. Atosiban was added to hexoprenaline due to increasing contractions, and a first dose of dexamethasone was administered for fetal lung maturation.

When the patient developed neurological symptoms, she received a magnesium sulfate infusion, although no additional signs of preeclampsia had developed in the meantime. Antibiotic therapy was initiated to treat group B streptococcus detected in a vaginal swab. Hexoprenaline was stopped when the patient became increasingly tachycardic. Fetal heart rate (monitored via CTG) decreased and was temporarily not detec-

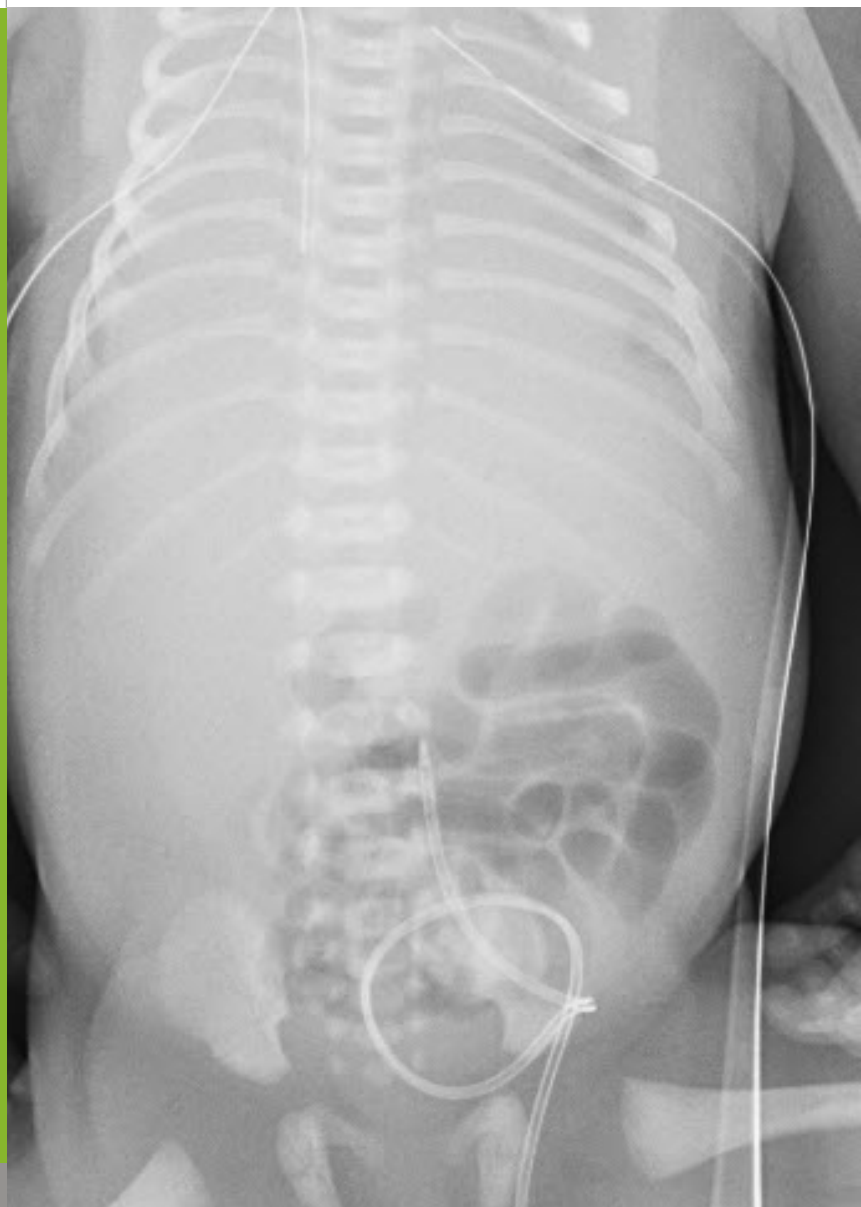

Fig. 1

Postmortem chest X-ray: bilateral chest drains and low lying umbilical venous catheter, no evidence of any air leaks.

table, so that ultrasound was used repeatedly. Finally, urgent Cesarean section was performed six hours after admission because of persistent fetal bradycardia.

Apgar scores were 0, 0 and 0 at 1, 5 and 10 minutes, respectively. Cardiopulmonary resuscitation was initiated immediately after birth and was performed per protocol, including immediate oral intubation and repeated administration of intravenous adrenaline. Fluid boli with normal saline 0.9% were given twice (25 ml each) and 60 ml of packed red cells were transfused. No signs of air leaks were detected clinically or by transillumination; nevertheless, bilateral chest drains were placed (Fig. 1). Repeated echocardiography showed absent myocardial contractions, and, at 50 minutes of life, it was decided to discontinue resuscitation.

During resuscitation, the following possible causes for cardiac arrest were excluded: hypovolemia, hypothermia, cardiac tamponade, tension pneumothorax, insufficient ventilation. Repeated blood gas analyses (drawn from the umbilical vein at birth and at 15 minutes of life) revealed severe hyperglycemic metabolic acidosis and raised potassium concentrations (Table 1). Just before resuscitation efforts were stopped, we were informed that the mother's blood gas analysis also revealed severe hyperglycemia (blood glucose concentration 28 mmol/l) and metabolic acidosis (pH 6.90) with a potassium level of 6.9 mmol/l (Table 1).

Table 1. Laboratory results

Blood gas analyses	pH	pCO ₂ (kPA)	BE (mmol/l)	Potassium (mmol/l)	Glucose (mmol/l)
Mother	6.95	3.3	-26	6.3	28
Infant – I	6.78	7.6	-30	7.1	21.8
Infant – II	< 6.30	18.2	?	10.4	23.4

I: at birth, II: at 15 minutes of life

Suspected cause of death was severe prolonged metabolic acidosis, aggravated by fetal bradycardia. We cannot exclude additional factors, such as cardiomyopathy or congenital heart disease due to diabetic fetopathy (birth weight 2710 g, > 97th percentile). The parents did not consent to autopsy.

Retrospectively, it was found that the patient had not injected her insulin for 58 hours due to her suspected gastroenteritis. On admission to our hospital, no blood gas analysis was performed until after birth and no insulin was given, as the patient and her husband, who also suffers from type 1 diabetes, claimed to be knowledgeable and competent to adjust their insulin requirements.

In summary, this case report illustrates the significant impact of type 1 diabetes on fetal/neonatal outcome.

For the prevention of cases like this, management for women with diabetes should be improved during pregnancy and on admission to the delivery room. Pregnant women and health care professionals involved in their care should be able to recognize signs and symptoms of diabetic ketoacidosis; in addition, appropriate laboratory investigations (including blood glucose and electrolyte concentrations as well as a blood gas analysis) should be performed in every woman with type-1 diabetes or insulin-dependent GDM on admission to the delivery room, especially when they present with preterm contractions and/or signs of diabetic ketoacidosis (vomiting, headache, etc.).

It is important to keep in mind that there can be euglycemia, especially in cases of starvation ketoacidosis due to nausea and/or vomiting and decreasing caloric intake without adequate insulin intake. Both are frequent situations in obstetric patients.

DKA should be ruled out as a differential diagnosis of preeclampsia, in particular prior to using steroids for fetal lung maturation or for chronic medical disorders because of the effects of steroids on serum glucose. Steroids can themselves lead to DKA (9). Of note, the effects of steroids will be more pronounced when used in association with beta sympathomimetic agents to treat uterine contractions or preterm labor.

REFERENCES

1. Dalfrà MG, Burlina S, Sartore G, Lapolla A. Ketoacidosis in diabetic pregnancy. *J Matern Fetal Neonatal Med* 2016;29:2889–2895 (*Abstract*)
2. Parker JA, Conway DL. Diabetes ketoacidosis in pregnancy. *Obstet Gynecol Clin North Am* 2007;34:533–543 (*Abstract*)
3. Ramin KD. Diabetic ketoacidosis in pregnancy. *Obstet Gynecol Clin North Am* 1999;26:481–488 (*Abstract*)
4. Foster DW, McGarry JD. The metabolic derangements and treatment of diabetic ketoacidosis. *N Eng J Med* 1983; 309:159–169 (no abstract available)
5. Hollingsworth DR. Medical and obstetric complications of diabetic pregnancies: IDDM, NIDDM, and GDM. Bron DL, Mitchell C (Eds.), *Pregnancy, Diabetes and Birth: A Management Guide* (2nd edition), Williams & Wilkins, Baltimore (1992) (no abstract available)
6. Chauhan SP, Perry KG. Management of diabetic ketoacidosis in the obstetric patient. *Obstet Gynecol Clin North Am* 1995;22:143–155 (*Abstract*)
7. Guo RX, Yang LZ, Li LX, Zhao XP. Diabetic ketoacidosis in pregnancy tends to occur at lower blood glucose levels: case-control study and a case report of euglycemic diabetic ketoacidosis in pregnancy. *J Obstet Gynaecol Res* 2008;34:324–330 (*Abstract*)
8. Frise CJ, Mackillop L, Joash K, Williamson C. Starvation ketoacidosis in pregnancy, *Eur J Obstet Gynecol Reprod Biol* 2013;167:1–7 (*Abstract*)
9. Bedalow A, Balasubramnyam A. Glucocorticoid-induced ketoacidosis in gestational diabetes: sequelae of the acute treatment of preterm labor. *Diabetes Care* 1997;20:922–924 (*Abstract*)

SUPPORTED BY



CONTACT

Swiss Society of Neonatology

www.neonet.ch

webmaster@neonet.ch