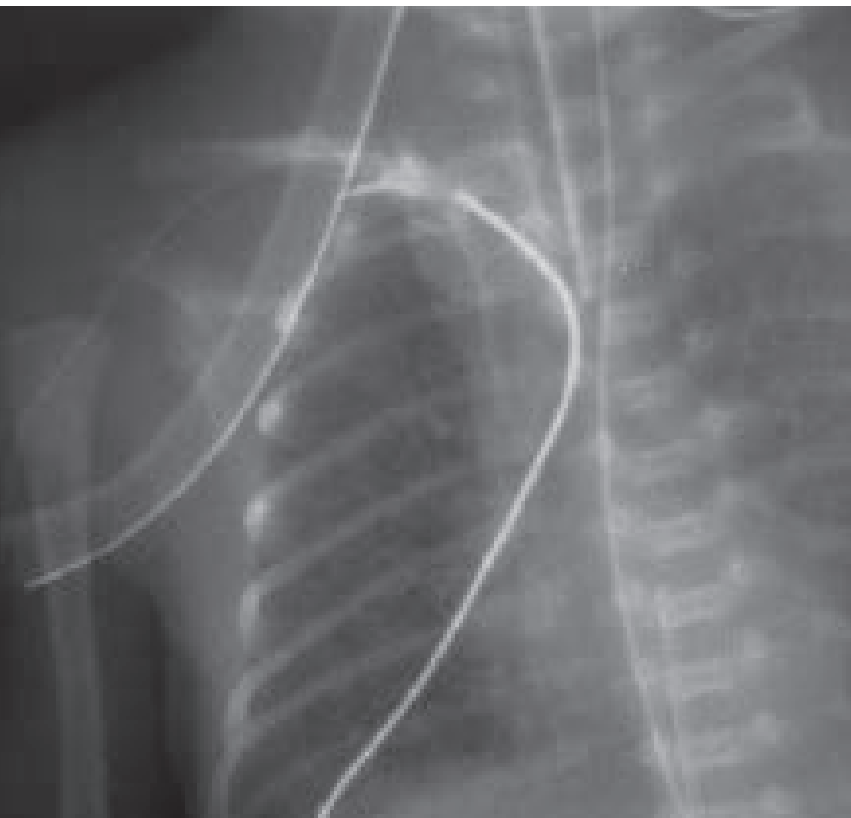

SWISS SOCIETY OF NEONATOLOGY

Potentially fatal complications
of peripherally inserted central
venous catheters (PICCs)

October 2001



Berger TM, Neonatal and Pediatric Intensive Care Unit,
Children's Hospital of Lucerne, Switzerland

Peripherally inserted central venous catheters (PICCs) are commonly used in neonatal intensive care units to administer vasoactive agents and parenteral nutrition solutions. Newer catheters are fitted with a guidewire and can be inserted even in the tiniest babies at the bedside. It is now rare for a preterm baby to be brought to the operating room for surgical placement of a central venous catheter. Catheter occlusion, thrombophlebitis and catheter-associated infections are the most common complications associated with the use of PICCs. The following cases illustrate two less common but potentially lethal complications.

CASE REPORT

Case 1

This 5-day-old former 28-week preterm male infant (birth weight 720 g) showed a gradually increasing oxygen requirement after having been weaned to room air more than 24 hours ago. A chest X-ray revealed diffuse opacification of the right hemithorax with evidence of a pleural effusion (Fig. 1). A pleurocentesis was performed and 10 ml of a milky fluid was aspirated (Fig. 2). The infant was still receiving partial parenteral nutrition through a silastic catheter inserted through an antecubital vein. Biochemical analysis of the aspirate (high glucose and lipid content) was consistent with the diagnosis of an infusothorax (Fig. 3).

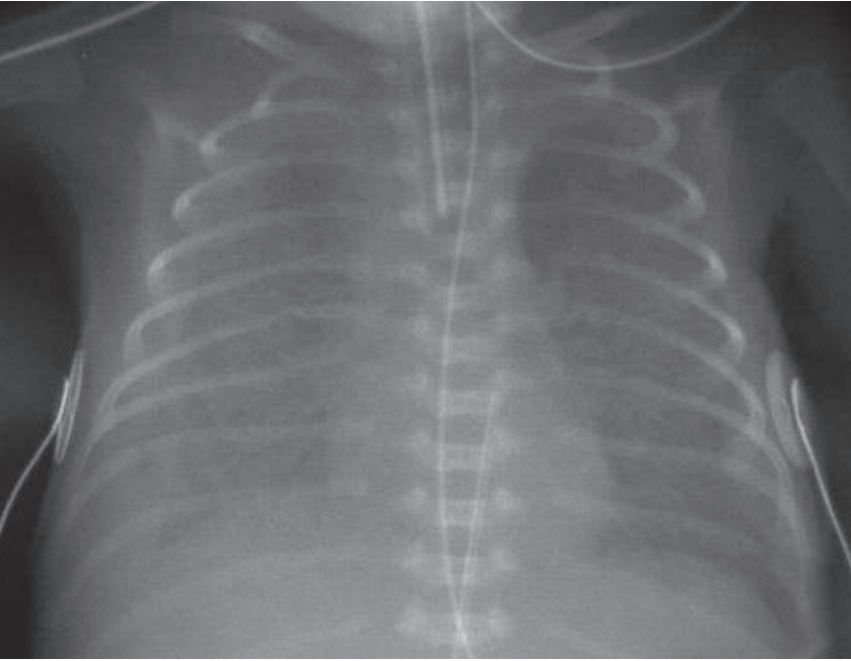


Fig. 1

Chest X-ray demonstrating a opacification of the right hemithorax and evidence of pleural effusion.

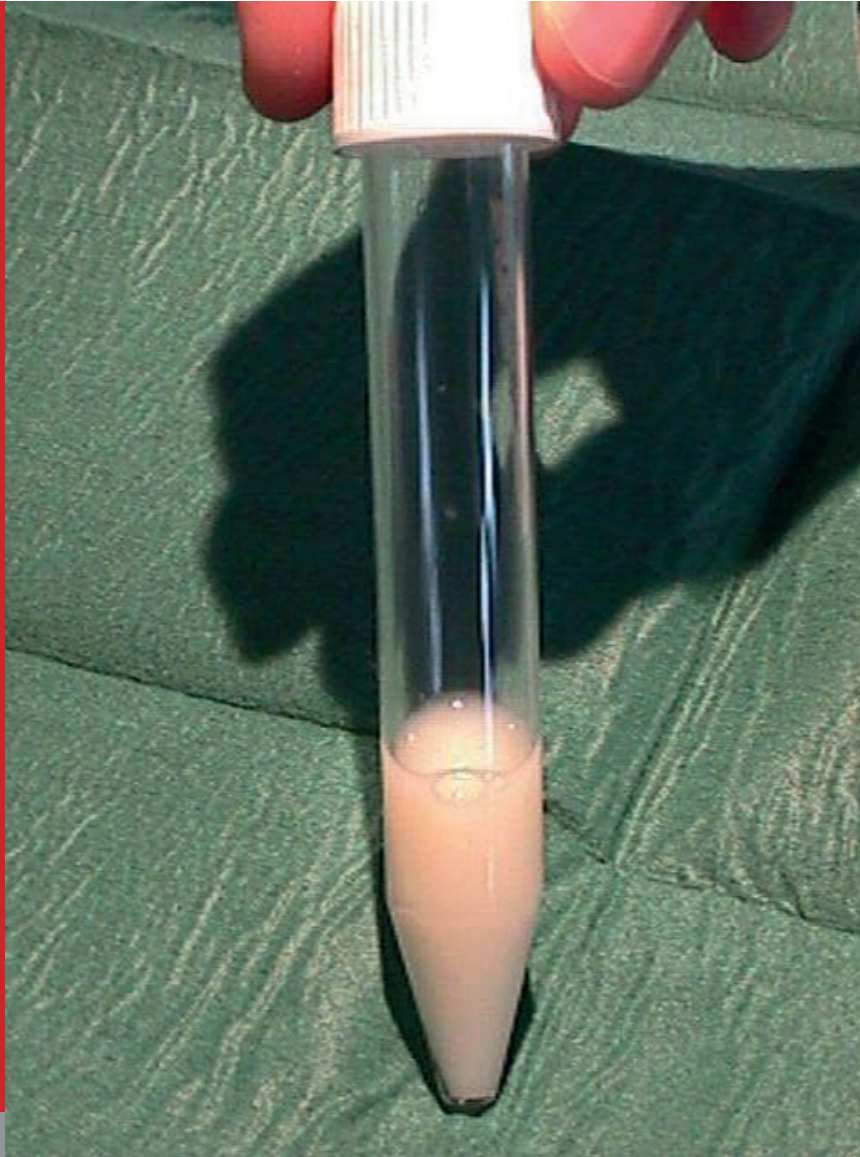


Fig. 2

Milky appearance of aspirated pleural fluid.

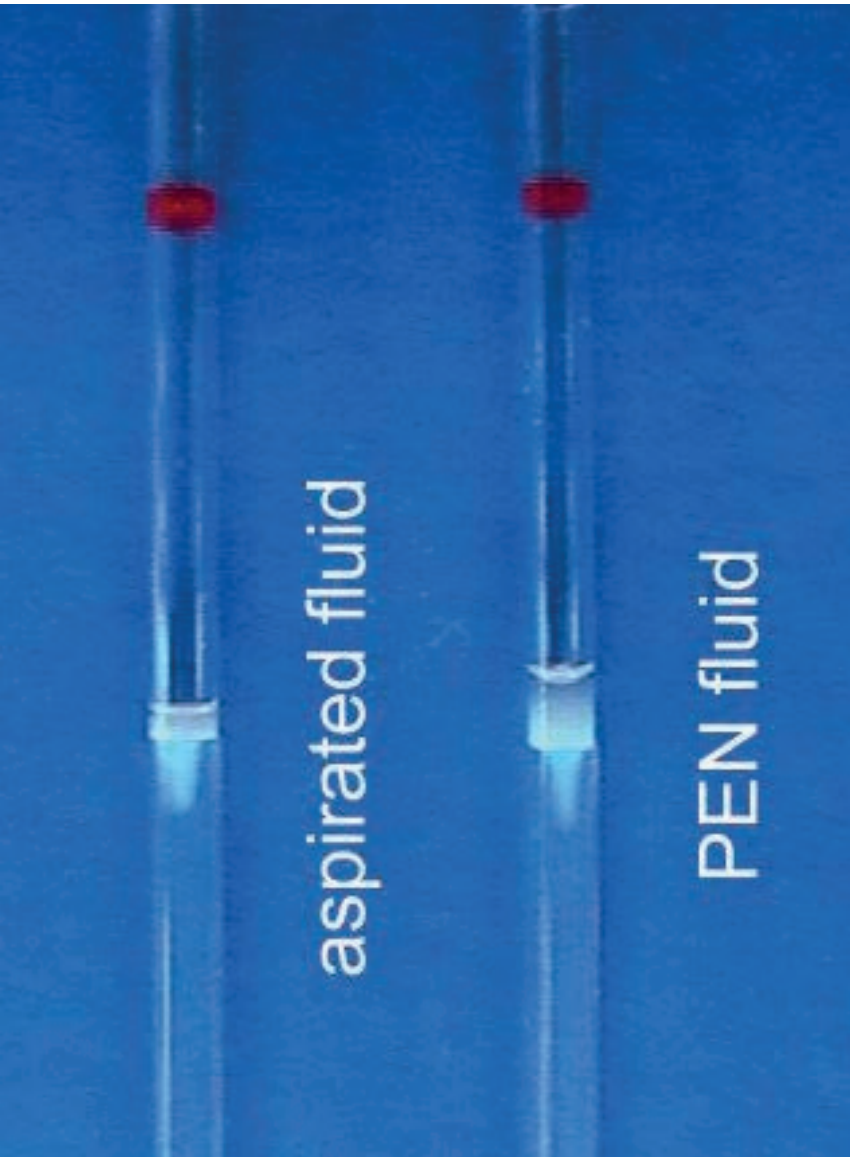


Fig. 3

Similar appearance of pleural aspirate and parenteral nutrition solution following centrifugation.

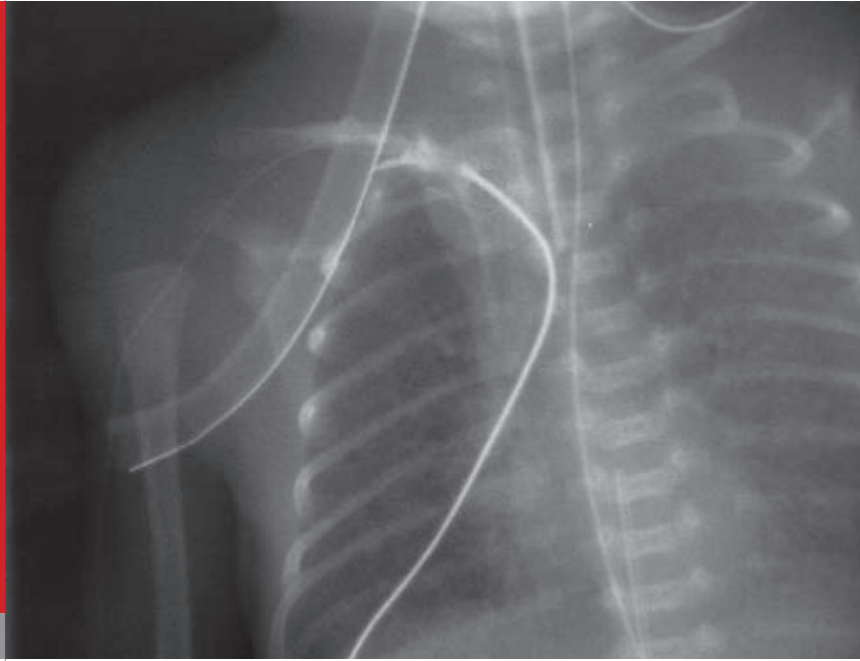


Fig. 4

Leaking contrast medium at the level of the right subclavian vein.

When a contrast medium was injected through the catheter, leakage into the pleural space was demonstrated at the level of the right subclavian vein (Fig. 4). Following pleurocentesis, the patient's respiratory status improved rapidly and he was extubated the following day. The PICC was replaced, and partial parenteral nutrition infusion was resumed. He eventually made an uneventful recovery and was discharged home at the corrected gestational age of 38 weeks.

Case 2

On the 7th day of life, this female preterm infant (gestational age 29 3/7 weeks, birth weight 1590 g) became increasingly restless and developed an increasing oxygen requirement while on nasal prong CPAP. She was noted to have poor peripheral perfusion but normal blood pressure. A sepsis evaluation was negative. A chest X-ray revealed cardiomegaly (Fig. 5). Shortly after intubation, she became bradycardic and no pulse oxymetry signal was detectable. Ultrasonography revealed a pericardial effusion. An emergency pericardiocentesis was performed and 15 ml of fluid were removed. Biochemical analysis confirmed that the parenteral nutrition solution given through a silastic catheter had caused the cardiac tamponade. Contrast medium was injected through the catheter and demonstrated that the catheter had migrated in to the right ventricle and possibly damaged the myocardial wall (Fig. 6). The infant recovered rapidly after pericardiocentesis.

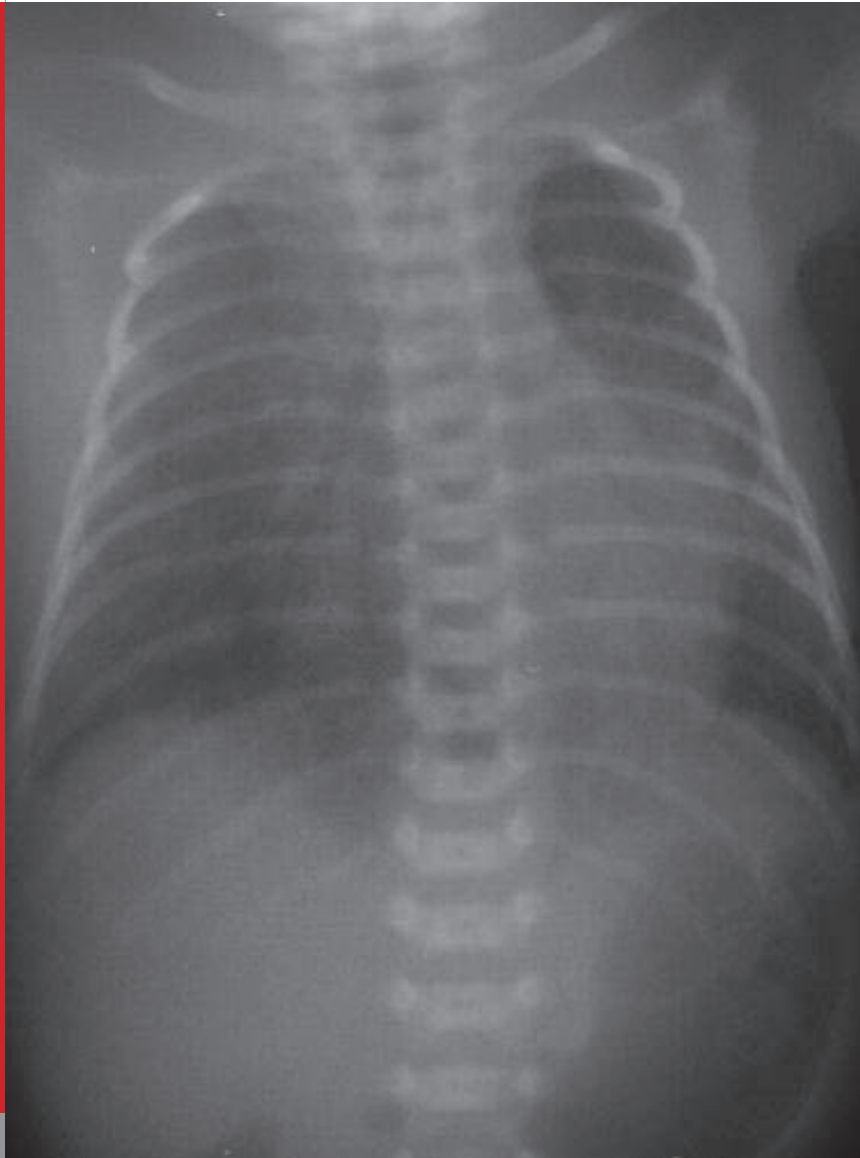


Fig. 5

Chest X-ray revealing cardiomegaly.

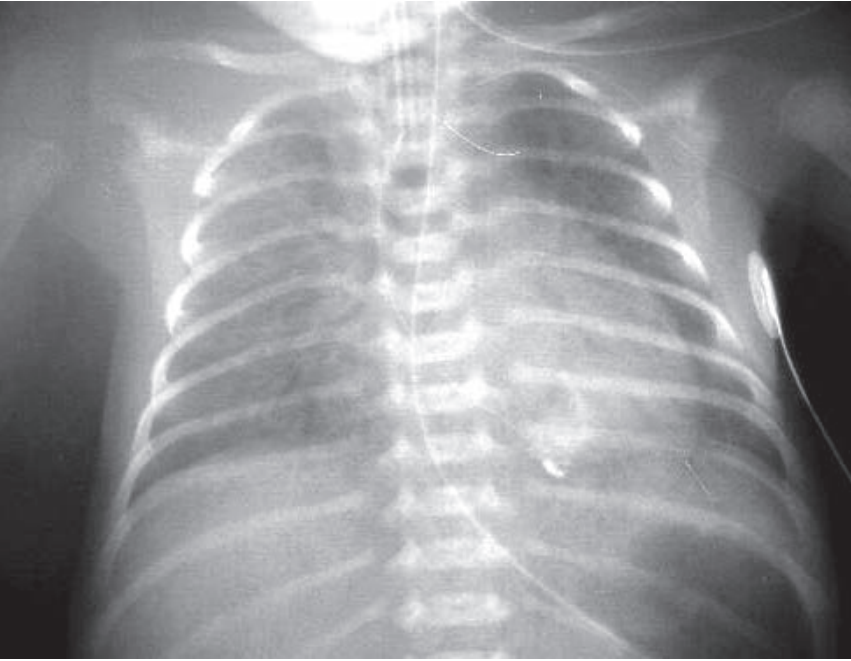


Fig. 6

Silastic catheter tip position projecting over the right ventricle.

DISCUSSION

Although the development of thin (24G and 27G) and durable catheters (usually made of polyurethane or silastic) has improved our ability to care for very low birth weight infants, the use of these catheters is not without risk. In a recently published survey (1) of 82 NICUs in the United States, a large percentage of units reported having seen severe complications at least once (Table).

Complications observed	Percentage of NICUs
Perforation of myocardium	29
Pericardial effusion	43
Pleural effusion	70
Death caused by cardiac tamponade	20
Death caused by arrhythmia	4
Mirgation and not Mirgation of catheter tip	1

Table (from Nadroo AM et al. J Pediatr 2001;138:599-601)

Based on the unacceptably high incidence of myocardial perforation, the authors suggest that the tip of the PICC should not be placed in the right atrium but should rather be positioned above the pericardial reflection line which corresponds to T2 on the radiograph (1).

The occurrence of cardiac tamponade in association with central venous catheters is not limited to neonates but has been described in adults as well (2). Endocardial injury is thought to be caused by either movement of the catheter tip with changes in arm,

neck and head position (in adults, cardiac tamponade is more frequent when catheters are inserted via peripheral rather than central veins), by movements of the cardiac chambers (cardiac cycle) or by direct trauma (particularly during insertion). Hyperosmolar solutions, such as parenteral nutrition, increase the risk of erosion and perforation of a vein wall or the endocardium.

In conclusion, a gradual or sudden deterioration in the condition of a neonate who has a PICC in place should prompt rapid evaluation for possible PICC complications. Cardiac tamponade, in particular, has to be ruled out immediately. When present, pericardiocentesis can be life-saving.

REFERENCES

1. Nadroo AM, Lin J, Green RS, Magid MS, Holzman IR. Death as a complication of peripherally inserted central catheters in neonates. *J Pediatr* 2001;138:599-601 (*Abstract*)
2. Booth SA, Norton B, Mulvey DA. Central venous catheterization and fatal cardiac tamponade. *Br J Anaesth* 2001;87:298-302 (*Abstract*)

SUPPORTED BY



CONTACT

Swiss Society of Neonatology

www.neonet.ch

webmaster@neonet.ch