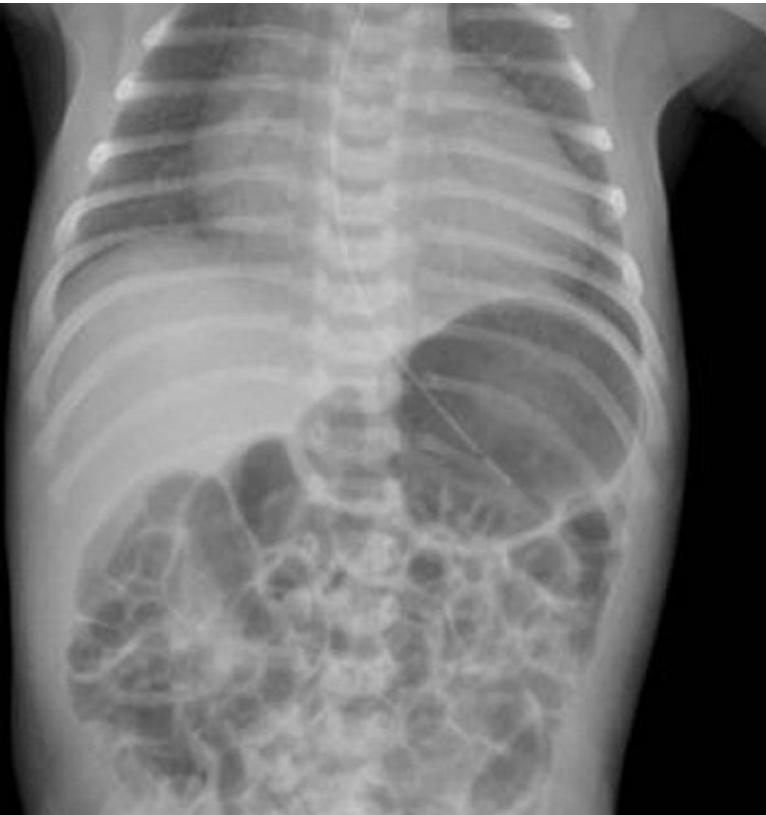

SWISS SOCIETY OF NEONATOLOGY

## Prenatal closure of the ductus arteriosus

March 2007



Leone A, Fasnacht M, Beinder E, Arlettaz R, Neonatal Intensive Care Unit (LA, AR), University Hospital Zurich, Cardiology Unit (FM), University Children's Hospital Zurich, Department of Obstetrics (BE), University Hospital Zurich, Switzerland

A 21-year-old G3/P2 had an uneventful pregnancy until the 38th week of pregnancy. At this time, prenatal closure of the fetal ductus arteriosus with severe dilatation of the right ventricle (Fig. 1) and tricuspid valve regurgitation was suspected on fetal ultrasound. The mother had not received any medications, particularly no non-steroidal anti-inflammatory agents (NSAIDs), during her pregnancy. There was no history of malformations or genetic disorders in the family. All previous ultrasound examinations had been reported to be normal.

Based on these findings, delivery by caesarean section was performed on the same day. A 3050 g boy was born with an Apgar score of 7 and 9 at 5 and 10 minutes, respectively. The arterial cord pH was 7.20. After birth, he developed moderate respiratory distress with a transient need for supplemental oxygen and a tachypnea of 70 breaths per minute. He was transferred to the neonatal intensive care unit.

Cardiac examination revealed a hyperdynamic precordium without thrill and a loud single second heart sound, a 3/6 holosystolic murmur best heard at the left parasternal border and at the apex with radiation to the chest and the back, as well as a gallop rhythm. The peripheral pulses were well palpable and blood pressure was normal. There was no hepatomegaly and no other clinical signs of heart failure.

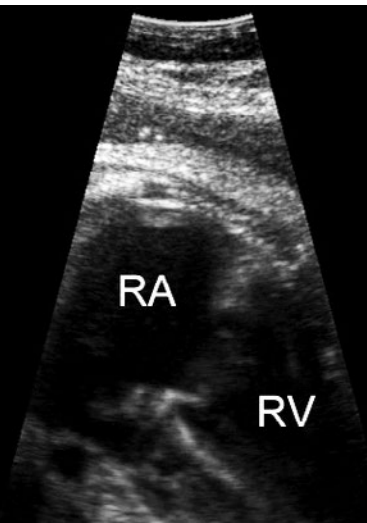

Fig. 1

*Fetal ultrasound at 38 weeks' gestation: enlarged right atrium (RA) and right ventricle (RV).*

Echocardiography performed in the delivery room showed an enlarged hypertrophied right ventricle (Fig. 2) with impaired contractility, pulmonary valve regurgitation and severe tricuspid regurgitation with a dysplastic tricuspid valve (Fig. 3). The ductus arteriosus was closed. There was marked pulmonary hypertension with a systolic pulmonary pressure of 65 to 70 mmHg, equal to the systemic blood pressure. ECG showed moderate signs of right ventricular hypertrophy. The babygram revealed cardiomegaly with a cardiothoracic index of 0.7 (Fig. 4). The clinical course in the neonatal care unit was uncomplicated with rapid resolution of the respiratory distress. Follow-up echocardiography on day 3 showed significant improvements: the right ventricle was less dilated but still hypertrophied, tri-

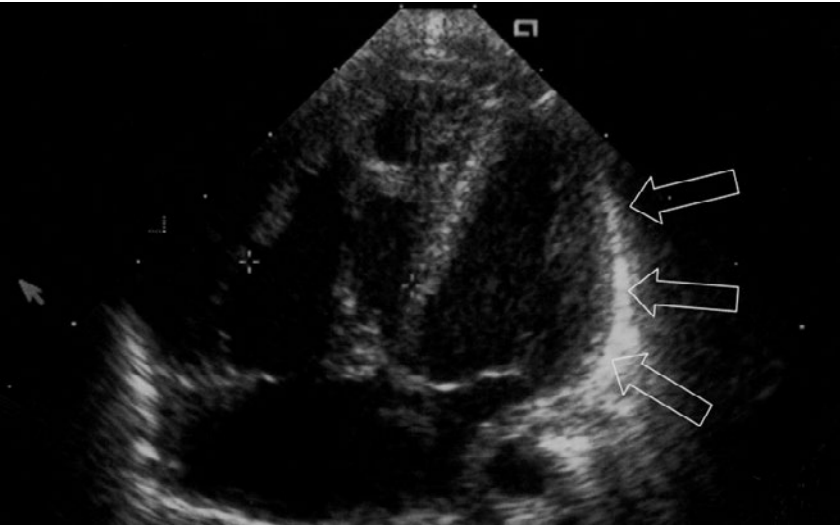

Fig. 2

*Postnatal echocardiography (day 1): right ventricular hypertrophy (arrows).*

cuspid regurgitation was mild, the estimated pulmonary pressure was half of the previous measurement, and the shunt across the foramen ovale was left to right. Clinical examination revealed a soft heart murmur and no gallop rhythm. Blood pressure had always been normal. On the fourth day of life, the boy was transferred to the nursery and discharged home 2 days later.

At the age of one month, his weight was 4500 g, and the clinical examination completely normal. The ECG showed sinus rhythm without any signs of hypertrophy of the right ventricle. Echocardiography was also normal and further follow-up was deemed unnecessary.

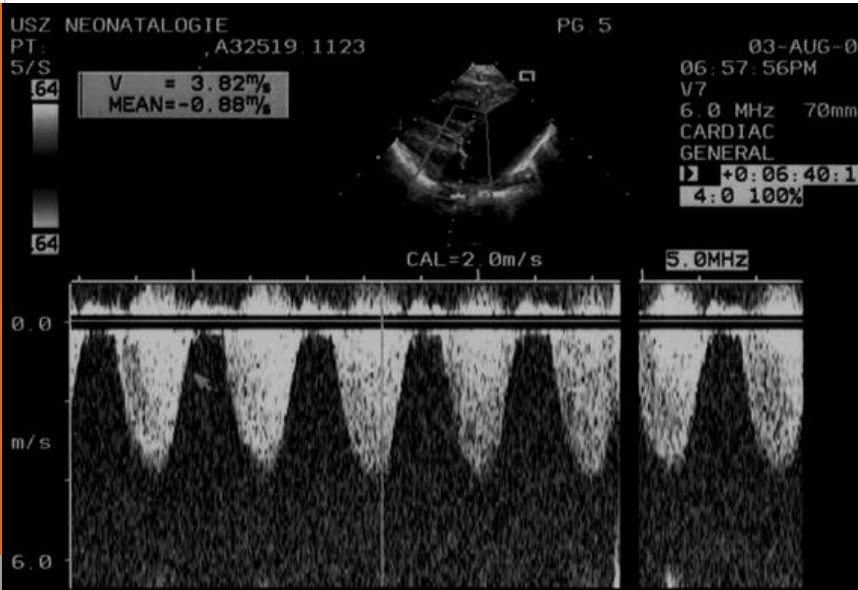


Fig. 3

*Postnatal echocardiography (day 1): tricuspid valve regurgitation.*

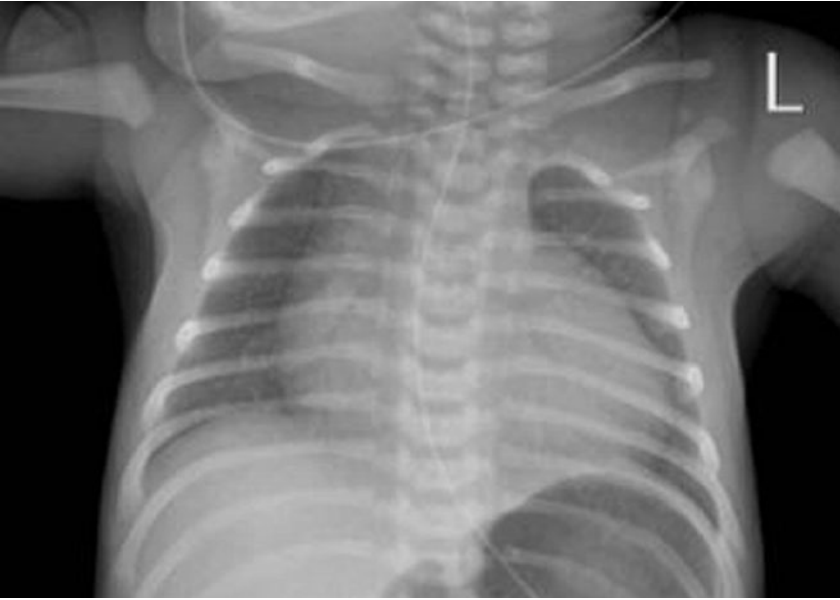

Fig. 4

*Babygram (day 1): cardiomegaly.*

## DISCUSSION

The ductus arteriosus originates from the 6th branchial arch and represents a muscular artery, whereas the pulmonary and aortic vessels are elastic arteries (1). The patency of the arterial duct is maintained during gestation by locally produced and circulating prostaglandins. As pregnancy advances, the ductus becomes less sensitive to prostaglandins and more sensitive to constricting factors such as prostaglandin synthetase inhibitors (2, 3). Fetal closure of ductus arteriosus can be caused by maternal medications in the form of prostaglandin synthetase inhibitors such as NSAIDs or by corticosteroids. Spontaneous or idiopathic constriction of the ductus arteriosus has also been reported but is rare (4-6).

If the ductus arteriosus closes antenatally, blood from the right heart is diverted into the lungs, resulting in increased right ventricular afterload because of physiologic pulmonary vasoconstriction, which in turn leads to impaired right ventricular function, tricuspid regurgitation and right heart failure. After birth, the right ventricular pressure normalises because of the physiologic decrease in pulmonary vascular resistance with rapid normalization of right ventricular function.

Fetuses affected by antenatal constriction of the ductus arteriosus may present with various signs of intrauterine cardiac failure which may end in prenatal or perinatal death (5). In every reported case of prenatal closure of the ductus arteriosus, there have



been consistent sonographic findings: cardiomegaly, dilatation of the main pulmonary artery, the right ventricle and the right atrium, tricuspid regurgitation, and no visualization of the ductus. Fetal hydrops has also been described (6). There are no reports of any associated anomalies.

The neonatal course correlates with the severity of the prenatal echocardiography findings. If only tricuspid and pulmonary regurgitation are seen in the presence of right ventricular hypertrophy, the postnatal course shows a prompt recovery within the first few months of life. In contrast, if abnormal umbilical venous pulsations are present antenatally, postnatal ventricular dysfunction is still evident at 2 to 6 months of life (5).

Delaying delivery can threaten the survival of the fetus (8). Urgent delivery is associated with an excellent prognosis and is always indicated in a term pregnancy. In the case of a preterm infant, the risks due to prematurity should be carefully weighed against the risks of the fetal cardiac decompensation.

## CONCLUSIONS

Premature constriction or closure of the ductus arteriosus should be considered if a dilated, hypertrophied right ventricle with signs of right heart failure is seen on fetal ultrasound. The association with use of NSAIDs is well known, and therefore these medications should be administered with caution during pregnancy. When their use is inevitable, close monitoring of the fetus is recommended. If the pregnancy is close to term, early or immediate delivery may reduce perinatal mortality and morbidity (9).

1. Brezinka C, Gittenberger-de Groot AC, Wladimiroff JW. The fetal ductus arteriosus, a review. *Zentral Gynakol* 1993;115:423-432
2. Huhta JC, Cohen AW, Wood DC. Premature constriction of the ductus arteriosus. *J Am Soc Echocardiogr* 1990;3:30-34
3. Tumbarello R, Pisu F, Pisano E, Puddu R, Bini RM. Timely detection of premature closure of the ductus arteriosus in a full-term fetus. Important role of fetal echocardiography. *Minerva Ginecol* 1999;51:197-201
4. Chao RC, Ho ES, Hsieh KS. Doppler echocardiographic diagnosis of intrauterine closure of the ductus arteriosus. *Prenat Diagn* 1993;13:989-994
5. Hofstadler G, Tulzer G, Altmann R, Schmitt K, Danford D, Huhta JC. Spontaneous closure of the human fetal ductus arteriosus. A cause of fetal congestive heart failure. *Am J Obstet Gynecol* 1996;174:879-883
6. Leal SD, Cavalle-Garrido T, Ryan G, Farine D, Heilbut M, Smallhorn JF. Isolated ductal closure in utero diagnosed by fetal echocardiography. *Am J Perinatol* 1997;14:205-210
7. Mielke G, Steil E, Gonser M. Prenatal diagnosis of idiopathic stenosis of the ductus arteriosus associated with fetal atrial flutter. *Fetal Diagn Ther* 1997;12:46-49
8. Becker AE, Becker MJ, Wagenvoort CA. Premature contraction of the ductus arteriosus: a cause of fetal death. *J Pathol* 1977;121:187-191
9. Schiessl B, Schneider KTM, Zimmermann A, Kainer F, Friese K, Oberhoffer R. Prenatal constriction of the fetal ductus arteriosus: related to maternal pain medication? *Z Geburtsh Neonatol* 2005;209:65-68

SUPPORTED BY



CONTACT

Swiss Society of Neonatology

[www.neonet.ch](http://www.neonet.ch)

[webmaster@neonet.ch](mailto:webmaster@neonet.ch)