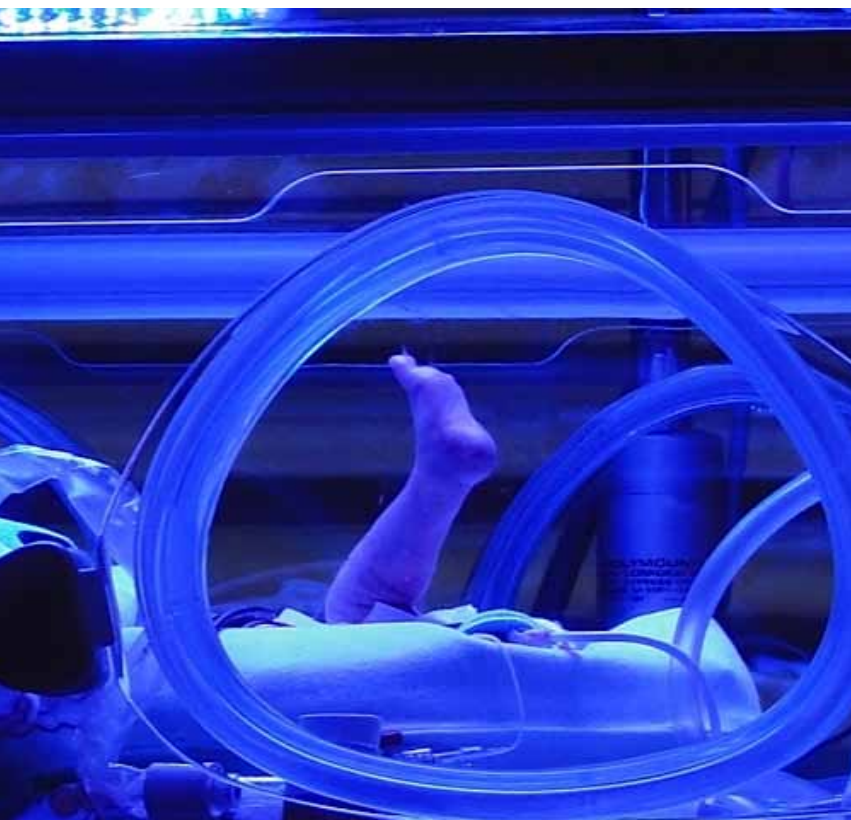

When a routine nursing  
procedure goes wrong:  
critical incident in a preterm  
infant

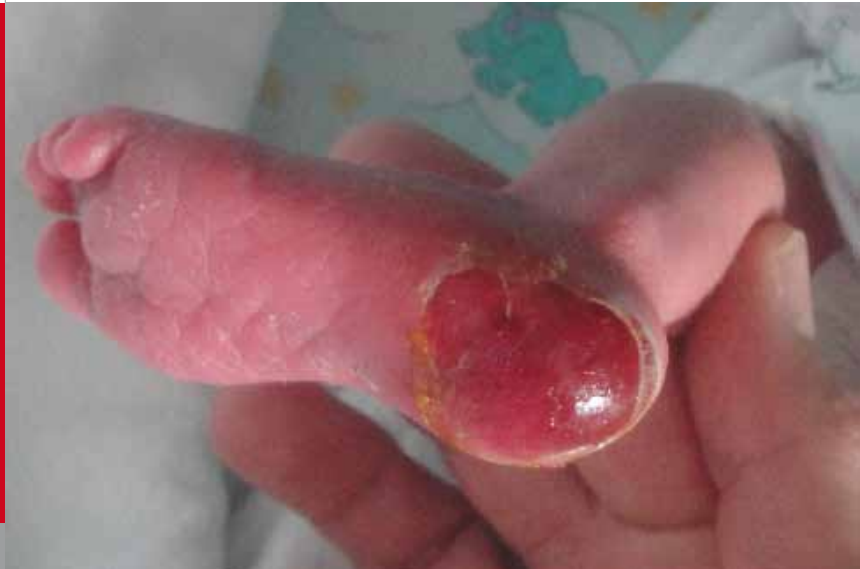May 2012



Fontana M, Seeger M, Neonatal and Pediatric Intensive  
Care Unit (FM), Department of Pediatrics, Department of  
Pediatric Surgery (SM), Children's Hospital of Lucerne,  
Switzerland

This twin girl was born to a 40-year-old G2/2+3 by cesarean section at 34 0/7 weeks of gestation because of severe preeclampsia. The monochorial diamniotic twin pregnancy had otherwise been uncomplicated. The infant adapted well with Apgar scores of 6, 8 and 8 at 1, 5 and 10 minutes, respectively. Her birth weight was 1730 g (P10). She required respiratory support with nasal CPAP for 24 hours because of wet lung syndrome. On day of life (DOL) 2, she was transferred to the intermediate care unit.

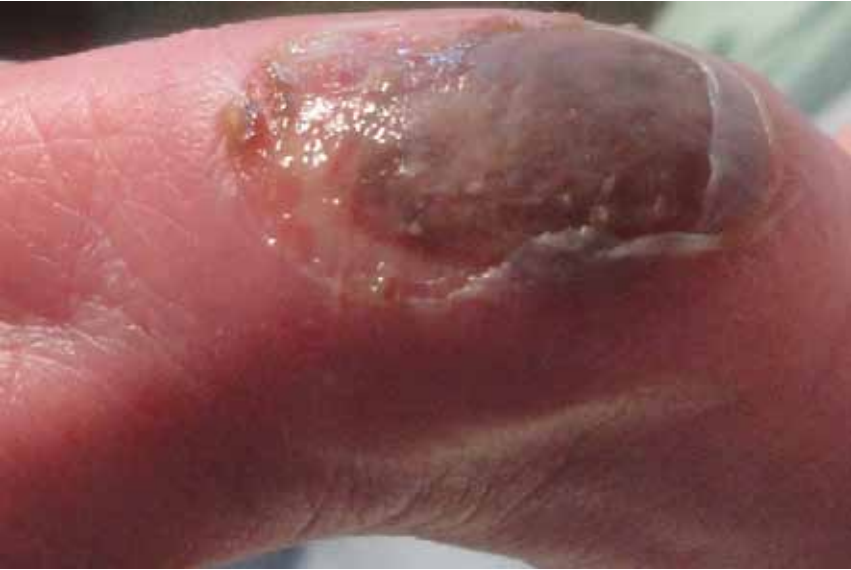On DOL 7, to facilitate blood sampling from a heel prick to measure her serum electrolytes, the nurse opted to use the "hot water in the diaper" technique. With this procedure, the lower leg and the foot of the child are wrapped in a warm wet cloth, with the aim to improve the circulation of the heel. To augment its efficacy, she also put a hot cherry pit pack on the infant's leg. After 5 minutes, when she wanted to do the blood test, she noticed a burn on the baby's heel.



**Fig. 1**

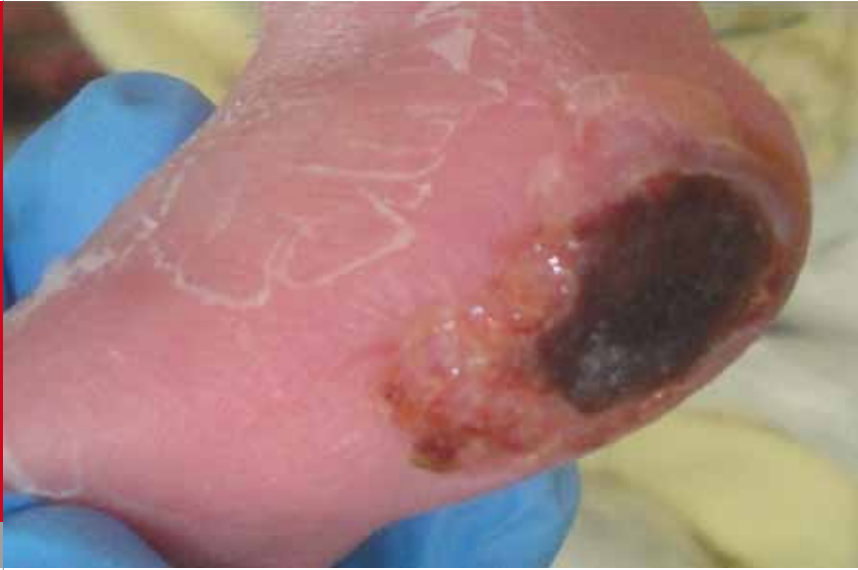*Day of injury: second-degree burn of the heel after removal of the blister.*

There was a large blister, compatible with at least a second-degree burn. Debridement was done (Fig. 1) and the wound was treated with a solution containing undecylamido-propyl betaine (tensid) and propyl-polihexanide (Prontosan®).

**Fig. 2**

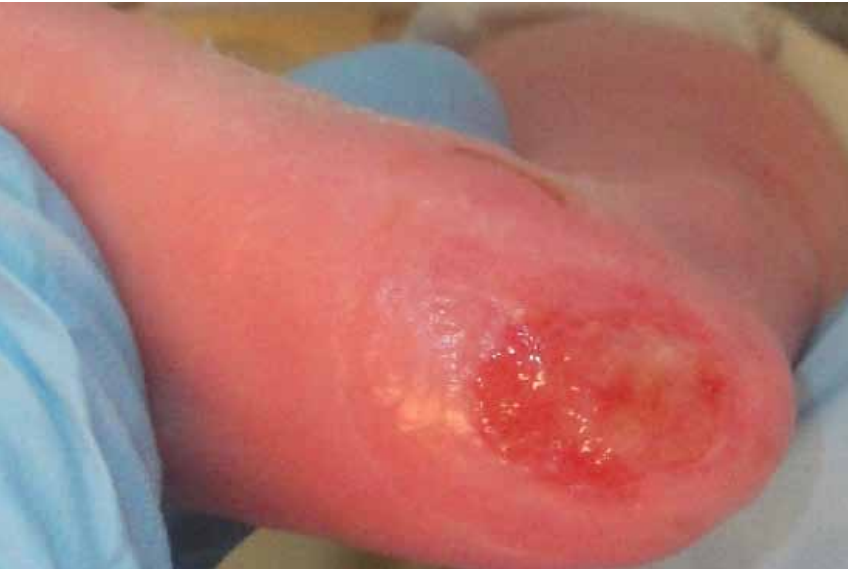*Day 3 after injury: a central area of necrosis, comparable with a third-degree burn, can be identified.*

After 3 days, there was an area of necrosis measuring 6x7 mm indicating a third-degree burn (Fig. 2). In the following days, dressings were done with a cream containing silver sulfadiazine and hyaluronic acid (Ialugen Plus®) and covered with an absorbent, atraumatic dressing made of polyurethane foam (Mepilex®).



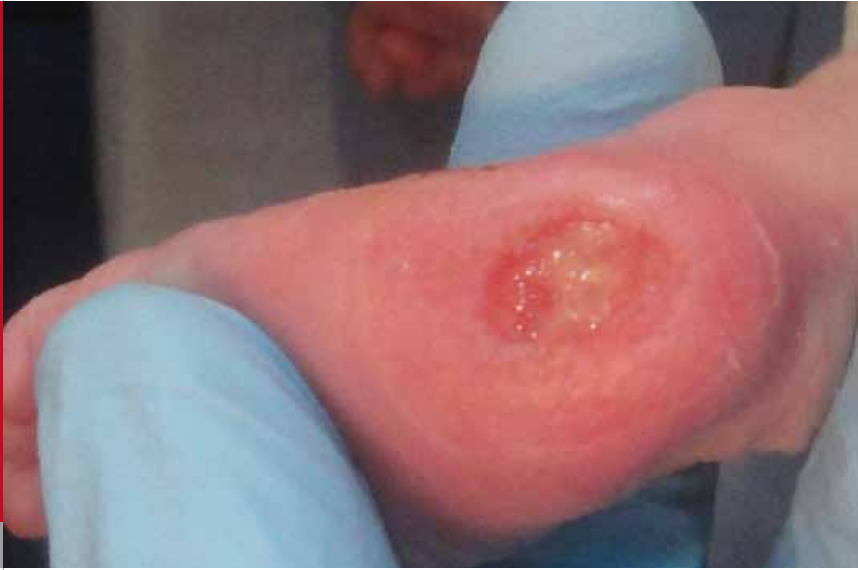**Fig. 3**

*Day 9 after injury: consolidation of the necrotic area.*

**Fig. 4**

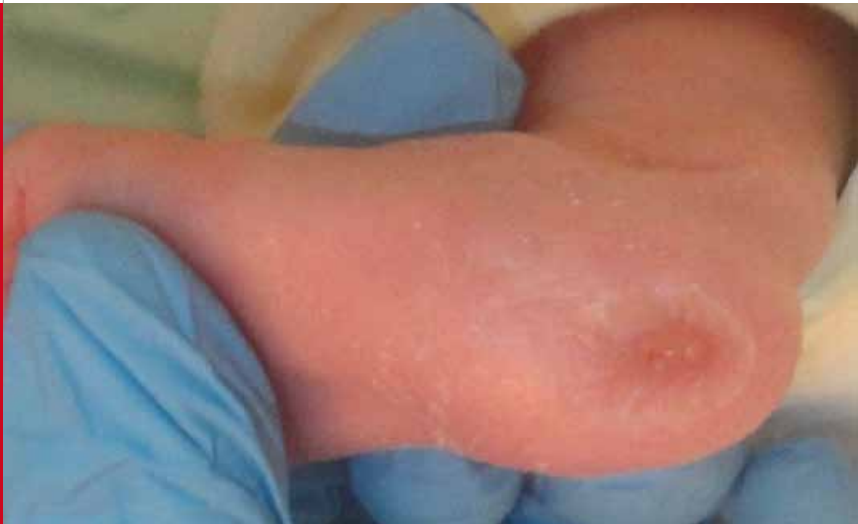
*Day 16 after injury: granulating wound can be recognized following detachment of the necrotic area.*

There were no signs of an inflammatory process; therefore, it was decided to continue with a conservative approach, without further necrosectomy, to avoid permanent damage to the calcaneus. One week after the incident, wound care was changed to dressings made of sodium carboxymethylcellulose and silver (Aquacel®), resulting in the detachment of the necrotic plate. Little by little the wound granulated (Fig. 4).



**Fig. 5**

*Day 20 after injury: the wound has become significantly smaller.*



**Fig.6**

*Day 30 after injury.*



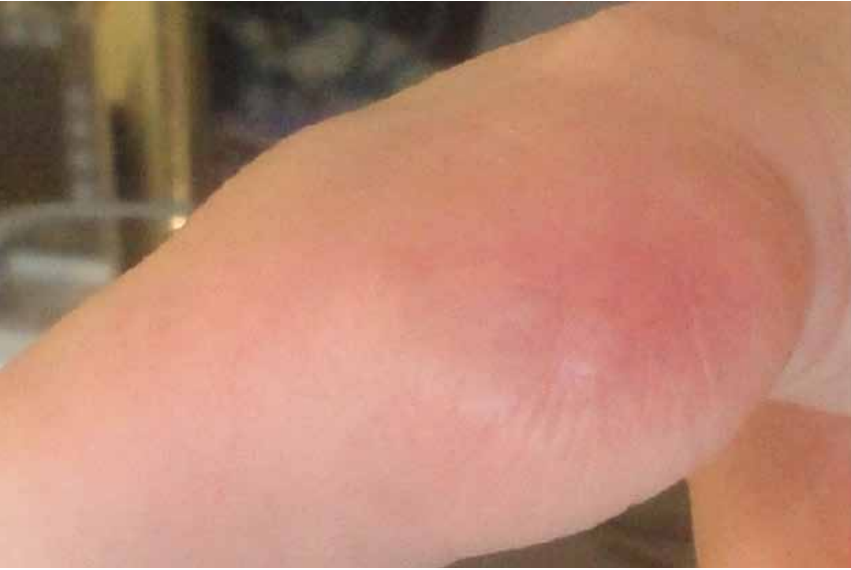

Fig. 7

*Day 50 after injury.*

After 3 weeks, there was a small residual moist wound area measuring 3 mm in diameter (Fig. 5). Treatment was then continued again with Ialugen Plus® resulting in complete wound healing with some scarring (Fig. 6). At discharge, the contour of the heel remained somewhat irregular (Fig. 7). It was suggested that the affected area be gently massaged with a fatty ointment (dexpanthenolum, Bepanthen®).

## DISCUSSION

Heel stick is one of the (painful) procedures commonly performed in premature and term infants. More than 30 years ago, Blumenfeld published an article with recommendations on how and where to prick the infants' heels to limit the risk of adverse events (1). Osteomyelitis of the calcaneus has always been the most feared painful complication leading to prolonged intravenous antibiotic therapy and permanent foot deformities that could preclude normal motility (2, 3).

Many studies have focused on methods to ease the infants' pain in association with heel sticks. The efficacy of oral sucrose has been demonstrated by several randomized controlled trials which were recently summarized in a meta-analysis (4). New methods, in addition or as alternatives to sucrose, are still the subject of research. Some studies investigated the use of opiates in addition to sucrose (5), others tested different doses of breast milk (6) or used mechanical vibration (7) as alternatives.

Prewarming the heel to increase blood flow is often used to prepare for a heel stick with the assumption that this procedure would facilitate blood sampling and therefore reduce the infants' pain. This procedure is widely performed both in nurseries and in neonatal intensive care units. The temperature of the diaper, the duration of the diaper's skin contact and the age dependent constitution of the skin contribute to the result of this procedure. In our case, the application

of a hot cherry pit pack increased the efficacy of the diaper and the combination of both provoked the burn.

Hassan and Shah reported a similar case (8) and, mostly based on two studies (9, 10), concluded that this technique should be abandoned. These studies showed no benefit of local prewarming with a patch compared with no prewarming. Obviously, local warming of the heel cannot be compared with the above described "hot water in the diaper" technique which enhances the perfusion of entire lower leg.

The presented case was discussed in context of the CIRS (critical incident reporting system), and despite the significant complication that had occurred, the practice was not banned. However, recommendations were made to prevent similar events. Hot cherry pit packs are no longer used. The temperature of the diaper must not exceed 40°C, the application time may not exceed 5 minutes and, above all, close observation must be guaranteed, particularly if the diaper is applied to the heel of immature preterm infants.

See also: COTM 01/2011: When a routine nursing procedure goes wrong: critical incident in a term infant.

## REFERENCES

1. Blumenfeld TA, Turi GK, Blanc WA. Recommended site and depth of newborn heel skin punctures based on anatomical measurements and histopathology. *Lancet* 1979;1(8110): 230-233
2. Goldberg I, Shauer L, Klier I, Seelenfreund M. Neonatal osteomyelitis of the calcaneus following a heel pad puncture: a case report. *Clin Orthop Relat Res* 1981;158:195-197
3. Abril Martin JC, Aguilar Rodriguez L, Albiñana Cilveti J. Flatfoot and calcaneal deformity secondary to osteomyelitis after neonatal heel puncture. *J Pediatr Orthop B* 1999;8: 122-124
4. Stevens B, Yamada J, Ohlsson A. Sucrose for analgesia in newborn infants undergoing painful procedures. *Cochrane Database Syst Rev* 2010 Jan 20;(1):CD001069
5. Harrison D, Loughnan P, Manias E, Smith K, Johnston L. Effect of concomitant opioid analgesics and oral sucrose during heel lancing. *Early Hum Dev* 2011;87:147-149
6. Ozdogan T, Akman I, Cebeci D, Bilgen H, Ozek E. Comparison of two doses of breast milk and sucrose during neonatal heel prick. *Pediatr Int* 2010;52:175-179
7. Baba LR McGrath JM, Liu J. The efficacy of mechanical vibration analgesia for relief of heel stick pain in neonates: a novel approach. *J Perinat Neonatal Nurs* 2010;24:274-283
8. Hassan Z, Shah M. Scald injury from the Guthrie test: should the heel be warmed? *Arch Dis Child Fetal Neonatal Ed.* 2005;90:F533-F534

9. Barker DP, Willetts B, Cappendijk VC, Rutter N. Capillary blood sampling: should the heel be warmed? *Arch Dis Child Fetal Neonatal Ed* 1996;74:F139–F140
10. Janes M, Pinelli J, Landry S, Downey S, Paes B. Comparison of capillary blood sampling using an automated incision device with and without warming the heel. *J Perinatol* 2002;22: 154–158

SUPPORTED BY



CONTACT

Swiss Society of Neonatology  
[www.neonet.ch](http://www.neonet.ch)  
[webmaster@neonet.ch](mailto:webmaster@neonet.ch)