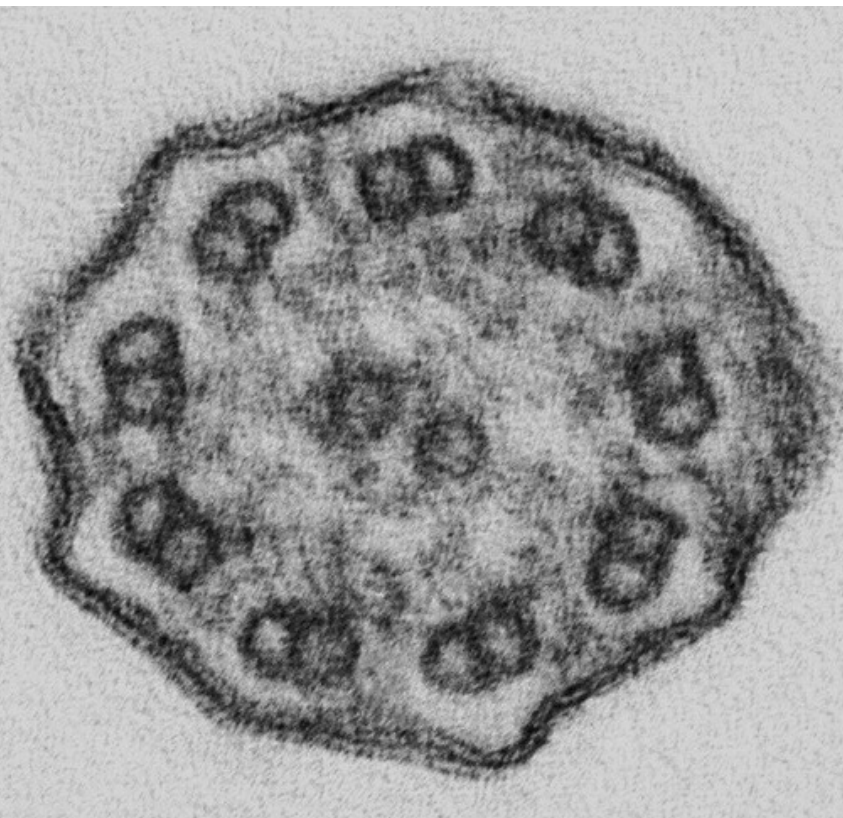


Kartagener's syndrome:
Neonatal respiratory distress
as initial symptom of primary
ciliary dyskinesia

MAY 2005



Christen M, and Berger TM, Neonatal and Pediatric
Intensive Care Unit, Children's Hospital of Lucerne,
Switzerland

Primary ciliary dyskinesia (PCD) is characterized by an inherited dysfunction of the ciliary apparatus. Propulsion of sperm as well as mucous clearance from the respiratory tract and middle ear are impaired. In 1902, Siewert first described a patient with situs inversus and bronchiectases, and, in 1933, Kartagener recognized a clinical syndrome consisting of situs inversus totalis, bronchiectases and chronic sinusitis. In 1975, Afzelius, Pederson and others described the absence of dynein arms in the tails of immotile sperm. The pathogenesis of PCD was further clarified when Afzelius and colleagues demonstrated the presence of non-functioning cilia in the respiratory tract of two patients with chronic pulmonary disease. The researchers also speculated that a lack of ciliary movement in embryonal tissue during development could result in random organ rotation, explaining that 50% of patients with PCD present with situs inversus totalis.

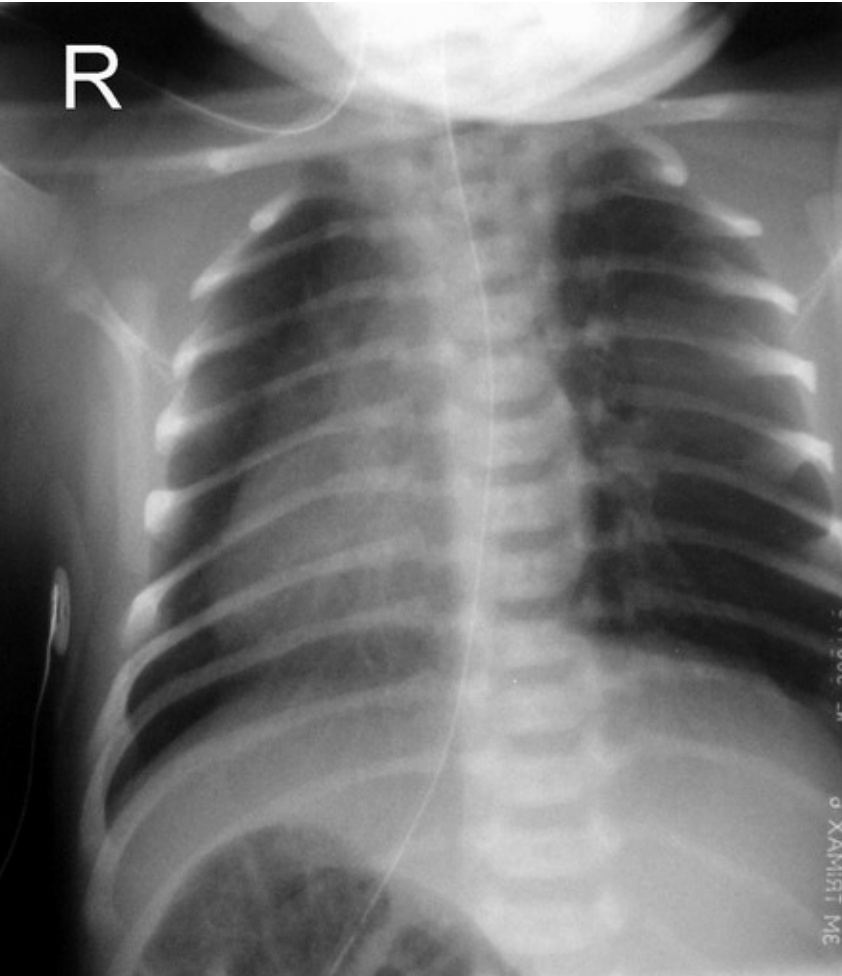
INTRODUCTION

We report on a full term male neonate (gestational age 38 3/7, birth weight 3480 g) who presented with mild respiratory distress at the age of 18 hours. He was the second child of a 32-year-old mother. Pregnancy had been unremarkable. He had been delivered by vacuum extraction because of late decelerations and meconium stained amniotic fluid. His primary adaptation was normal with Apgar scores of 7, 9, and 9 at 1, 5, and 10 minutes, respectively. Family history

CASE REPORT

revealed no parental consanguinity and no known hereditary diseases.

On admission, he was tachypneic with a respiratory rate of 80 breaths per minute. Transcutaneous oxygen saturation was 92% in room air. Heart sounds were louder over the right side of the chest. Clinical examination of the abdomen was normal. Suspected situs inversus was confirmed by chest X-ray (Fig. 1), echocardiography (Fig. 2) and abdominal ultrasound (Fig. 3). The signs of respiratory distress were mild but intermittent oxygen supplementation needed to be continued for 11 days. Antibiotics were discontinued after 72 hours when blood cultures had remained sterile. Nasal congestion with increased mucous production was noted during the infant's entire hospitalization. When asked specifically for respiratory illnesses in the family, the parents reported that his 3-year-old brother was suffering from non-seasonal chronic cough and rhinitis. Subsequently, he was found to have situs inversus totalis. Both siblings underwent further investigations. The levels of exhaled NO in the upper airways were markedly reduced. Biopsy of respiratory epithelium taken from the patients' upper airways revealed total lack of inner and outer dynein arms on electron microscopic examination (Fig. 4, 5). In comparison to normal cilia (movie 1), ciliary function in our patient was severely impaired (movie 2).



Chest X-ray.

Fig. 1

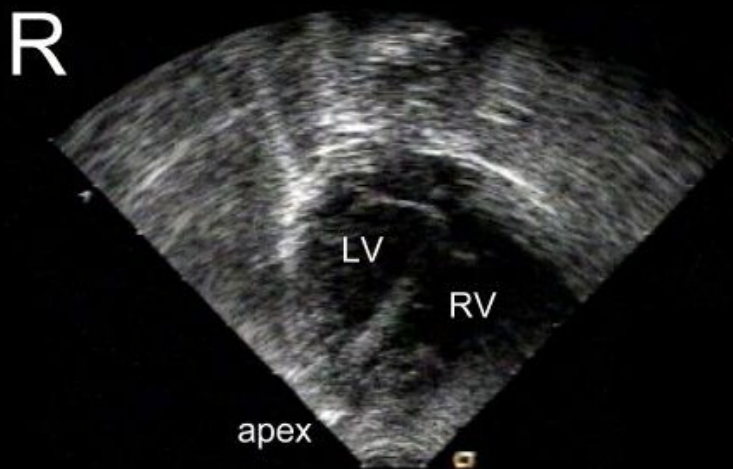


Fig. 2

Echocardiography.

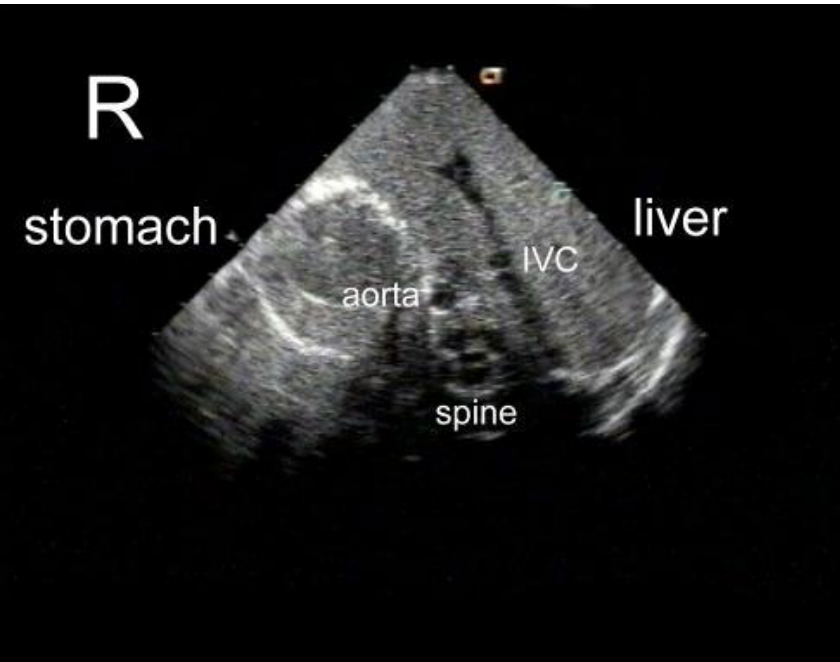


Fig. 3

Abdominal ultrasound.

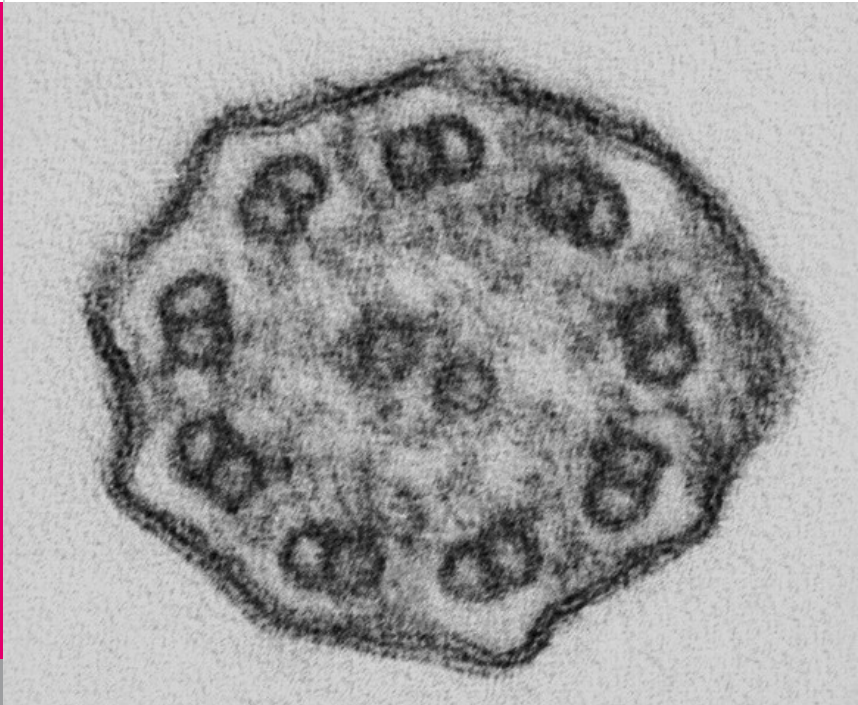


Fig. 4

*H&E stain: absence of ganglion cells in the myenteric
Transmission electron microscopy: lack of inner and
outer dynein arms in our patient.*

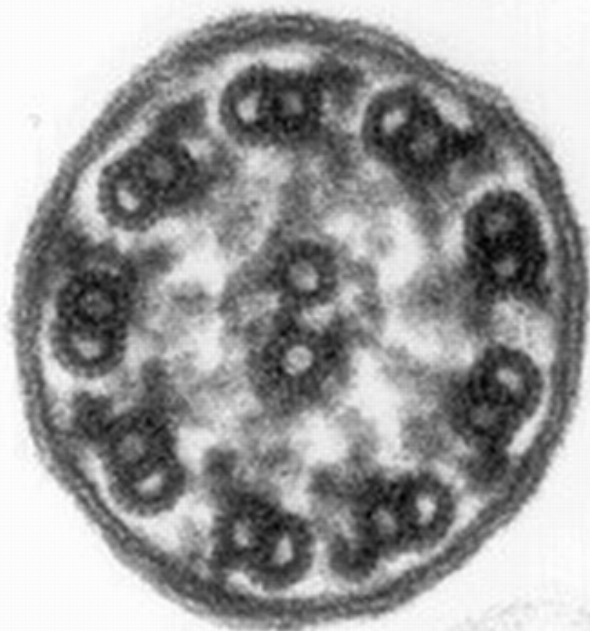

Fig. 5

Transmission electron microscopy: normal structure of ciliary apparatus.

DISCUSSION

The prevalence of PCD has been estimated at 1:15'000 (1). It is suspected that there is under-recognition of this disease and that it is diagnosed late (mean age 4.4 years) or not at all (1). Interestingly, symptoms often start in the neonatal period with unexplained respiratory difficulties (1, 2), followed by chronic rhinitis, bronchitis, sinusitis and serous otitis media in infants and toddlers (3). Men are infertile, whereas women's fertility is between 25-60% (compared with a normal fertility rate of 80%).

50% of the patients show situs inversus. It is believed that there is a concentration gradient of proteins between the future right and left side that leads to the normal arrangement of organs in the visceral cavities. Embryonic nodal cells with monocilia are responsible to build up and maintain this concentration gradient. If their motility is impaired the arrangement of visceral organs is due to chance and results either in situs ambiguous or situs inversus (4).

Diagnosis is confirmed by demonstrating the ultrastructural defect of the cilia by electron microscopy. Interference contrast microscopy gives additional information about the functional impairment. Multiple ciliary defects have been identified, the most common being a lack of outer or inner dynein arms. The genetic pattern is yet unknown and probably heterogeneous. An autosomal recessive inheritance is suspected but dominant spontaneous mutations also occur (5).

The aim of early diagnosis is to prevent upper and lower airway morbidity. Therapy consists of suppor-

ting mucociliary clearance and antibiotic treatment of bacterial infections of the respiratory tract. Administration of antitussive agents is contraindicated. For more in-depth information, the reader is referred to two more recent reviews (6, 7).

We would like to thank our colleagues B. Sasse from the Institute of Pathology at the University Hospital of Zurich, R. Jentsch from the Research Division of the Department of Gynecology of the University Hospital of Zurich and R. Rebetez from the Federal Institute of Technology in Zurich.

ACKNOWLEDGEMENTS

REFERENCES

1. Coren ME, Meeks M, Morrison I, Buchdahl RM, Bush A. Primary ciliary dyskinesia: age at diagnosis and symptom history. *Acta Paediatr* 2002;91:667-669 (Abstract)
2. Felix H, Holzmann D. Function and ultrastructure of cilia in primary ciliary dyskinesia. *Schweiz Med Wochenschr* 2000;130:699-704
3. Von Ahrens P, Körbler H. Primäre ziliäre Dyskinesie: Klinik, Diagnostik und Differentialdiagnostik. *HNO aktuell* 2002.
4. Izpisua Belmonte JC. Die Entstehung des Situs inversus. *Spektrum der Wissenschaft*, Oktober 1999, Seite 36ff.
5. Dombi VH, Walt H. Primäre ziliäre Dyskinesie, „immotile-dilia syndrome“ und Kartagener-Syndrom: diagnostische Kriterien. *Schweiz Med Wochenschr* 1996;126:421-433
6. Bush A, Cole P, Hariri M, Mackay I, Phillips G, O'Callaghan C, Wilson R, Warner JO. Primary ciliary dyskinesia: diagnosis and standard of care. *Eur Respir J* 1998;12:982-988

SUPPORTED BY



CONTACT

Swiss Society of Neonatology
www.neonet.ch
webmaster@neonet.ch