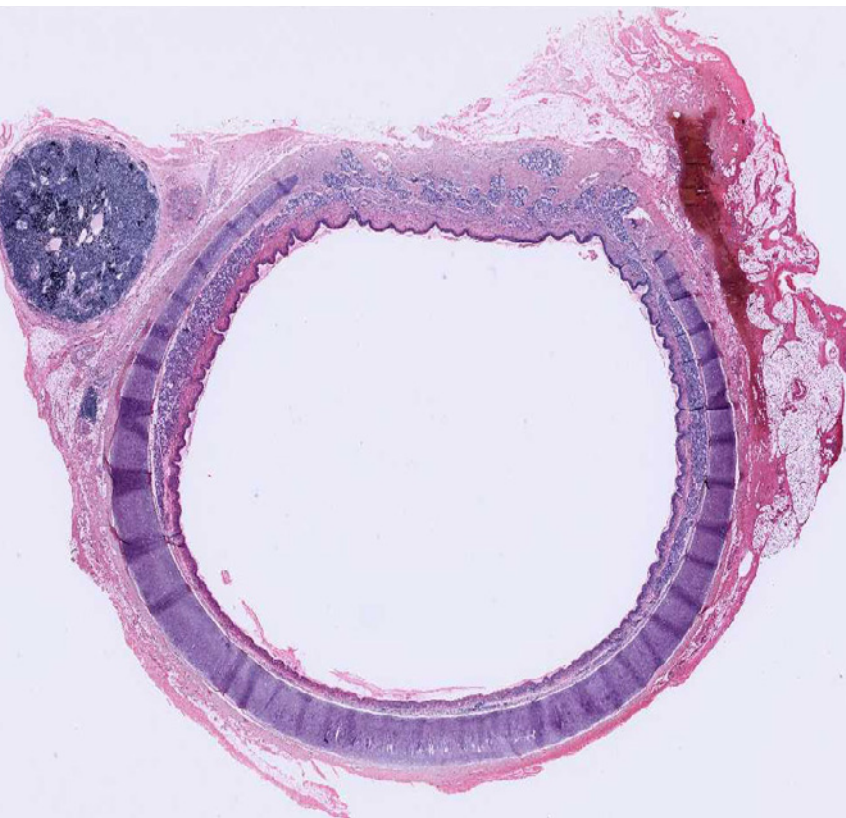

Tracheal agenesis:
still an unsolved problem

October 2009



Fontana M, Arcand PH, Payot A, Department of Neonatology (FM, PA) and Department of Otorhinolaryngology (APH), CHU Ste-Justine, Montréal, Canada

Title figure:

www.medcell.med.yale.edu

Tracheal agenesis (TA) is a rare and almost always fatal malformation of the foregut that in most cases is associated with other congenital anomalies. For the pediatrician in general and the neonatologist in particular, it is important to recognize the clinical signs of TA such as respiratory insufficiency, severe respiratory distress or difficult (or impossible) endotracheal intubation, in order to make adequate decisions in an unexpected emergency. Unfortunately, curative attempts of reconstruction of the airways are still experimental and long-term outcome is poor.

This male infant was born to a 31-year-old G5/P4/A1 at 33 0/7 weeks of gestation. Pregnancy was complicated by polyhydramnios, without signs of esophageal atresia or any other anatomic or functional abnormalities. His birth weight was 2510 g. Apgar scores were 1, 2 and 7 at 1, 5 and 10 minutes, respectively. At birth, no spontaneous respiration was noted and the boy was cyanotic and bradycardic. External chest compressions were applied during 30 seconds. Endotracheal intubation with a 3.0 endotracheal tube (ETT) was unsuccessful, as the tube did not pass the larynx. Intubation was achieved with difficulty with a 2.5 ETT. The infant could then rapidly be weaned from the ventilator and an attempt of extubation was made on day 2 of life. However, extubation failed because of important respiratory distress, cyanosis and bradycardia. Reintubation was only possible with a 2.0 ETT.

Because of ventilation difficulties (pH 7.09, pCO₂ 108 mmHg) he was referred to our hospital on day 3 of life. A chest X-ray (Fig. 1) showed areas of atelectasis and areas of hyperinflation. Laryngoscopy revealed hypoplastic supraglottic and glottic areas as well as a tracheoesophageal fistula. The distal esophagus was severely stenotic. Connected bronchi could not be visualized (movie: size 5 MB). CT scanning confirmed the diagnosis of congenital agenesis of the distal trachea with proximal tracheoesophageal fistula, stenosis of the distal esophagus and showed that the main stem bronchi were emerging from the ventral aspect of the esophagus at the level of the stenosis (Fig. 2-4). The distal findings are compatible with a Floyd type III anomaly but the presence of a hypoplastic larynx with a short proximal tracheal segment makes our case atypical for classic tracheal agenesis. The lateral view of the chest X-ray showed the nasogastric tube and the distal ETT being both in the esophagus (Fig. 5). Echocardiography did not show any cardiac anomalies.

A multidisciplinary team composed of pulmonologists, ENT specialists, thoracic surgeons, radiologists and neonatologists unanimously concluded that the reported treatments for tracheal TA were still experimental and that the associated morbidity and mortality were too high to attempt surgical repair of the malformation. Palliative care was instituted and the boy quietly died in the arms of his parents a few minutes after being extubated.

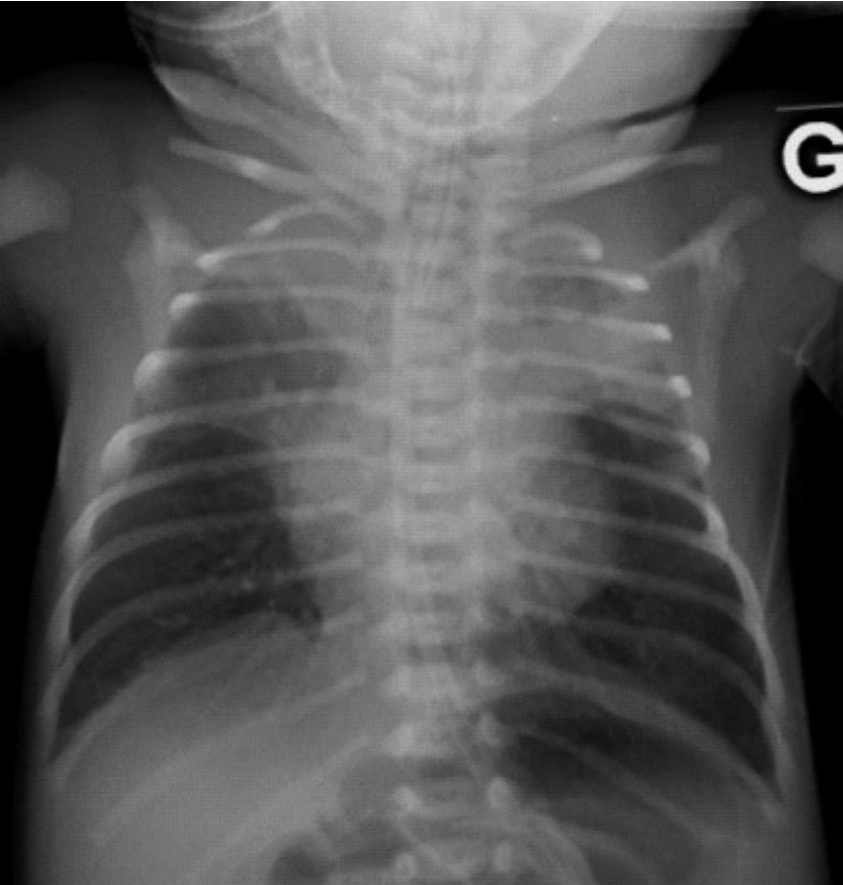


Fig. 1

Chest X-ray (ap view): patterns of atelectasis with areas of hyperinflation.

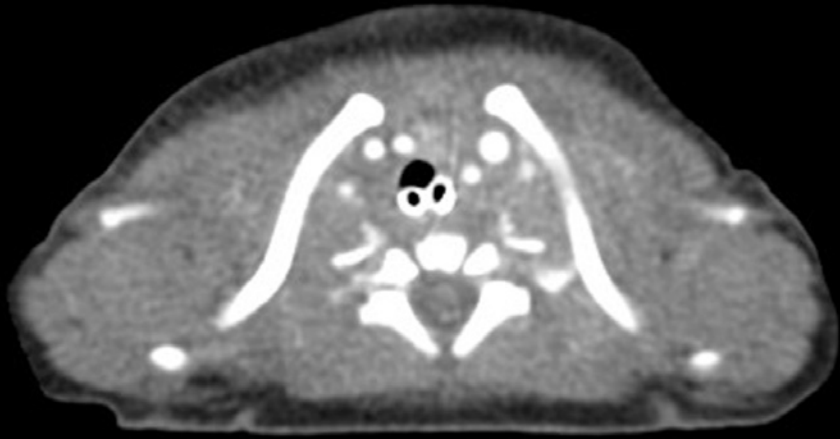

Fig. 2

Chest CT (axial view, upper thoracic region): both endotracheal tube and nasogastric tube are located in the esophagus.

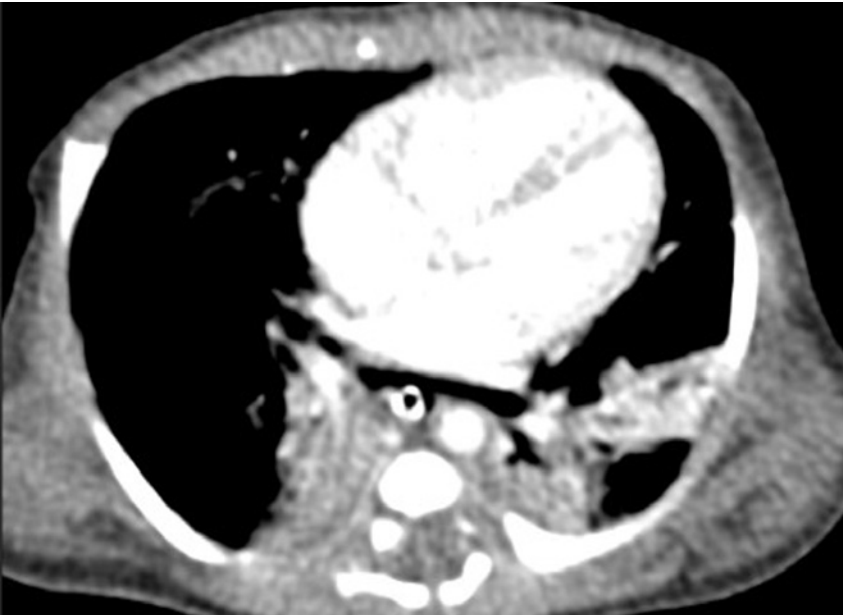

Fig. 3

Chest CT (axial view, mid-thoracic region): both bronchi emerge from the ventral aspect of the esophagus (containing a nasogastric tube).

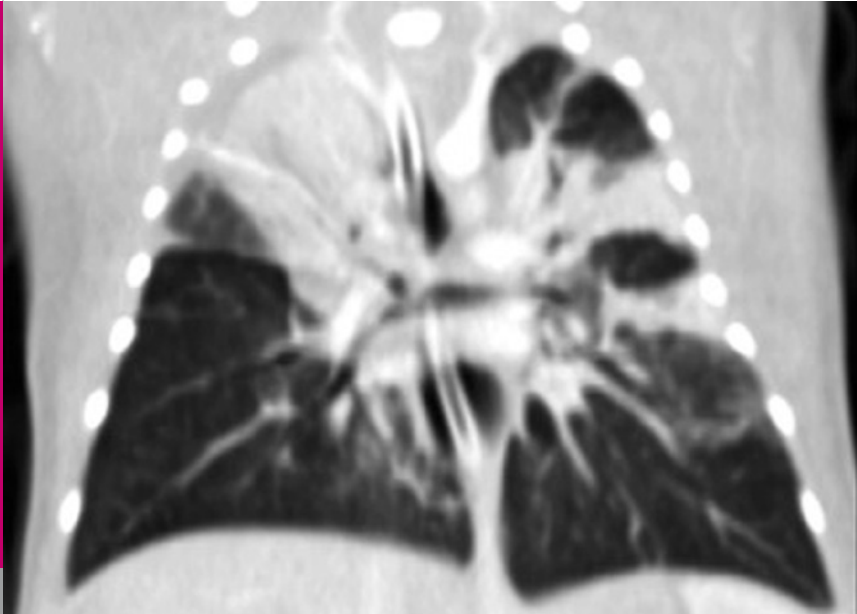


Fig. 4

Chest CT (coronal reconstruction): both bronchi emerge from the esophagus (containing nasogastric tube), there are bilateral atelectatic areas.

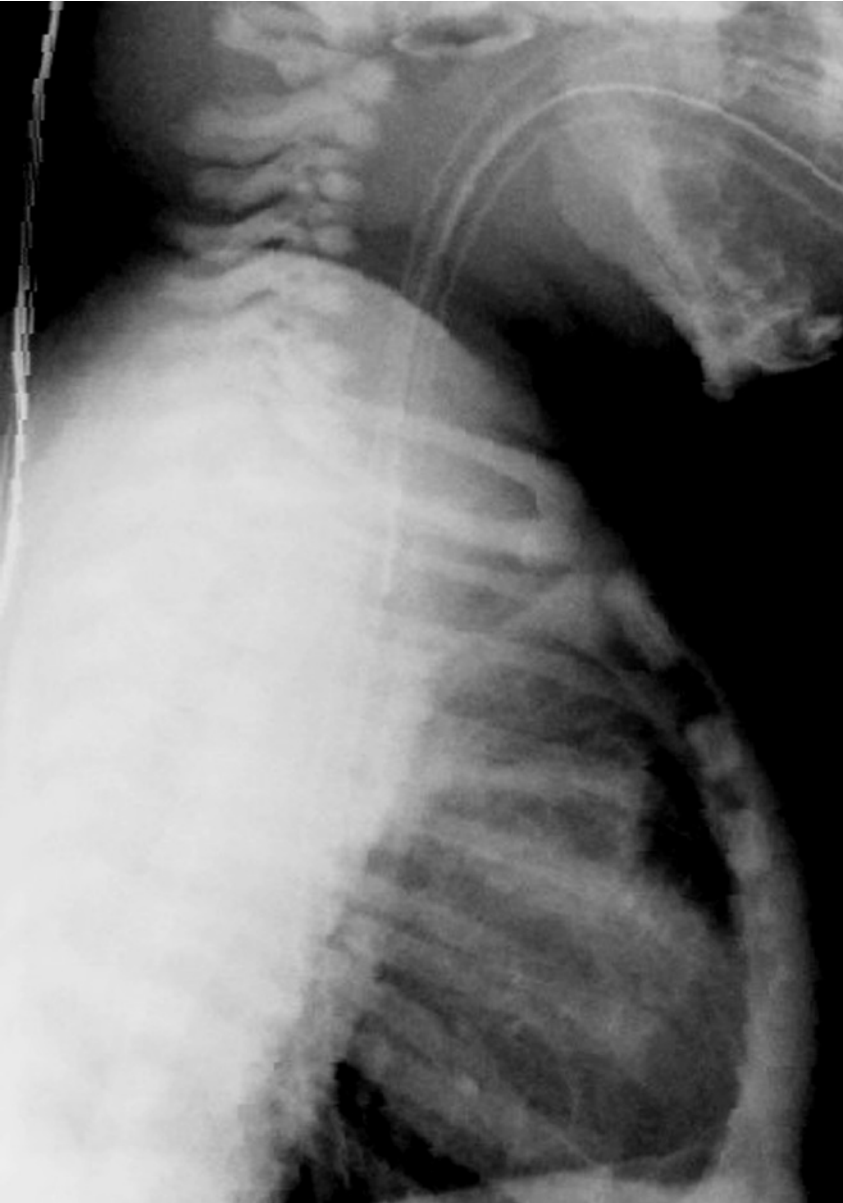

Fig. 5

Chest X-ray (lateral view): the nasogastric tube and the distal ETT are both in the esophagus.

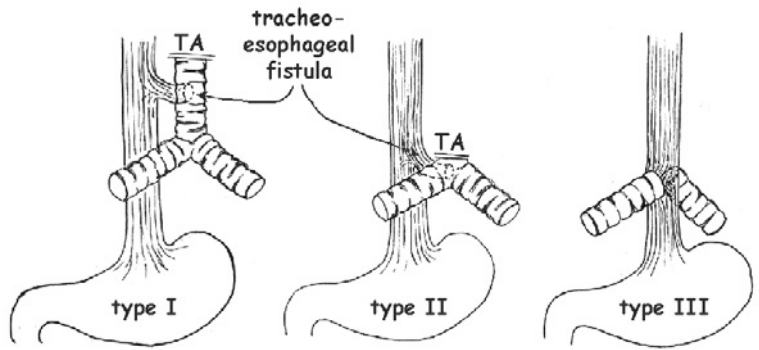


Fig. 6

Floyd classification of tracheal agenesis (6).

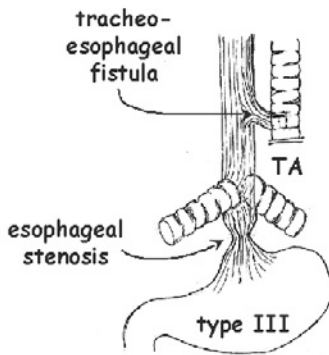


Fig. 7

Schematic drawing of the tracheal malformation seen in our patient: TA type III with proximal tracheo-esophageal fistula and distal esophageal stenosis.

DISCUSSION

Tracheal agenesis (TA) is a rare malformation with an incidence of less than 1:50'000 births. It was first described by Payne (1) in 1900. In the English literature, there have been reports of more than 150 cases of TA. In half of these cases, children were born prematurely and at least half of the pregnancies were complicated by polyhydramnios (2). Prenatal diagnosis with ultrasonography is very difficult. In some cases, diagnosis was possible with MRI when congenital high airway obstruction was suspected (3). Postnatal diagnosis can be suspected with contrast X-ray and confirmed by fiberoptic laryngoscopy (including tracheo- and esophagoscopy) and CT scan (4). TA can occur isolated or in association with other anomalies, such as the VACTERL association and the TACRD syndrome (an extremely rare condition with tracheal agenesis, cardiac, renal and duodenal malformations) (5).

In 1962, Floyd and colleagues (6) suggested the following classification of TA (Fig. 6):

Type I: agenesis of the proximal trachea with tracheo-oesophageal fistula to a short distal tracheal remnant

Type II: complete agenesis of the trachea with tracheo-esophageal fistula to communicating bronchi

Type III: complete agenesis of the trachea with the bronchi arising directly and separately from the esophagus

Fig. 7 depicts the complex tracheal malformation seen in our patient.

Attempts to surgically repair this otherwise lethal congenital malformation have been reported since 1963 (7). Reconstructive surgical attempts described have included trachealization of the esophagus, the use of allografts, autologous tissue or prosthetic material to replace the trachea. Only a few cases have been reported to survive for longer periods of time (8, 9). The most promising treatment to date seems to be the external esophageal stenting reported by Watanabe et al. (10). They used a Goretex external esophageal stent with radial traction sutures to prevent collapse of the esophagus which is one of the most important problems in the approaches that are based on trachealizing the esophagus. The greatest and still unresolved problem is the inability to provide a suitable ciliated epithelium to ensure the clearance of the reconstructed airways.

We would like to thank Fabienne Berger for the artwork in Figures 6 and 7.

ACKNOWLEDGEMENT

REFERENCES

1. Payne W. Congenital absence of the trachea. *Brooklyn Med J* 1900;14:568
2. Van Veenendaal MB, Liem KD, Marres HA. Congenital absence of the trachea. *Eur J Pediatr* 2000;159:8-13
3. Guimaraes CV, Linam LE, Kline-Fath BM, et al. Prenatal MRI findings of fetuses with congenital high airway obstruction sequence. *Korean J Radiol* 2009;10:129-134
4. Panthagani ID, Santos MC, D'Angio CT. Use of computed tomography to categorize the type of tracheal agenesis. *J Pediatr Surg* 2009;44:1044-1046
5. Wei JL, Rodeberg D, Thompson DM. Tracheal agenesis with anomalies found in both VACTERL and TACRD associations. *Int J Pediatr Otorhinolaryngol* 2003;67:1013-1017
6. Floyd J, Campbell DC, Jr., Dominy DE. Agenesis of the trachea. *Am Rev Respir Dis* 1962;86:557-560
7. Fonkalsrud EW, Martelle RR, Maloney JV, Jr. Surgical treatment of tracheal agenesis. *J Thorac Cardiovasc Surg* 1963;45:520-525
8. Soh H, Kawahawa H, Imura K, et al. Tracheal agenesis in a child who survived for 6 years. *J Pediatr Surg* 1999;34:1541-1543
9. Hiyama E, Yokoyama T, Ichikawa T, Matsuura Y. Surgical management of tracheal agenesis. *J Thorac Cardiovasc Surg* 1994;108:830-833
10. Watanabe T, Okuyama H, Kubota A, et al. A case of tracheal agenesis surviving without mechanical ventilation after external esophageal stenting. *J Pediatr Surg* 2008;43:1906-1908

