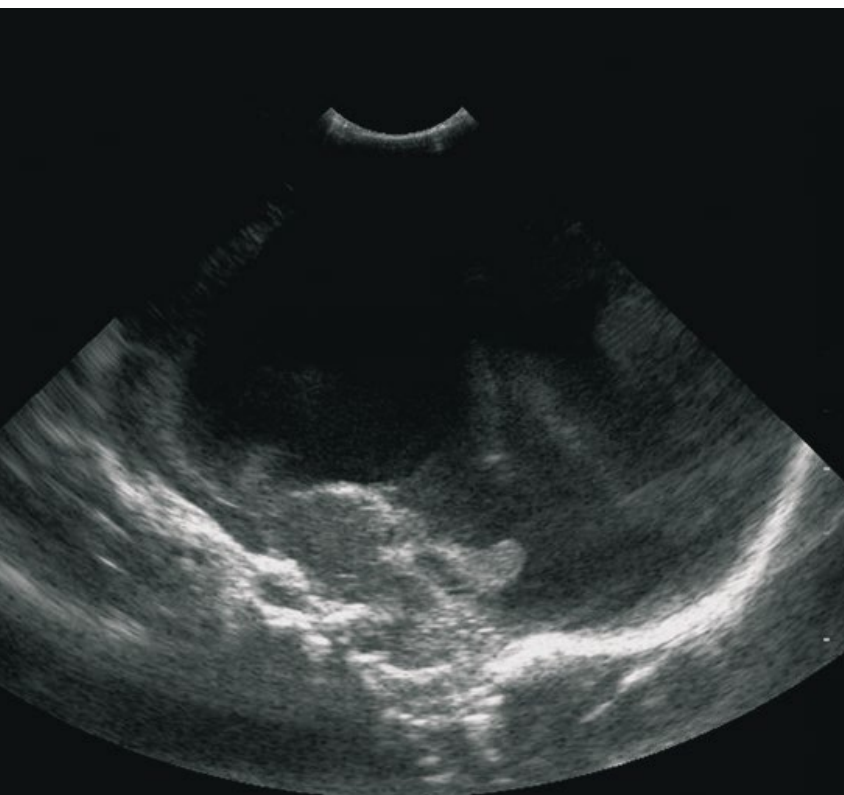


SWISS SOCIETY OF NEONATOLOGY

Two cases of live born infants
with triploidy syndrome

July 2006



This female infant was born to a 32-year-old G3/P1-2/A1 at 29 1/7 weeks of gestation at home following acute onset of vaginal bleeding. The mother's second pregnancy had resulted in an early abortion at 5 weeks. Two months before birth, the obstetrician had noticed a large placenta but no other abnormalities. The mother dried her infant and alerted the EMT service. The neonatal transport team arrived at 15 minutes of age. Several dysmorphic features were noted, including a large myelomeningocele, bilateral proptosis and syndactyly between digits III and IV bilaterally. The infant was intubated and transported uneventfully to the Children's Hospital of Lucerne.

The girl weighed 990 g (P10), her length was 36 cm (P10-25) and her head circumference was 25.5 cm (P10-25). There were large fontanelles (anterior: 3x5 cm, posterior 3x3 cm), bilateral proptosis (right > left) with iris colobomata (Fig. 1), bilateral complete 3/4 syndactyly of fingers (Fig. 2), a simian crease on the left, and a large lumbar myelomeningocele (Fig. 3). On cerebral ultrasound, there was unilateral hydrocephalus and intraventricular hemorrhage. The placenta was noted to be very large (926 g) with a subchorial hematoma and mild chorionitis. Based on the above findings, combined with severely impaired oxygenation secondary to persistent fetal circulation, care was redirected and the infant died at 6 hours of age. Chromosomal analysis revealed a triploid karyotype (69, XXX).

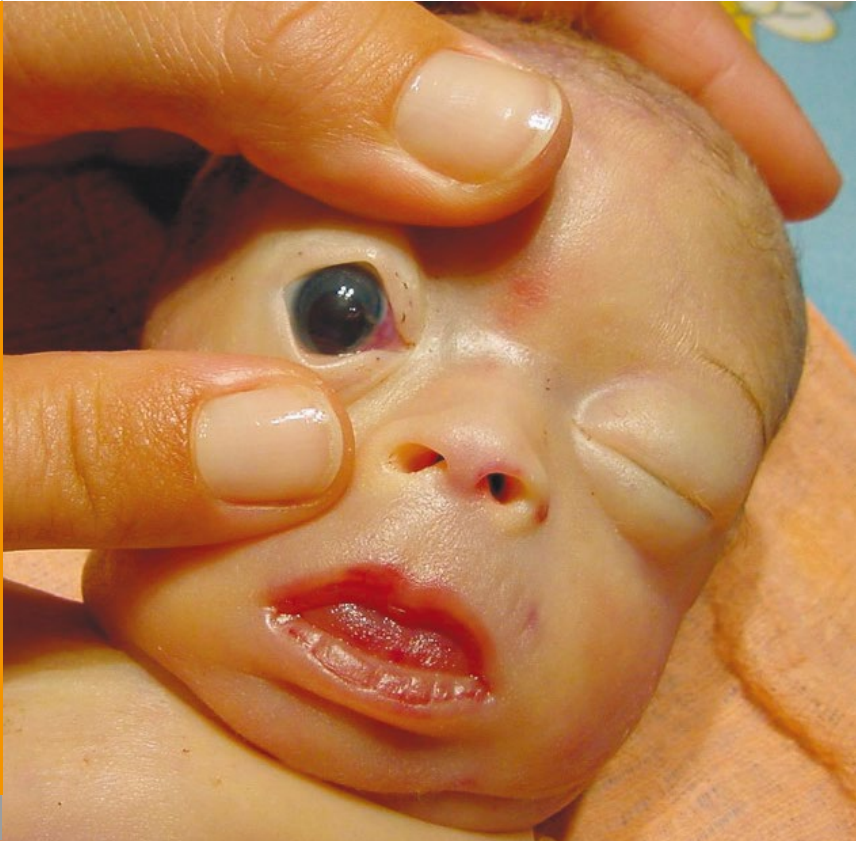

Fig. 1

Bilateral proptosis, iris colobomata, and macroglossia.

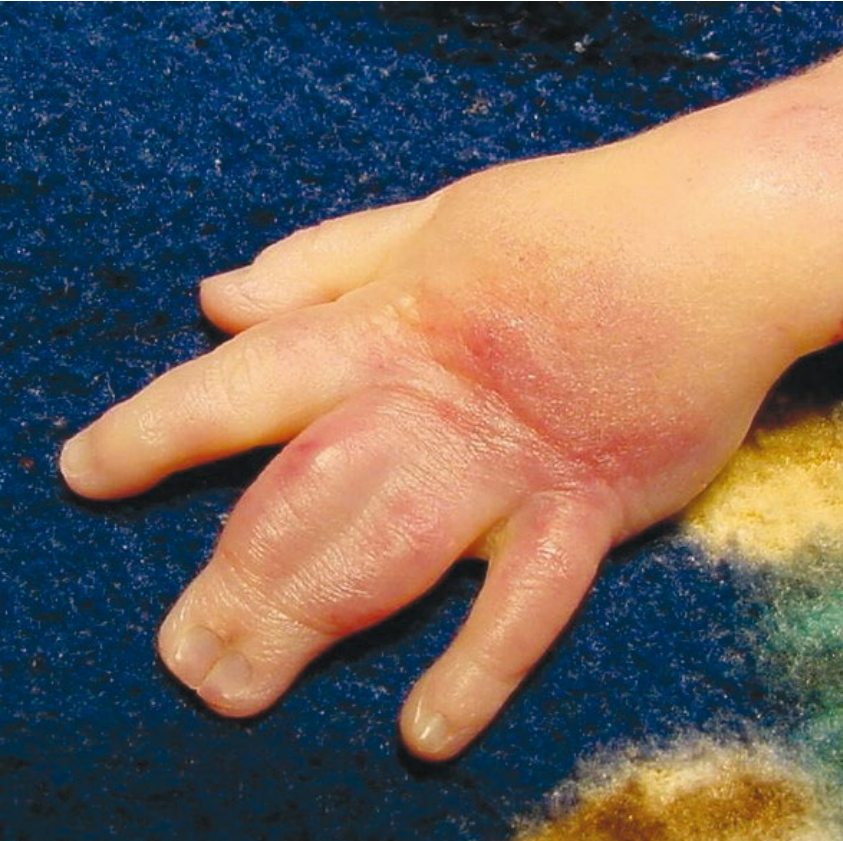

Fig. 2

Complete 3/4 syndactyly of the fingers.

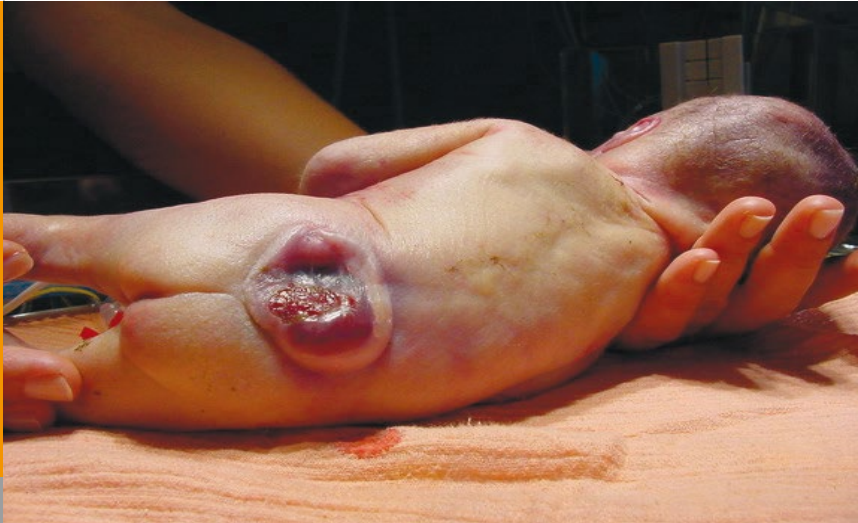

Fig. 3

Lumbar myelomeningocele.

CASE REPORT 2

This male infant was born to a 25-year-old G1/P1 at 32 3/7 weeks of gestation by C-section following PROM, meconium-stained amniotic fluid and non-reassuring fetal heart rate tracing. Earlier, fetal ultrasound had revealed a myelomeningocele and a CNS abnormality which was felt to be consistent with hydrocephalus. Also, the placenta was noted to be very large (713 g). Apgar scores were 5, 6, and 8 at 1, 5, and 10 minutes respectively. An umbilical venous catheter was placed and the infant was transferred on nasal CPAP to the neonatal intensive care unit.

The boy weighed 1700 g (P25), his length was 38 cm (P<3) and his head circumference was 32 cm (P75). Clinical examination and further investigations revealed the following abnormal findings: large posterior fontanel, low nasal bridge, hypertelorism, micrognathia, low-set malformed ears (Fig. 4, 5), iris colobomata (Fig. 6), bilateral simian creases and clinodactyly (Fig. 5, 7), cryptorchidism, micropenis with hypospadias, bilateral talipes equinovarus (Fig. 8), bilateral 3/4 syndactyly of the toes (Fig. 9), and lumbosacral myelomeningocele (Fig. 10). A head ultrasound showed alobar holoprosencephaly with cerebellar hypo- or aplasia (Fig. 11, 12). Echocardiography was remarkable for severe persistent pulmonary hypertension. These findings were felt to be consistent with triploidy syndrome. After discussion with the parents, life-sustaining therapies were discontinued and comfort therapy was provided. There were progressively more prolonged periods of apnea and the infant died at the age of 15 hours. Chromosomal analysis from a fibroblast culture confirmed the diagnosis of triploidy syndrome (Fig. 13).

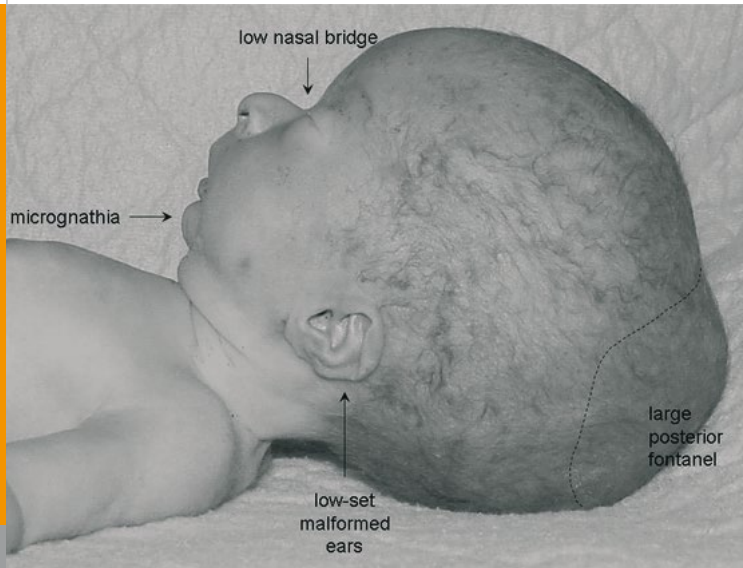


Fig. 4

Large posterior fontanel, low nasal bridge, micrognathia, low-set ears.

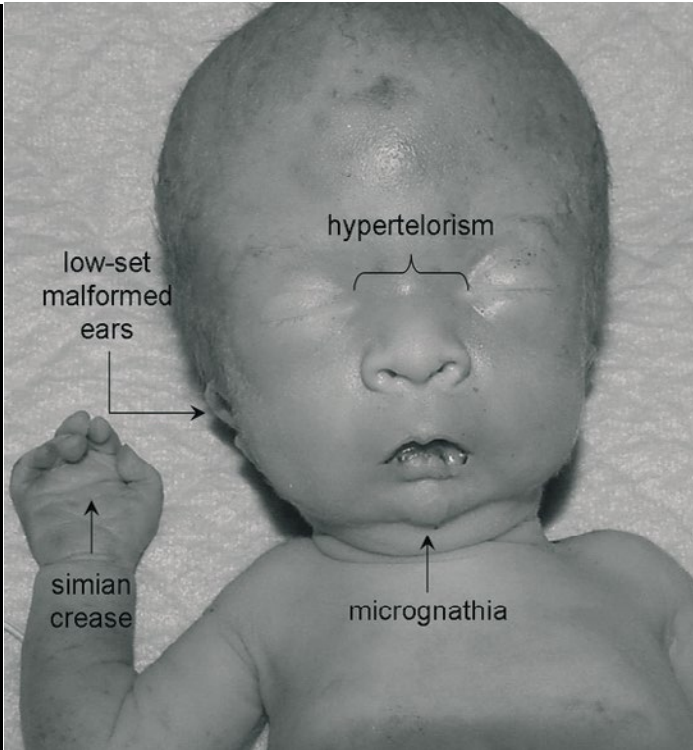


Fig. 5

Hypertelorism, low-set ears, micrognathia, simian crease.

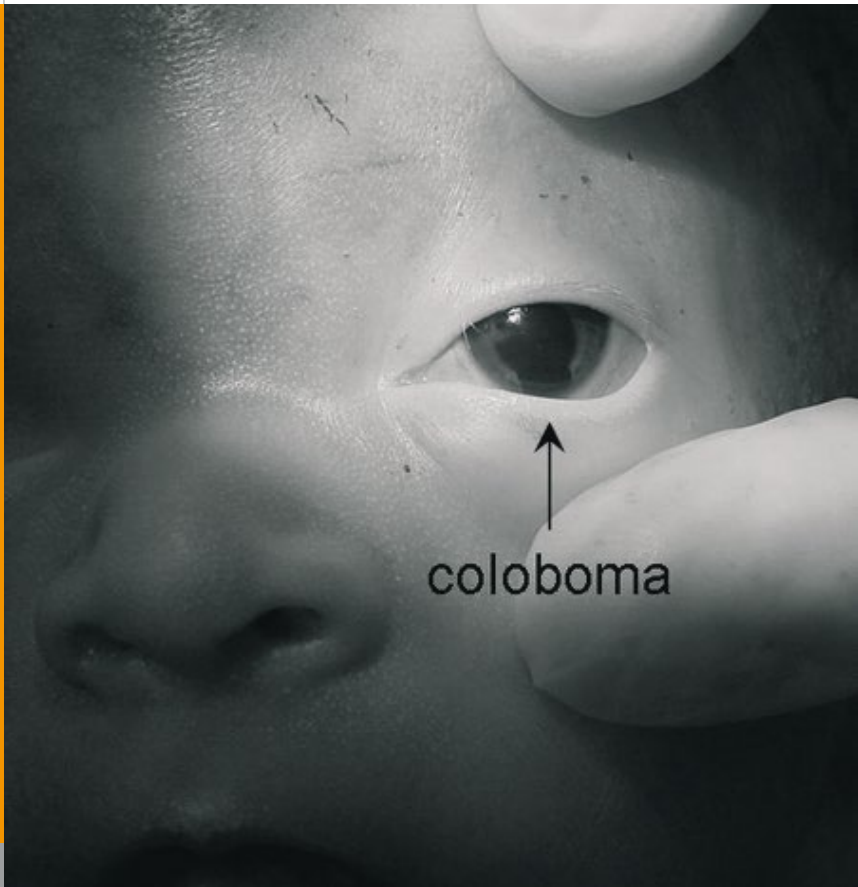


Fig. 6

Iris coloboma.

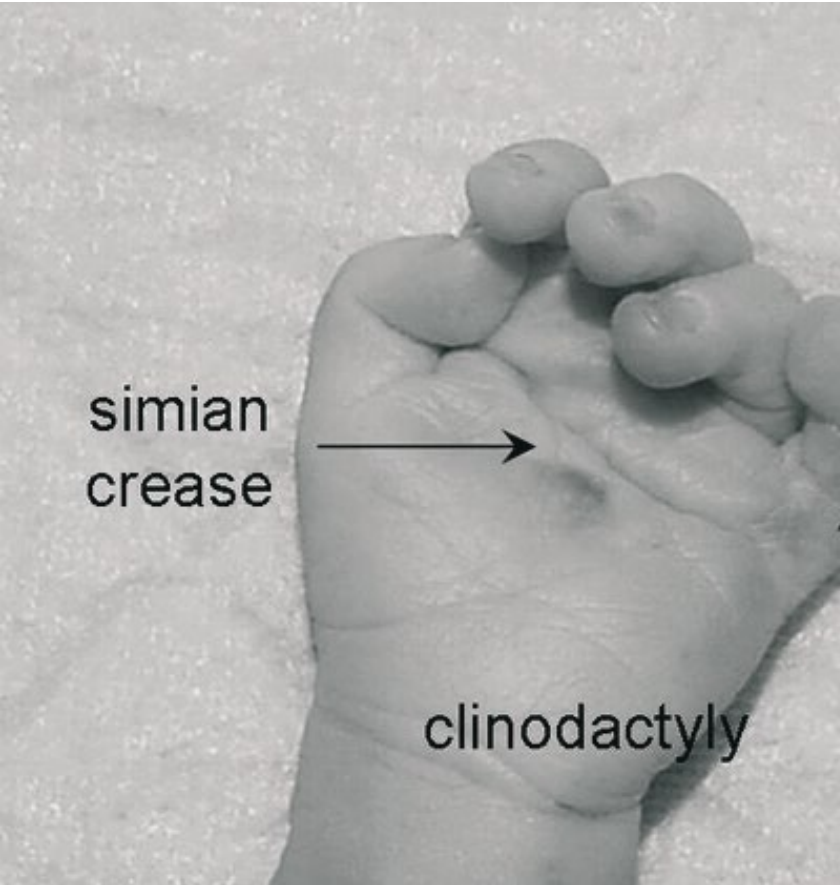


Fig. 7

Simian crease, clinodactyly.

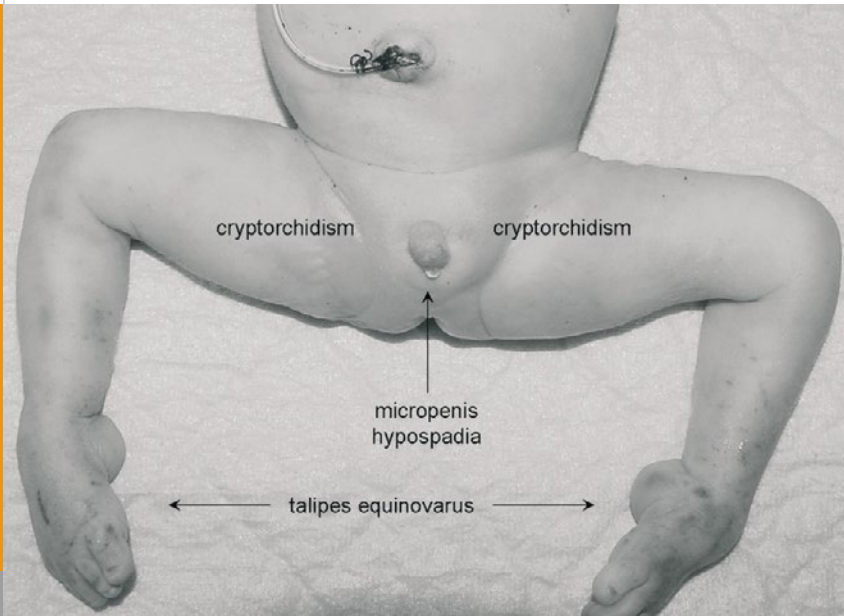
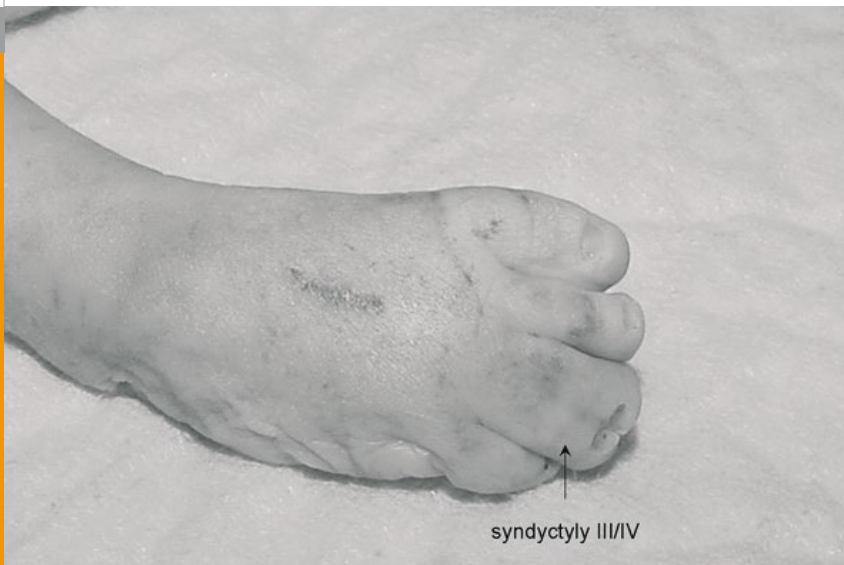

Fig. 8

Cryptorchidism, micropenis with hypospadias, bilateral talipes equinovarus.

3/4 syndactyly of the toes.

Fig. 9



syndactyly III/IV

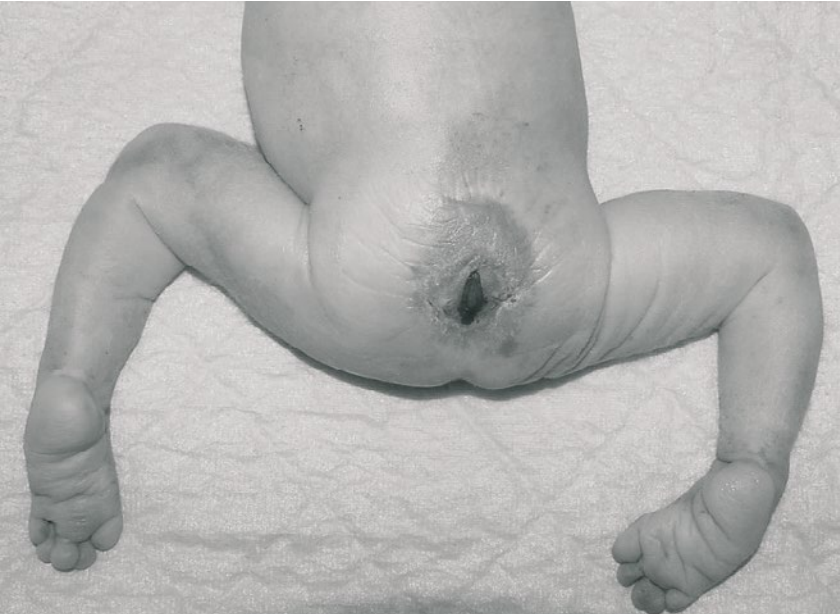

Fig. 10

Lumbosacral myelomeningocele.

Head ultrasound: coronal views demonstrating alobar holoprosencephaly.

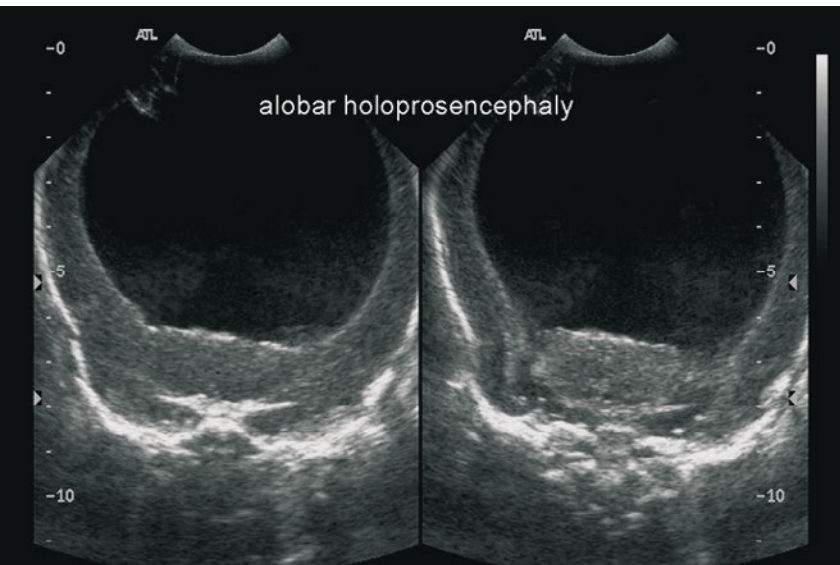


Fig. 11

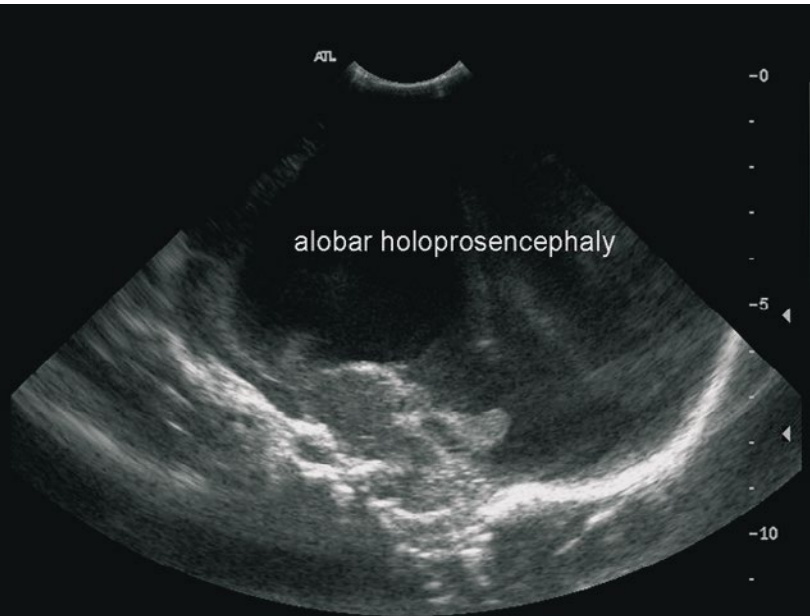
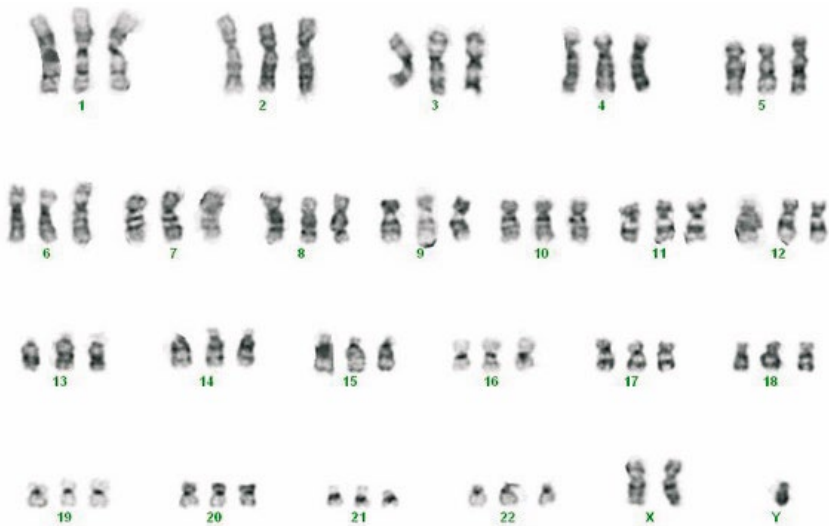


Fig. 12

Head ultrasound: sagittal view.

*Chromosomal analysis from fibroblast culture:
69, XXY.*

Fig. 13



Triploidy is the most frequent chromosome aberration in first trimester abortions (1). It is estimated to occur in approximately 2% of conceptuses (2). Placentas are large and show areas of hydatiform degeneration without trophoblast hyperplasia if the diploid set is of paternal origin (1). This is consistent with the placental morphology in our patient 1 (female); unfortunately, apart from its weight, no further details of the placenta in patient 2 (male) were available. Maternal triploidy (diploid set of maternal origin) is usually associated with a fetus with growth restriction and a small non-cystic placenta.

According to Jones (2) disproportionate prenatal growth deficiency, dysplastic calvaria with large posterior fontanel, ocular hypertelorism with eye defects (including colobomata as in our patients), low-set malformed ears, low nasal bridge, micrognathia, syndactyly of third and fourth fingers, simian crease, talipes equinovares, congenital heart defects, micropenis, hypospadias, cryptorchidism, and brain anomalies (including hydrocephalus and holoprosencephaly) occur in 50% or more of the cases. Our patients showed all of these features except for congenital heart disease. Myelomeningoceles (seen in both of our patients) occur in less than 50% of patients with triploidy syndrome. Most cases of triploidy syndrome described in the literature have either been stillborn or have died in the early neonatal period. The longest recorded survival is 10 months (3).

The two most common mechanisms of origin are attributable to maternal factors: first, dispermy or double fertilization due to failure of the zone reaction (which normally prevents polyspermy), and, second, a failure of meiosis I or II leading to a diploid egg (4). There is no data indicating an increased recurrence risk (2).

REFERENCES

1. Schinzel A. A catalogue of unbalanced chromosomal aberrations in man. Walter de Gruyter (Berlin, New York), 2nd edition (2001)
2. Jones KL. Smith's recognizable patterns of human malformation. Elsevier Saunders, 6th edition (2006)
3. Sherard J, Bean C, Bove B, Del Duca V, Esterly KL, Karcsh HJ, Munshi G, Reamer JF, Suazo G, Wilmoth D, et al. Long survival in a 69, XXY triploid male. *Am J Med Genet* 1986;25:307-312
4. Baumer A, Balmer D, Binkert F, Schinzel A. Paternal origin and mechanisms of formation of triploidy: a study of 25 Cases. *Eur J Hum Genet* 2000;8:911-917

SUPPORTED BY



CONTACT

Swiss Society of Neonatology
www.neonet.ch
webmaster@neonet.ch