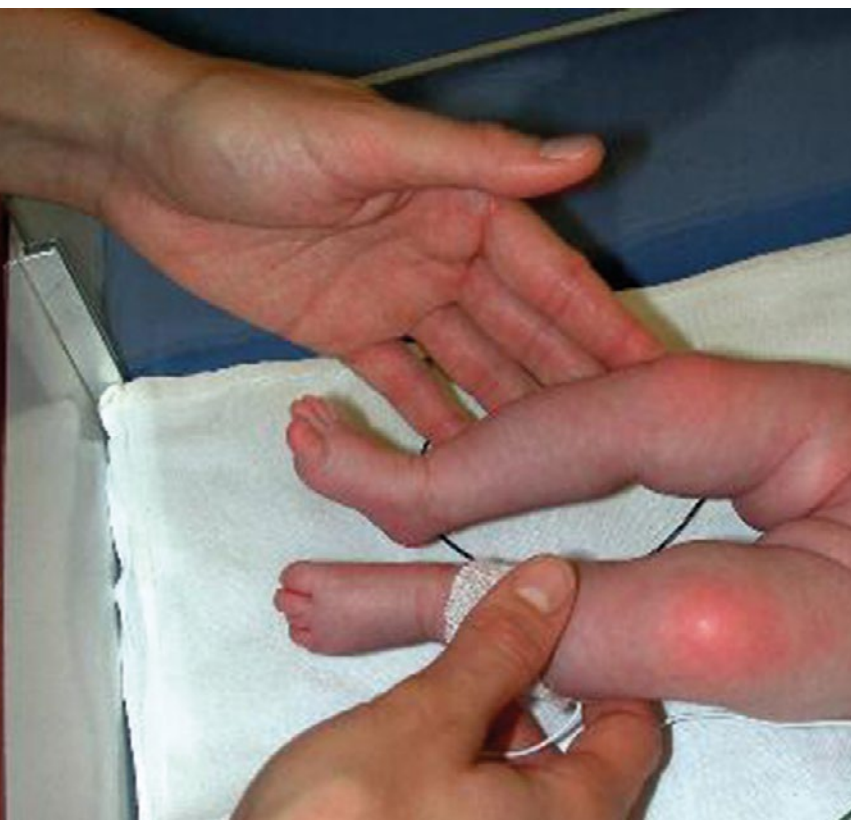

SWISS SOCIETY OF NEONATOLOGY

A newborn girl with suspected Silver-Russell syndrome

June 2003



We present the case of a girl with suspected Silver-Russell syndrome (SRS). SRS is a rare, clinically and genetically heterogeneous disorder involving intrauterine and postnatal growth retardation with a wide spectrum of additional dysmorphic features. Because of the clinical heterogeneity, diagnosis can be rather subjective and is not always easy to confirm.

The girl, third child of a 30-year-old mother, was born prematurely at 31 6/7 weeks of gestation by Cesarean section because of a pathologic CTG. Intrauterine growth retardation had been diagnosed at 26 6/7 weeks of gestation. At that time, amniocentesis and TORCH serologies were performed with inconspicuous results.

After delivery, the girl was cyanotic, bradycardic with no spontaneous respiration. Bag and mask ventilation was needed during the first minute of life. Apgar scores were 3, 9 and 8 at 1, 5 and 10 minutes, respectively. Birth weight was 980 g ($P < 3$), length 32.5 cm ($P < 3$) and head circumference 29.5 cm (P_{25-50}). Besides a disproportionately large appearing head and a high forehead, downturned corners of the mouth (Fig. 1) and an asymmetry of the limbs (Fig. 2) were striking. Postnatal growth was poor (Fig. 3 and 4).

Because of these clinical findings the diagnosis of SRS was suspected and a molecular analysis was initiated,

but showed no abnormalities. The suspected diagnosis of SRS in our case therefore remained based solely on clinical criteria and could not be confirmed genetically.

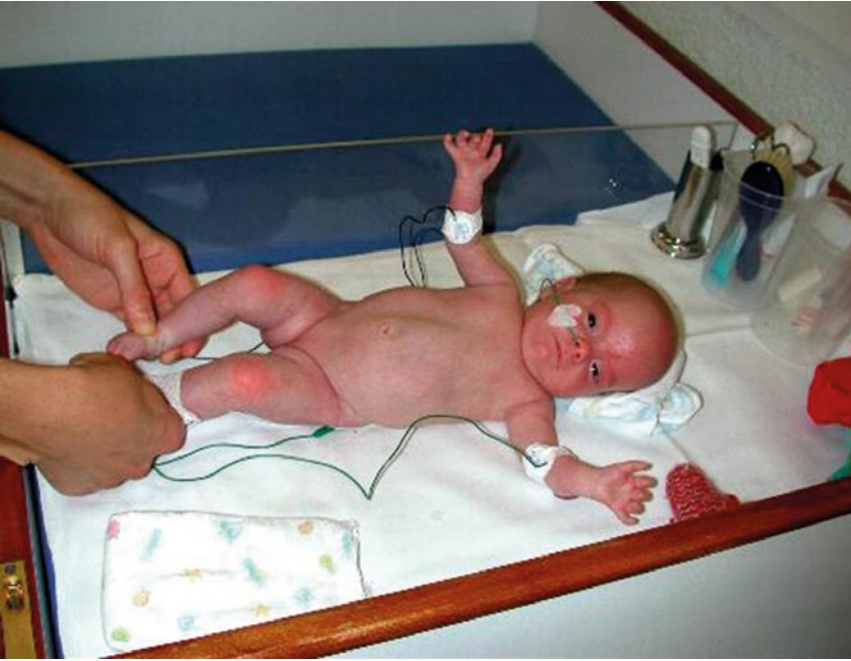

Fig. 1

Large appearing head, high forehead, downturning corners of the mouth.

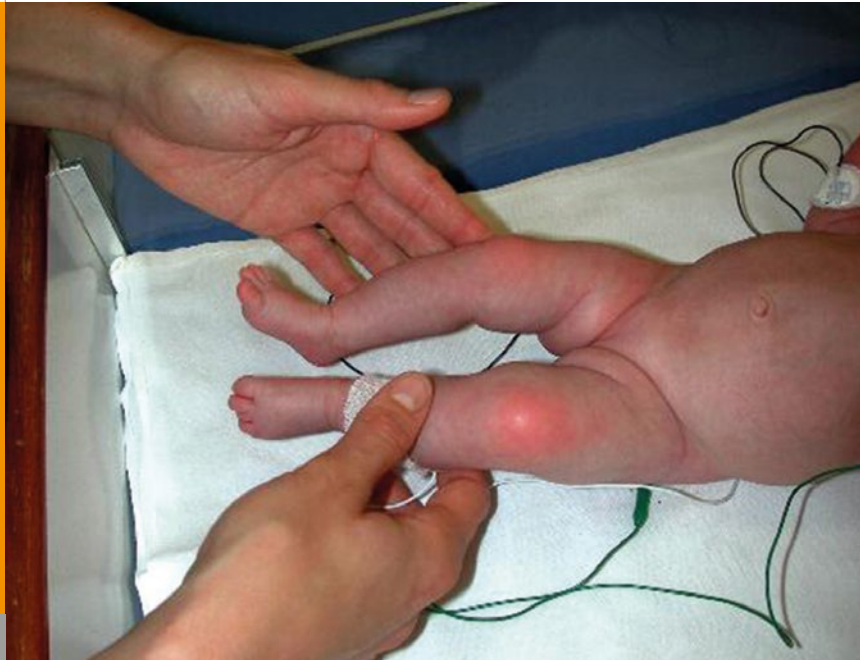

Fig. 2

Asymmetry of the legs.

Perzentilkurven für Körpermaße bei Geburt

Deutsche Neugeborene, 23 bis 43 Schwangerschaftswochen

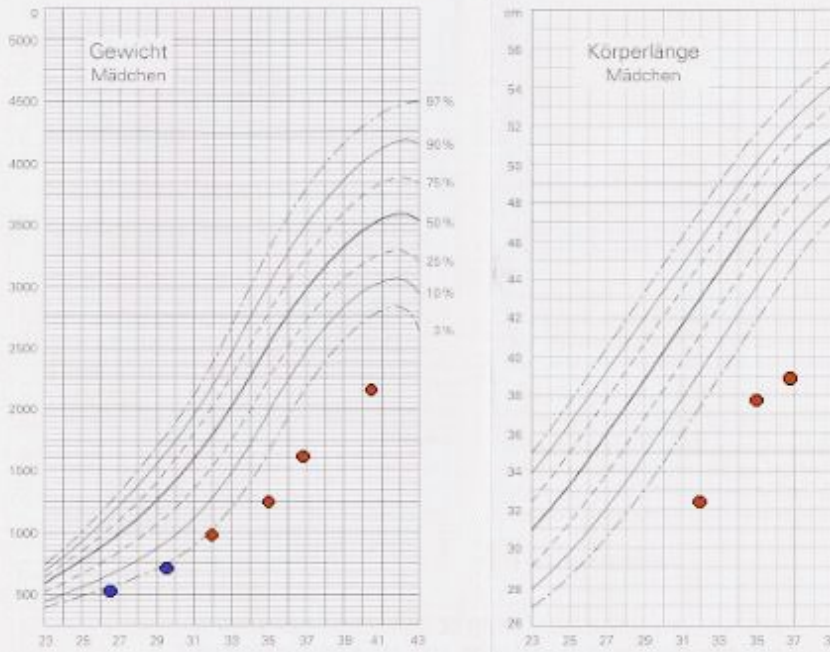


Fig. 3

Weight and height (blue: prenatal, red: postnatal measurements).

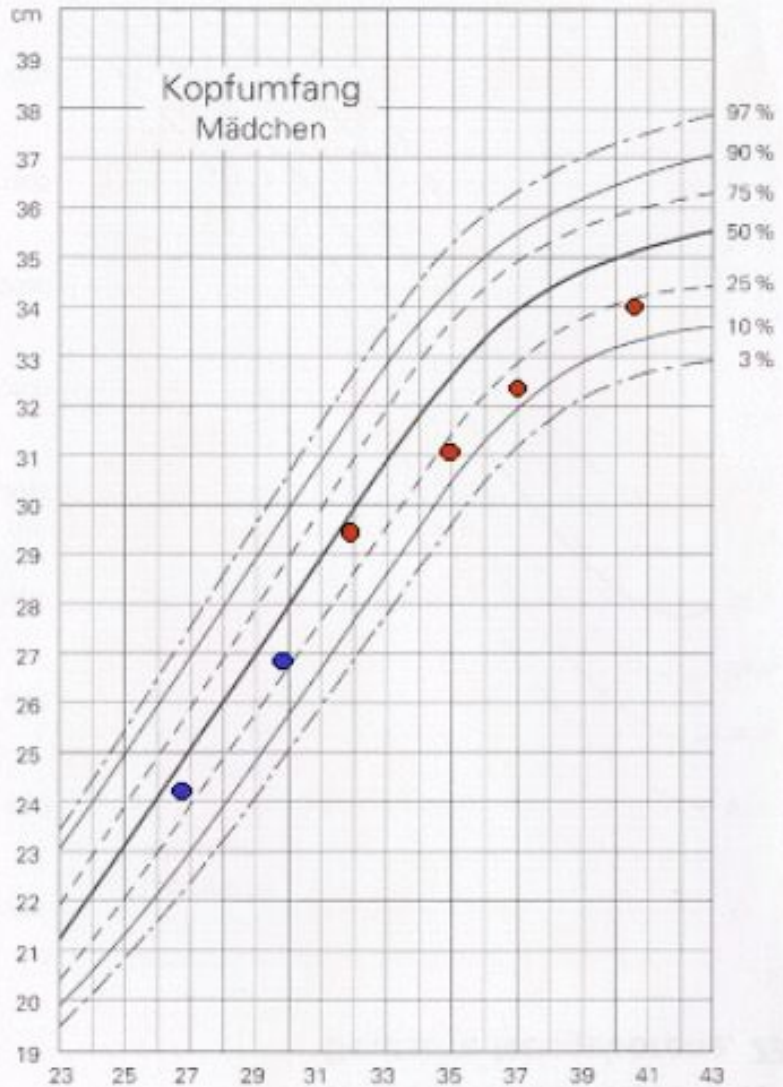


Fig. 4

Head circumference (blue: prenatal, red: postnatal measurements).

Silver-Russell syndrome (SRS) was originally described by Silver and colleagues in 1953 (1) and little later by Russell in 1954 (2). They described children with characteristic facies, low birthweight, body asymmetry and growth retardation. Today, SRS is seen as a clinically and genetically heterogeneous disorder involving intrauterine and postnatal growth retardation with a wide spectrum of additional dysmorphic features (3).

Because the syndrome is not only clinically but also genetically heterogeneous (4), diagnosis is not always easy to confirm. Only about 10% of affected individuals have maternal uniparental disomy (UPD) of chromosome 7 (inheriting 2 copies of maternal chromosome 7, with no paternal contribution) (5), a defect which may be documented by molecular analysis. If no UPD can be found, like in our case, the diagnosis remains based solely on clinical criteria. In 1999 Price proposed such diagnostic criteria for SRS (6):

1. Birth weight more or equal to 2 SD below the mean
2. Poor postnatal growth more or equal to 2 SD below the mean at diagnosis
3. Preservation of occipitofrontal head circumference
4. Classic facial phenotype (small triangular face)
5. Asymmetry (especially of the limbs)

Growth failure is the primary abnormality (7). Infants present with intrauterine growth retardation, feeding difficulty, failure to thrive, excessive sweating, a

tendency towards fasting hypoglycemia or postnatal growth retardation. Older children and adults do not manifest clinical features as clearly as infants or young children. Intelligence may be normal or there may be learning disabilities (8).

Although growth hormone (GH) levels usually are normal in affected individuals, children with SRS exhibit abnormalities of pulsatile growth hormone secretion and GH treatment may have a positive effect on the growth pattern (9). Long-term studies have not yet been performed on a large number of patients. The eventual outcome and possible adverse effects of GH treatment therefore have to be further investigated before GH therapy can be introduced as standard treatment in SRS.

1. Silver HK, Kiyasu W, George J. Syndrome of congenital hemihypertrophy, shortness of stature and elevated urinary gonadotropins. *Pediatrics* 1953;12:368-375
2. Russell A. A syndrome of „intrauterine dwarfism“ recognisable at birth with craniofacial dysostosis, disproportionately short arms and other abnormalities (5 examples). *Proc Royal Soc Med* 1954;47:1040-1044
3. Preece MA. The Genetics of the Silver-Russell Syndrome. *Rev Endocr Metab Disord* 2002;3:369–379
4. Wakeling EL, Abu-Amero S, Price SM, et al. Genetics of Silver-Russell syndrome. *Horm Res* 1998;49:32-36 (*Abstract*)
5. Monk D, Bentley L, Hitchins M, et al. Chromosome 7p disruptions in Silver Russell syndrome: delineating an imprinted candidate gene region. *Hum Genet* 2002;111:376-387 (*Abstract*)
6. Price SM, Stanhope R, Garrett C, et al. The spectrum of Silver-Russell syndrome: a clinical and molecular genetic study and new diagnostic criteria. *J Med Genet* 1999;36:837-842 (*Abstract*)
7. Wollmann HA, Kirchner T, Enders H, et al: Growth and symptoms in Silver-Russell syndrome: review on the basis of 386 patients. *Eur J Pediatr* 1995 Dec;154:958-968 (*Abstract*)
8. Jones KL. Russell-Silver syndrome. In: *Smith’s Recognizable Patterns of Human Malformation*. 5th Edition (1997) pp 96-9. W.B. Saunders, Philadelphia.
9. Rakover Y, Dietsch S, Ambler GR. Growth hormone therapy in Silver Russell syndrome: 5 years experience of the Australian and New Zealand Growth database (OZGROW). *Eur J Pediatr* 1996;155:851-857 (*Abstract*)

SUPPORTED BY



CONTACT

Swiss Society of Neonatology

www.neonet.ch

webmaster@neonet.ch