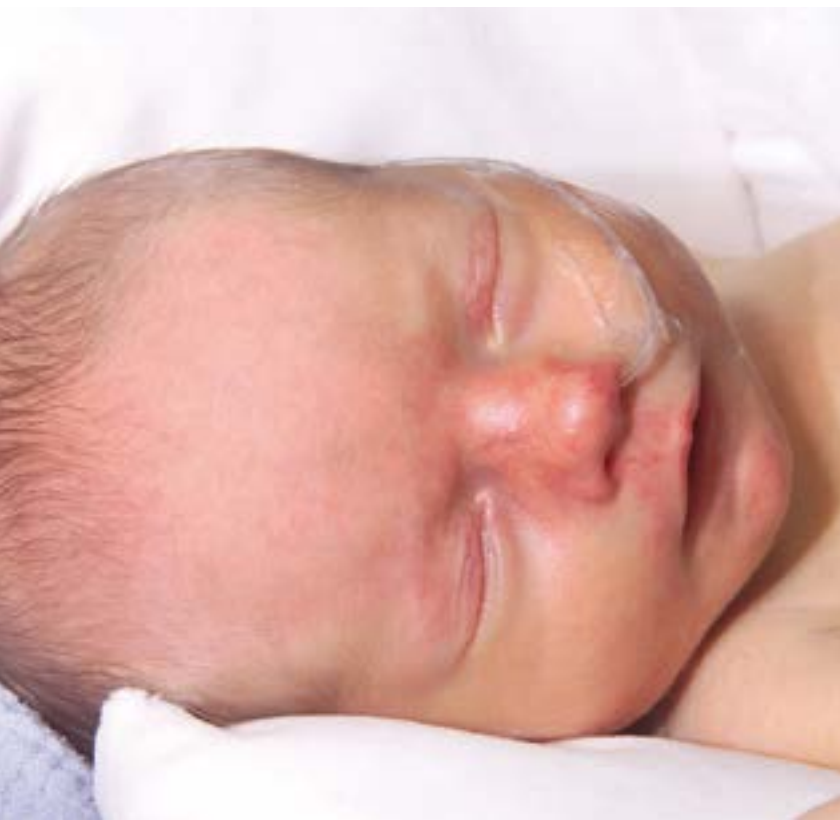

Facial segmental
hemangioma in a girl –
the tip of the iceberg

October 2008



Geissberger R, Luhmann Lunt C, Roth K, Itin P, Briner J, Hauser P, Capone Mori A, Eich G, Pasquier S, Zeilinger G, Department of Pediatrics (GR, LLC, CMA, PS, ZG) and Department of Pediatric Surgery (RK), Children's Hospital of Aarau, Department of Dermatology (IP), University Hospital of Basel, Institute of Histology and Cytology (BJ), Aarau, Department of Diagnostic and Interventional Radiology, University Hospital Lausanne (HP), Department of Radiology (EG), Kantonsspital Aarau

This female infant was the first child born to a 28-year-old mother at 36 6/7 weeks of gestation. Postnatal adaptation was normal and growth measures were within normal limits. Both parents originated from the same small village in southern Kosovo and were probably distantly related. On the fourth day of life, recurring clonic seizures of the left arm and leg were noticed and the baby was referred to our hospital for further evaluation.

On clinical examination, a large plaque-like hemangioma in the mid-line of the face was found, spreading more to the right than to the left side. It was initially subtle (Fig. 1), but within weeks became more prominent with bright red coloring and raised bluish patches (Fig. 2). Ophthalmologic examination revealed dilatation of the blood vessels of the iris, dysplasia of the chamber angle and a small tumor in the iris of the right eye. There was no evidence of increased intraocular pressure. An MRI scan of the head revealed a defect of the right frontal lobe with both pachy- and microgyria. There were associated signs of atrophy with dilatation of the anterior horn of the lateral right ventricle (Fig. 3 A, B). Previously, calcifications of the subcortical white matter of the right frontal lobe were seen on a CT scan of the head on the fifth day of life (Fig. 4). An EEG showed localized slow activity in the right fronto-parietal region with apparent epileptic discharges. The seizures were controlled with phenobarbital. The patient was discharged home at the age of two weeks.

At four weeks of age, the infant presented with failure to thrive and weight loss. On physical examination, she appeared septic and had signs of subileus. Dilated small bowel and a subtle linear calcification in the mid-abdomen were seen on conventional ex-ray (Fig. 5). Because of persistence of these symptoms despite conservative therapy laparotomy was performed at the age of six weeks. The abdomen was laced with thick adhesions. There was a jejunal and ileal perforation. Additionally, intestinal malrotation and an annular pancreas were noted. Adhesions were divided and resection of the perforated parts of the jejunum and ileum was performed. The histology of the resected parts showed intestinal angiomatosis with ulcers and peritonitis. The postoperative course was complicated by difficulties in advancing enteral feedings and recurrent nosocomial infections. The child was discharged at the age of six months.

The cutaneous hemangiomas continued to proliferate and were treated with both topical and oral corticosteroids. Fig. 6 shows the patient at the age of one year. After oral corticosteroid therapy was stopped at the age of 17 months, stridor developed. A CT scan showed subglottic tracheal and mediastinal hemangiomas. Tracheal endoscopy confirmed the finding of subglottic hemangiomas causing narrowing of the trachea (Fig. 7). Laser therapy led to prompt and complete relief of stridor.

At the age of 2 years, an MRI scan of the head was performed. It showed subcutaneous, parotid and parapharyngeal hemangiomas.

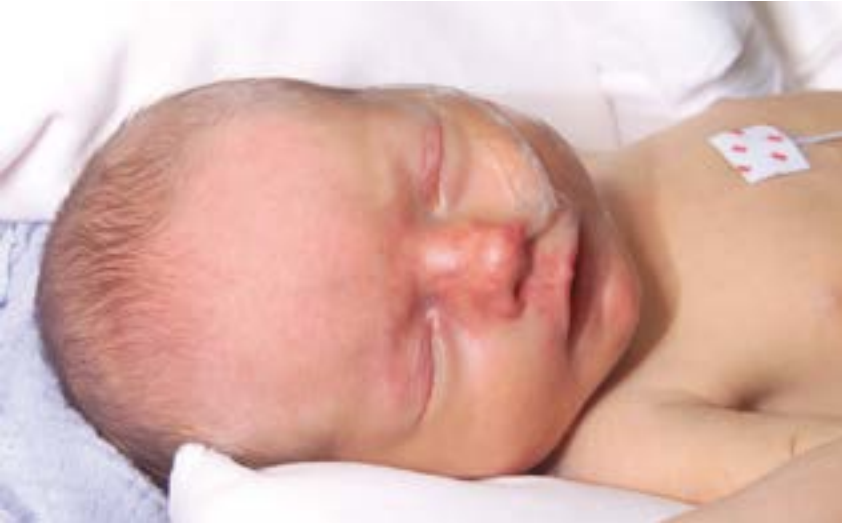

Fig. 1

Patient at the age of 1 week.

Patient at the age of 2 months.

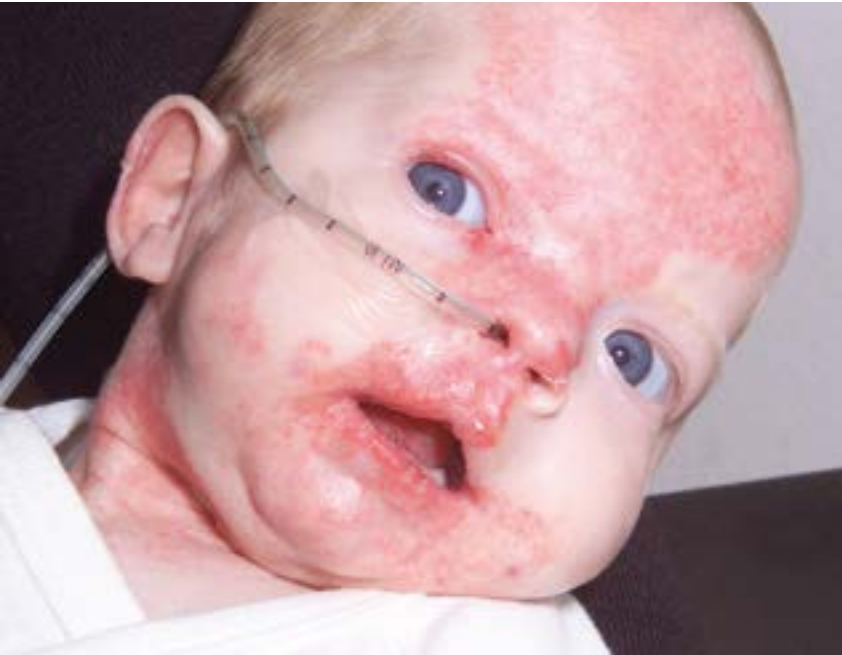

Fig. 2

ryngeal extension of the right facial hemangioma (Fig. 8) as well as absence of the right anterior cerebral artery and persistence of a right trigeminal artery (Fig. 9).

DISCUSSION

Hemangiomas of infancy are the most common benign tumors in childhood (1). Capillary hemangiomas classically undergo an initial phase of proliferation, followed by slow involution. They show a striking predilection for the head and neck region. Large, plaque-like hemangiomas have a higher risk of associated pathologies than the more frequent, localized, tumor-like lesions, which usually occur as an isolated finding (2, 3). Based on a proposed segmental map for facial hemangiomas (3), the hemangioma in our patient involves segment 1 (supra-orbital), 3 (mandibular and ear) and 4 (midline) and is therefore a mixed type segmental hemangioma. The few bluish tumors within the area of the hemangioma suggest subcutaneous involvement at these sites (Fig. 6).

The initial appearance of a hemangioma can be mistaken for a capillary malformation presenting as port-wine-stain and consecutively be misdiagnosed as Sturge-Weber-syndrome which is characterized by leptomeningeal vascular malformation and glaucoma (4).

In 1978, Pascual-Castroviejo described seven female patients with facial or scalp hemangiomas, which were associated with both vascular and nonvascular intracranial malformations. Some patients had congenital

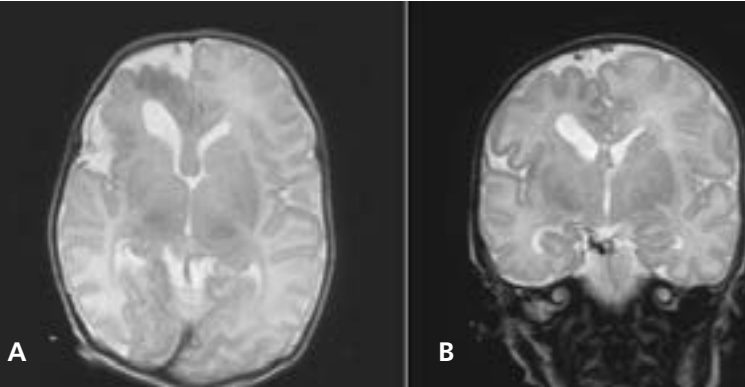


Fig. 3

T2-weighted MRI-scan of the head at the age of 10 days showing pachy- and microgyria of the right frontal lobe and widening of the CSF spaces (A) axial and B) coronal view).

CT scan at the age of 5 days showing subcortical calcifications of the right frontal lobe (horizontal view).

Fig. 4

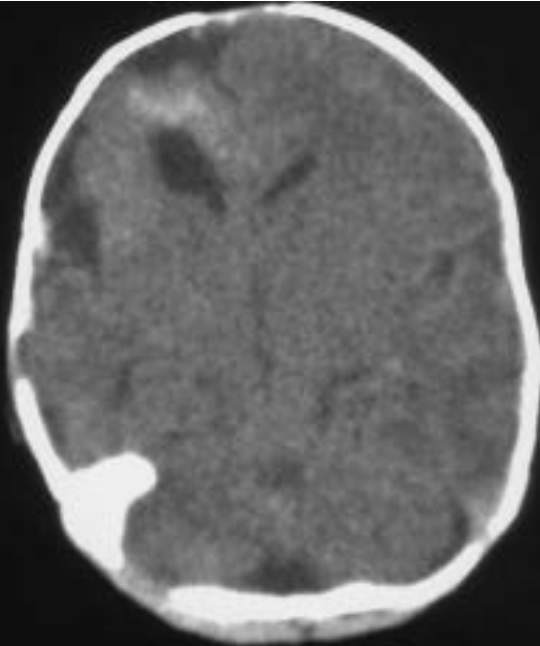

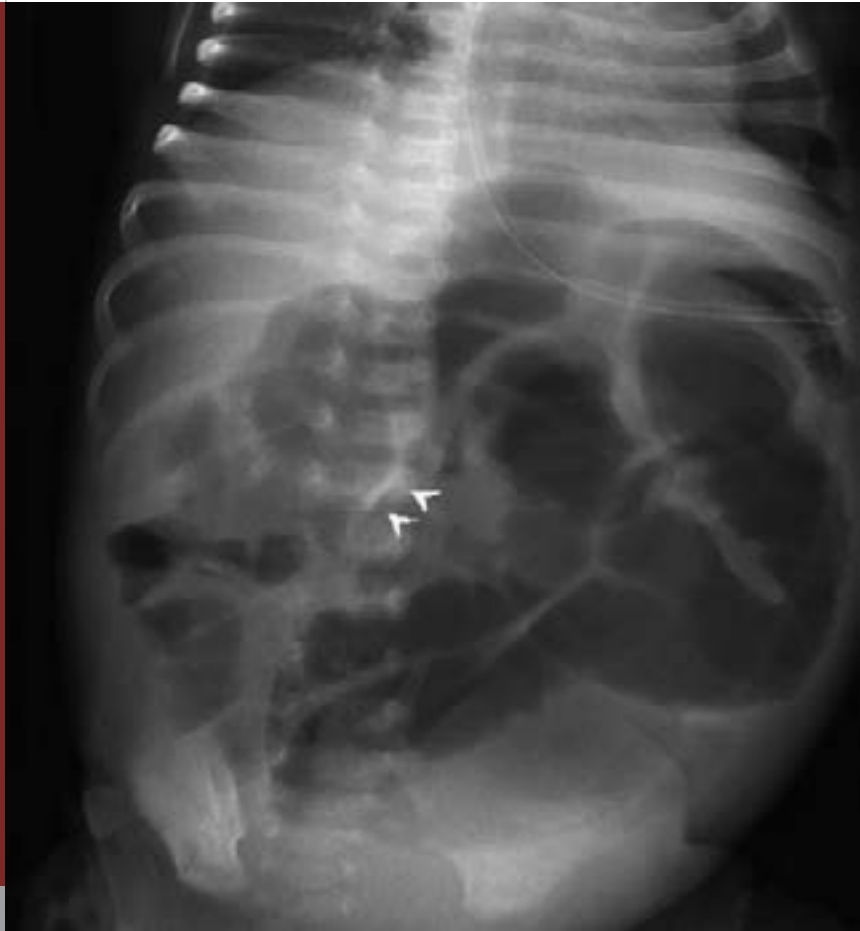


Fig. 5

Abdominal X-ray at the age of 4 weeks showing dilated small bowel and a single linear intestinal calcification (arrow heads).

heart disease or additional brain malformations most frequently involving the cerebellum (5). In 1996, he presented 17 additional cases, among them two with supratentorial unilateral cerebral defects and one with an intraabdominal hemangioma. He suggested the name "cutaneous hemangioma – vascular complex syndrome" for this newly described neurocutaneous syndrome, that he later renamed "Pascual Castroviejo Type II syndrome" (6, 9). In the same year, Frieden presented 2 new cases and reviewed 41 previously published cases. She proposed the acronym PHACE for this syndrome, consisting of the following major features: Posterior fossa malformations, Hemangiomas, Arterial anomalies, Coarctation of the aorta and cardiac defects, and Eye abnormalities. If ventral developmental defects such as sternal clefting and/or supraumbilical raphe are included, the acronym is changed to PHACES (4). Obviously, the terms "cutaneous hemangioma – vascular complex syndrome", "Pascual-Castroviejo Type II syndrome" and "PHACE(S)" association describe very similar syndromes.

PHACE association is defined as a cutaneous hemangioma of the face and at least one of the major features of the acronym PHACE. Pascual-Castroviejo Type II syndrome has a broader clinical spectrum. It is characterized by cutaneous hemangioma or vascular malformation associated with internal vascular or non-vascular anomalies (7). PHACE seems now to be the more popular name and is the only one mentioned in the OMIM-Database as PHACE association (606519).

In 2001, Metry et al. presented 14 new cases of PHACE association and found 116 additional cases described in the literature. Based on this data, she suggested that PHACE represented a spectrum of anomalies, with 70% of the affected children presenting only one extracutaneous manifestation of the syndrome (8). Later, she emphasized the potential association of solitary segmental hemangiomas of the skin with visceral hemangiomatosis (2). Metry established a PHACE registry in 2006 (www.texaschildrenshospital.org).

No familial cases of PHACE have been reported (4). A female predominance has been postulated (9-11). The etiology of this neurocutaneous syndrome is unknown. X-linked inheritance with fatal outcome in males has been proposed to explain the marked female predominance (3). Pascual-Castroviejo hypothesized that the anomalies develop between the 7th and 8th week of gestation based on the ontogeny of the cerebral vasculature (11). Metry suggested, that the constellation of anomalies best represented a "developmental field defect" as proposed by Opitz et al., whereby an insult at a critical time in embryogenesis gives rise to corresponding developmental outcomes (3).

In our patient, intestinal hemangiomas lead to perforations and sepsis. The abdominal calcifications seen on X-ray at four weeks of age suggest intrauterine perforation. The association of segmental hemangiomas of the skin and intestinal angiomatosis varies between 7.5%

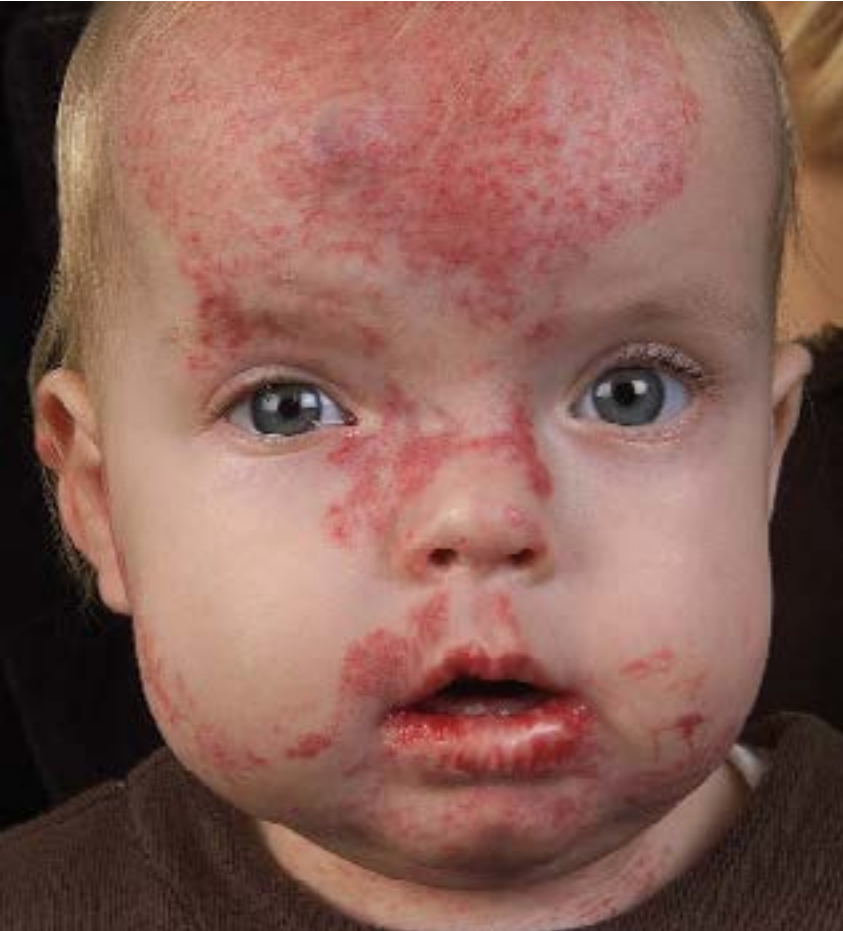
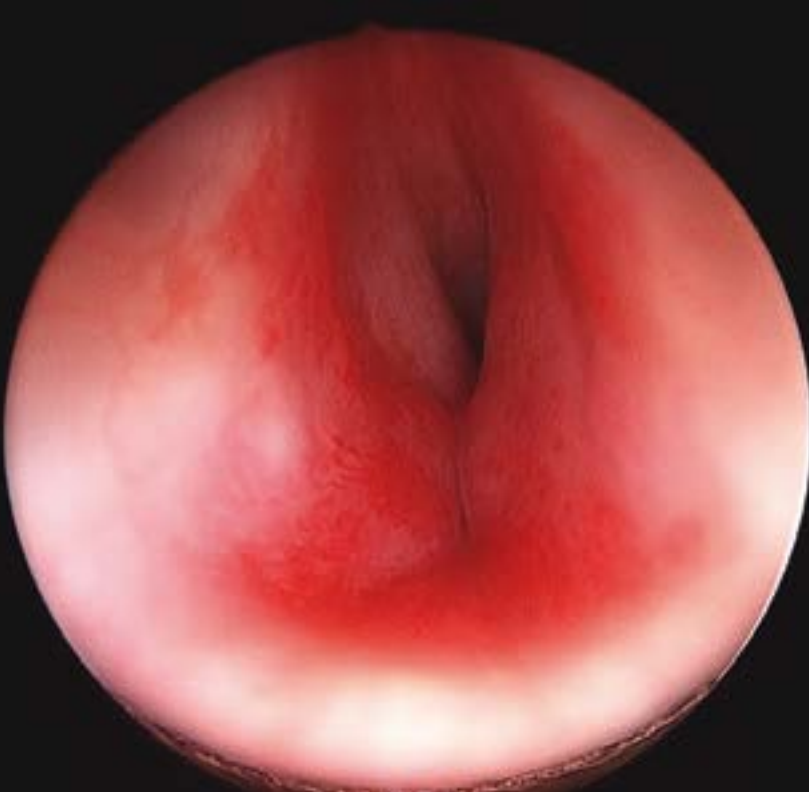
Fig. 6

Patient at the age of 1 year.

and 34% in selected patient groups (2, 10). Visceral angiomas is a major factor contributing to fatality in infancy (2). Intestinal hemangiomas, like other hemangiomas, seem to have a spontaneous tendency to disappear during the first years of life (10). The incidence of mediastinal angiomas including tracheal hemangiomas in patients with visceral angiomas is reported to be 19% (2).

Our patient shows a defect of the right frontal lobe with pachy-, microgyria and calcification ipsilateral to the hemangioma. While the most frequent structural CNS defects in PHACE association are cerebellar anomalies, there are only few reports of supratentorial defects like cortical hypoplasia or dysplasia (6, 10-14). All of them show abnormalities of cerebral arteries, which is a typical finding in patients with PHACE association. This was also confirmed in our patient by cerebral MR angiography at the age of two years which revealed a missing right anterior cerebral artery and persistence of a right trigeminal artery. Supratentorial cerebral defects may represent a new aspect of the PHACE spectrum (12). The etiology of cerebral defects is unclear. They may be an expression of ischemic events during brain development or of a possible dysfunction of neural crest cells that could result in vascular facial and cerebral abnormalities and cortical maldevelopment (11). Neurological sequelae seem to be common (about 90%) in patients with structural or arterial brain anomalies (2). The majority of patients present with seizures in infancy or developmental delay.

**Fig. 7**

Laryngeal and tracheal endoscopy at the age of 19 months showing tracheal narrowing caused by a subglottic hemangioma.

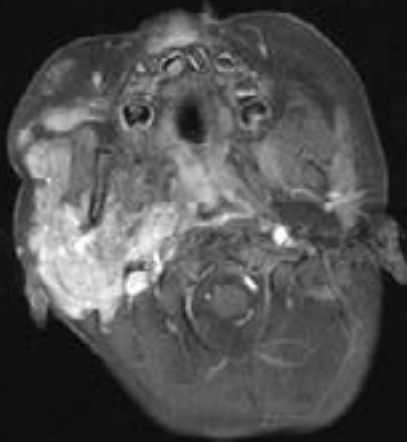


Fig. 8

MRI at the age of 2 years showing subcutaneous, parotid and parapharyngeal extension of the right facial hemangioma, horizontal section.

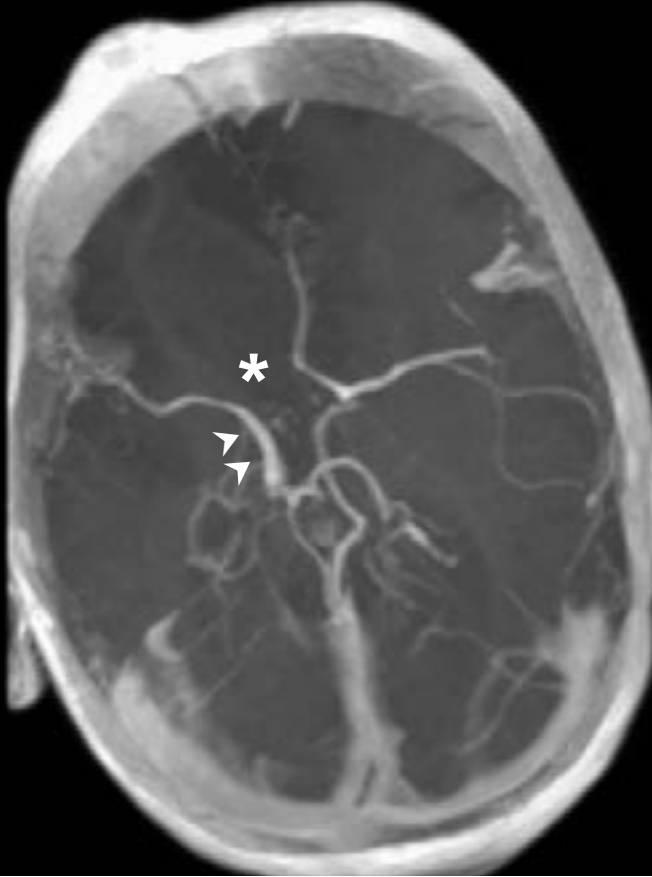

Fig. 9

Maximum intensity projection of an MRI angiogram of the head at the age of 2 years: note absence of the right anterior cerebral artery (asterisk) and persistence of a right trigeminal artery (arrow heads).

The eye abnormalities found in our patient are not typical ocular features found in PHACE syndrome like microphthalmia, optic nerve hypoplasia, cataracts or increased retinal vascularity.

In summary, our patient shows features consistent with PHACE or Pascual-Castroviejo Type II syndrome. The association of hemangioma of the face and one of the following features has been described in a small number of patients: cerebral defect with vascular anomaly, intestinal angiomatosis or tracheal/mediastinal hemangioma. But we found no previous report of the association of facial hemangioma and all three features combined as found in our patient.

CONCLUSION

In children presenting with a large, plaque-like facial hemangioma, a PHACE or Pascual-Castroviejo Type II syndrome should be considered. Children at risk should have careful neurologic, ophthalmic and cardiac evaluation. Visceral hemangiomas can cause serious or even fatal complications. If stridor occurs, a tracheal hemangioma should be considered. Systemic steroid therapy may be necessary to limit growth of the hemangioma.

1. Wenk C, Itin PH. Epidemiology of pediatric dermatology and allergology in the region of Aargau, Switzerland. *Pediatr Dermatol* 2003;20:482-487
2. Metry DW, Hawrot A, Altman C, Frieden IJ. Association of solitary, segmental hemangiomas of the skin with visceral hemangiomatosis. *Arch Dermatol* 2004;140:591-596
3. Metry DW, Haggstrom AN, Drolet BA, Baselga E, Chamlin S, Garzon M, Horii K, Lucky A, Mancini AJ, Newell B, Nopper A, Heyer G, Frieden IJ. A prospective study of PHACE syndrome in infantile hemangiomas: demographic features, clinical findings and complications. *Am J Med Genet A* 2006;140:975-986
4. Frieden IJ, Reese V, Cohen D. PHACE syndrome. The association of posterior fossa brain malformation, hemangiomas, arterial anomalies, coarctation of the aorta and cardiac defects, and eye abnormalities. *Arch Dermatol* 1996;132:307-311
5. Pascual-Castroviejo I. Vascular and nonvascular intracranial malformation associated with external capillary hemangiomas. *Neuroradiology* 1978;16:82-84
6. Pascual-Castroviejo I, Viano J, Moreno F, Palencia R, Martinez Fernandez V, Pascual-Pascual SI, Martinez-Bermejo A, Garcia-Penas JJ, Roche MC. Hemangiomas of the head, neck and chest with associated vascular and brain anomalies: a complex neurocutaneous syndrome. *Am J Neuroradiol* 1996;17:461-471
7. Pascual-Castroviejo I. Neurocutaneous syndromes in children 2006, Editions John Libbey Eurotext, Montrouge, France, pp 33-54
8. Metry DW, Dowd CF, Barkovich AJ, Frieden IJ. The many faces of PHACE syndrome. *J Pediatr* 2001;139:117-123
9. Pascual-Castroviejo I. Hemangiomas y malformaciones vasculares cutaneas y patologia asociada. Un nuevo sindrome neurocutaneo. *An Pediatr* 2003;58:39-49

10. Pascual-Castroviejo I, Pascual-Pascual SI, Velazquez-Fragua R, Garcia L, Lopez-Gutierrez JC, Viano-Lopez J, Martinez V, Palencia R. Cutaneous hemangiomas and vascular malformations and associated pathology (Pascual-Castroviejo type II syndrome). Study of 41 patients. *Rev Neurol* 2005;41:223-236
11. Pascual-Castroviejo I. The association of extracranial and intracranial vascular malformation in children. *Can J Neurol Sci* 1985;12:139-148
12. Aeby A, Guerrini R, David P, Rodesch G, Raybaud C, Van Bogaert P. Facial hemangioma and cerebral corticovascular dysplasia. *Neurology* 2003;60:1030-1032
13. Grosso S, De Cosmo L, Bonifazi E, Galluzzi P, Farnetani MA, Loffredo P, Anichini C, Berardi R, Morgese G, Balestri P. Facial hemangioma and malformation of the cortical development: a broadening of the PHACE spectrum or a new entity? *Am J Med Genet A* 2004;15;124:192-95
14. Pascual-Castroviejo I, Viano J, Pascual-Pascual SI, Martinez V. Facial hemangioma, agenesis of the internal carotid artery and dysplasia of cerebral cortex: case report. *Neuroradiology* 1995; 37: 692-695

SUPPORTED BY



CONTACT

Swiss Society of Neonatology

www.neonet.ch

webmaster@neonet.ch