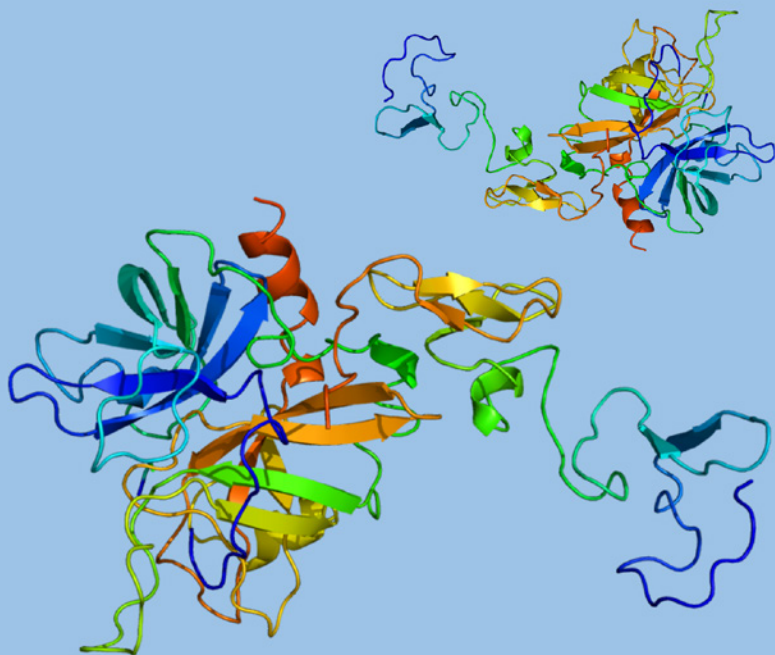


SWISS SOCIETY OF NEONATOLOGY

Neonatal purpura fulminans

March 2017



Bubl B, Gysling Hagemann K, Dallavès F, Bartenstein A, Nelle M, Neonatology (BB, NM), Hematology/Oncology (GHK), Human Genetics (DF), Pediatric Surgery (BA), University Children's Hospital of Berne, Switzerland

Title figure:

Molecular structure of protein C

(Source: www.wikipedia.com)

The PROC-gene is located on chromosome 2q13-q14 and encodes a vitamin K-dependent glycoprotein (1). Protein C (PC) is a zymogen produced by the liver; it is activated when it binds to thrombin. Activated protein C (APC) is a serine protease and has three main functions, two of which concern the coagulation system. First, APC is a very important inhibitor of the coagulation cascade by cleaving and inhibiting activated coagulation co-factors FVa and FVIIIa. Secondly, APC enhances fibrinolysis by inhibiting plasminogen activator inhibitor-1 (PAI-1). In addition, APC has cytoprotective and anti-inflammatory effects.

In PC deficiency, decreased inhibition results in thrombus formation and reduced fibrinolysis. PC deficiency is diagnosed directly by an immunological quantitative method (norm: 65–150%). A functional assay uses the activated partial thromboplastin time (aPTT) (norm: 70–120%) (2). Newborns physiologically have a lower activity of 17–53%; activity increases with advancing degree of maturation.

Acquired PC deficiency must be differentiated from congenital PC deficiency, which is inherited in an autosomal recessive manner. In its heterozygous presentation, it is mostly asymptomatic during the neonatal period. Homozygous or compound heterozygous forms are associated with development of purpura fulminans (3), as well as intravitreal and intracerebral hemorrhages (4). The latter two symptoms may

manifest prenatally (5). In most cases, purpura fulminans, which is caused by dermal microvascular thrombosis, emerges within 2–12 hours after birth. As purpura fulminans develops, skin changes progress from deep-red into purple lesions. These lesions quickly become darker and develop black crusts. They predominantly are observed on the extremities (thighs) and the buttocks (6). Histology is characterized by involvement of small vessels at the junction of dermis and subcutaneous fat with intraluminal thrombi, sparse perivascular infiltrates of neutrophils, extravasated erythrocytes, edema of the dermis and epidermal necrosis with subepidermal blister formation.

The diagnosis of PC deficiency is made when absence of protein C in plasma combined with elevated D-dimers can be demonstrated in patients with a typical clinical presentation. In addition, disseminated intravascular coagulation (DIC) can lead to thrombocytopenia, low levels of fibrinogen or other coagulation factors. Genetic analysis is essential to establish the diagnosis of congenital PC deficiency. There are two different types of this disorder. The more common type I is characterized by a reduced protein concentration (i.e., quantitative deficiency). In type II, on the other hand, protein function is reduced (i.e., qualitative deficiency). Homozygous or compound heterozygous PC deficiency is rare with an incidence of 1:500'000–1:750'000 (7).

Acquired PC deficiency in the neonate results from increased consumption and can be seen in severe group B streptococcus infection (8). Other cases of acquired PC deficiency are secondary to reduced hepatic production, for example in galactosemia, during warfarin therapy or because of immaturity of the liver.

CASE REPORT

At 28 weeks of pregnancy, prenatal ultrasound examination demonstrated bilateral hydrocephalus in a male infant. This was confirmed by fetal MRI; in addition, bilateral grade IV periventricular/intraventricular hemorrhages were demonstrated.

Because of these findings, the infant was delivered by elective Cesarean section at 39 weeks of gestation. Adaptation was uneventful. However, within a few hours after birth, rapidly progressive skin lesions consistent with purpura fulminans developed on his buttocks and thighs (Fig. 1–4), as well as on his left lower leg. While the platelet count was normal, coagulation studies were mildly abnormal with a Quick value of 34% and an aPTT of 54.5 s. On extended coagulation studies, complete absence of PC was demonstrated. On genetic testing, he was found to be compound heterozygous for two disease-causing mutations in the PROC-gene. Additionally, a factor V Leiden mutation was found.

On neurological examination, the infant was hypotonic with periods of agitation. Both conventional EEG and aEEG were physiological. On cranial ultrasound examinations, non-progressive post-hemorrhagic hydrocephalus was confirmed. In addition, bilateral vitreous and retinal hemorrhages were seen on fundoscopy.

After initial administration of fresh frozen plasma, intravenous PC concentrate (Ceprothin®, Baxter) was

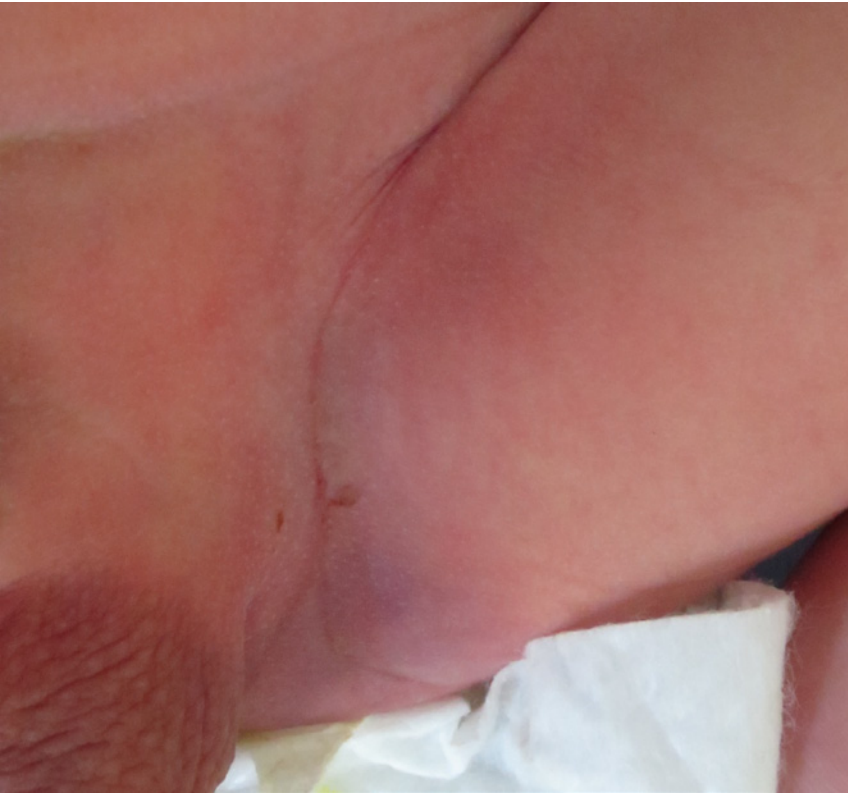

Fig. 1

Early skin changes in the left groin region a few hours after birth.

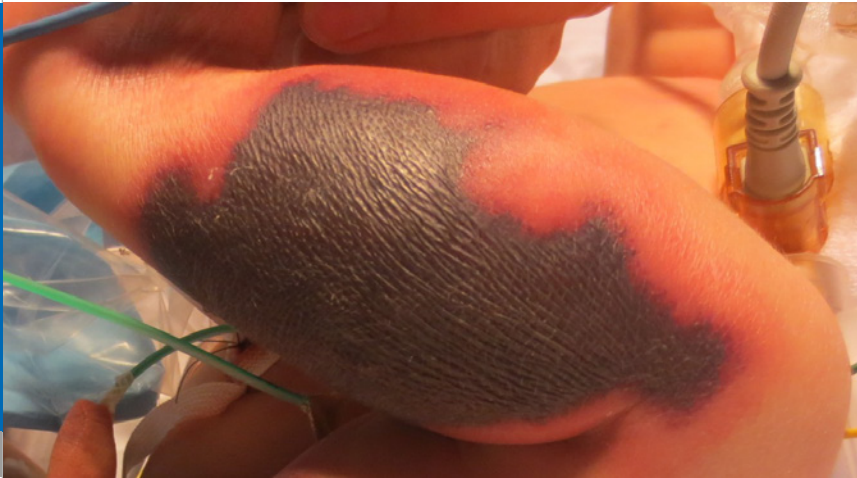


Fig. 2

Rapid progression of purpura fulminans: appearance of the skin on the left thigh at 24 hours of age.

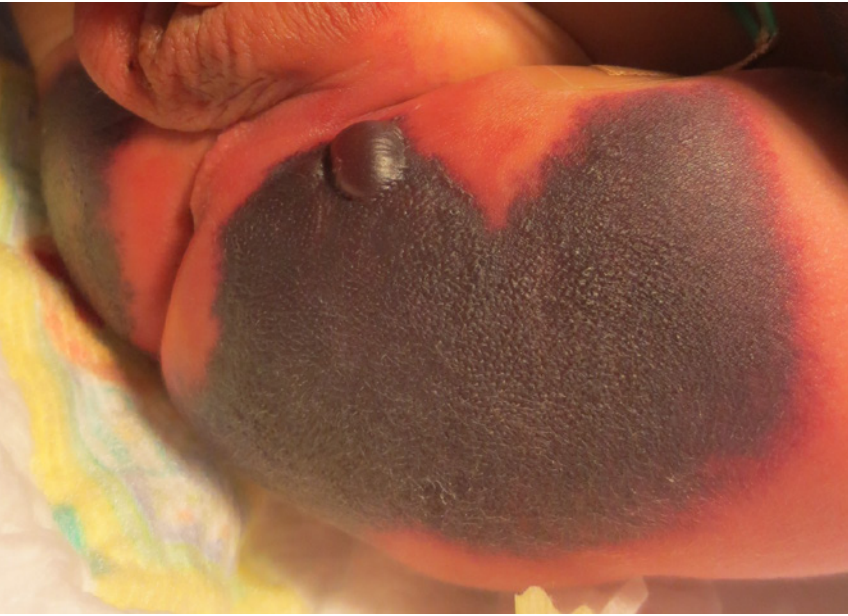

Fig. 3

Rapid progression of purpura fulminans: appearance of the skin on the buttocks at 24 hours of age

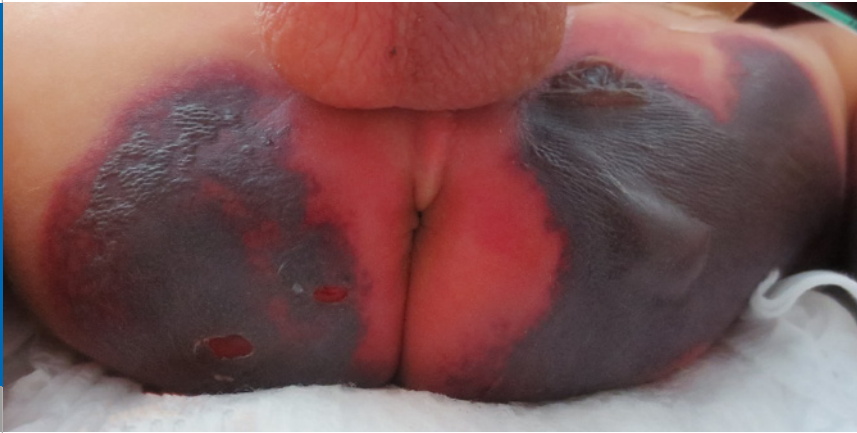

Fig. 4

Rapid progression of purpura fulminans: appearance of the skin on the buttocks at 48 hours of age.

started. With this treatment, there was no further progression of the purpuric lesions, and the skin began to heal (Fig. 5, 6). Dosing of PC concentrate therapy was based on aPTT measurements. On one occasion, when the PC activity measured by the aPTT method fell below 30%, swelling of the legs and worsening of ventilation were noted. Thrombotic and thromboembolic events were excluded, and increased dosing of PC concentrate was followed by clinical improvement.

The challenging transition from intravenous to subcutaneous injections was managed well without complications. With a subcutaneous dose of 200 E/kg/d PC concentrate twice daily appropriate PC blood levels were measured. The infant was discharged home at the age of two months.

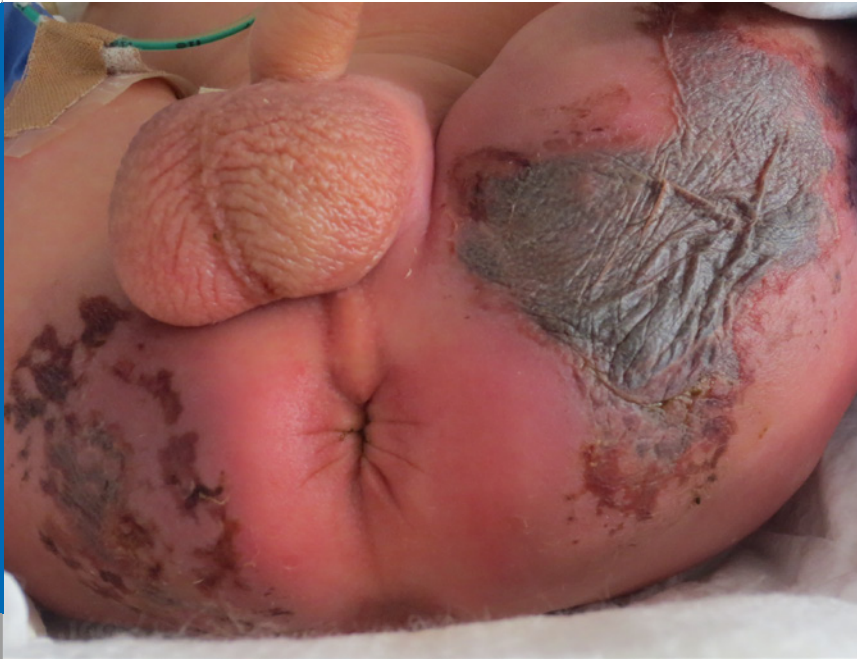

Fig. 5

Improvement of skin changes on day of life 8 after treatment with PC replacement.

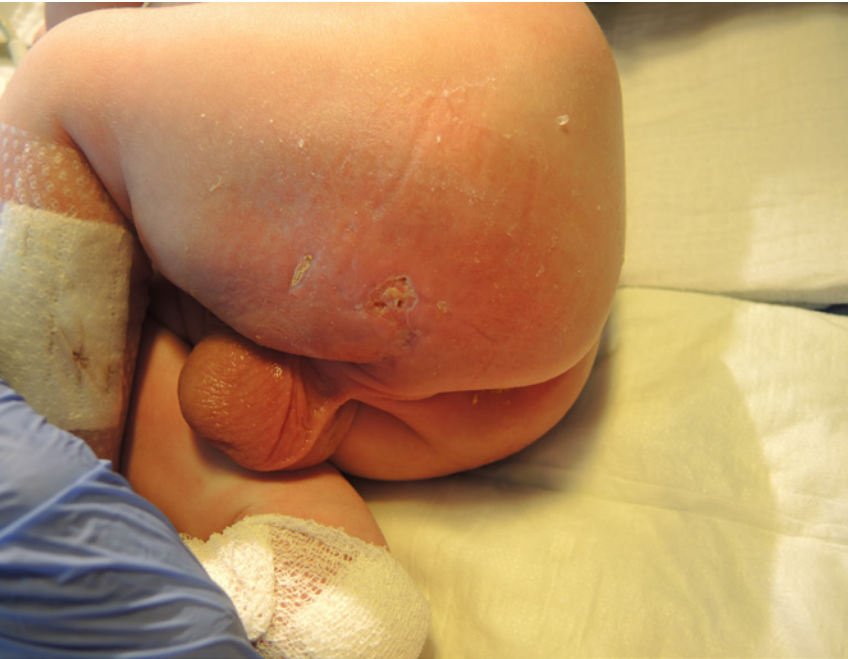

Fig. 6

At 28 days of life, the purpura fulminans lesions have healed almost completely.

DISCUSSION

Early recognition and diagnosis, followed by rapid therapeutic intervention are extremely important in patients with purpura fulminans. In cases of acquired PC deficiency, the underlying causes must be uncovered and treated promptly. Symptomatic emergency treatment with intravenous fresh frozen plasma followed by PC concentrate is identical for both acquired and inherited forms of PC deficiency (9).

For long-term therapy of severe PC deficiency, oral anticoagulation with warfarin is still used most commonly. However, adequate dosing can be challenging in small children (10). More recently, substitution of PC concentrate – if available – has become the treatment of choice. Obtaining and maintaining long-term vascular access can be difficult and catheter-associated complications are common. Administration of protein C concentrate via the subcutaneous route was first described by Minford et al. in 1996 (11). Other reports followed (10,12–14). Based on these encouraging reports, we decided to switch our patient from intravenous to subcutaneous PC replacement therapy prior to discharge home. A PC dose of 200 U/kg/day (slightly below the recommended 250 U/kg/day published in the literature) (15), resulted in adequate PC levels (> 30% measured by the aPTT method) without increase of D-dimers.

In 2009, Lee et al. described a six-month-old girl with homozygous protein C deficiency who was success-

fully treated with living donor liver transplantation. They suggested that liver transplantation might be an alternative and curative treatment for children with homozygous protein C deficiency (16).

CONCLUSION

Our patient with a compound heterozygous mutation in the PROC-gene presented with the typical clinical triad of periventricular/intraventricular hemorrhage, purpura fulminans, and vitreous hemorrhage. Rapid diagnosis and therapy of congenital PC deficiency with fresh frozen plasma and PC concentrate are essential. For long-term therapy, subcutaneous administration of PC concentrate appears to be a reliable and safe method.

1. Foster DC, Yoshitake S, Davie EW. The nucleotide sequence of the gene for human protein C. Proc Natl Acad Sci USA 1985;82:4673 – 4677 (*Abstract*)
2. Miletich JP. Laboratory diagnosis of protein C deficiency. Semin Thromb Hemost 1990;16:169 – 176 (no abstract available)
3. Marlar RA, Montgomery RR, Broekmans AW. Diagnosis and treatment of homozygous protein C deficiency. Report of the Working Party on Homozygous Protein C Deficiency of the Subcommittee on Protein C and Protein S, International Committee on Thrombosis and Haemostasis. J Pediatr 1989;114:528 – 534 (no abstract available)
4. Hattenbach LO, Beeg T, Kreuz W, Zubcov A. Ophthalmic manifestation of congenital protein C deficiency. J AAPOS 1999;3:188 – 190 (*Abstract*)
5. Kirkinen P, Salonvaara M, Nikolajev K, Vanninen R, Heinonen K. Antepartum findings in fetal protein C deficiency. Prenat Diagn 2000;20:746 – 749 (*Abstract*)
6. Manco-Johnson MJ, Abshire TC, Jacobson LJ, Marlar RA. Severe neonatal protein C deficiency: prevalence and thrombotic risk. J Pediatr 1991;119:793 – 798 (*Abstract*)
7. Marlar RA, Neumann A. Neonatal purpura fulminans due to homozygous protein C or protein S deficiencies. Semin Thromb Hemost 1990;16:299–309 (*Abstract*)
8. Zenciroglu A, Karagol BS, Ipek MS, Okumus N, Yarali N, Aydin M. Neonatal purpura fulminans secondary to group B streptococcal infection. Pediatr Hematol Oncol 2010;27:620 – 625 (*Abstract*)

9. Müller FM, Ehrental W, Hafner G, Schranz D. Purpura fulminans in severe congenital protein C deficiency: monitoring of treatment with protein C concentrate. *Eur J Pediatr* 1996;155:20 – 25 ([*Abstract*](#))
10. Peters C, Casella JF, Marlar RA, Montgomery RR, Zinkham WH. Homozygous protein C deficiency: observations on the nature of the molecular abnormality and the effectiveness of warfarin therapy. *Pediatrics* 1988;81:272 – 276 ([*Abstract*](#))
11. Minford AM, Parapia LA, Stainforth C, Lee D. Treatment of homozygous protein C deficiency with subcutaneous protein C concentrate. *Br J Haematol* 1996;93:215 – 216 ([*Abstract*](#))
12. de Kort EHM, Vrancken SLAG, van Heijst AFJ, Binkhorst M, Cuppen MPJM, Brons PPT. Long-term subcutaneous protein C replacement in neonatal severe protein C deficiency. *Pediatrics* 2011;127:e1338 – e1342 ([*Abstract*](#))
13. Minford A, Behnisch W, Brons P, et al. Subcutaneous protein C concentrate in the management of severe protein C deficiency – experience from 12 centres. *Br J Haematol* 2014;164:414 – 421 ([*Abstract*](#))
14. Piccini B, Capirchio L, Lenzi L, et al. Continuous subcutaneous infusion of protein C concentrate using an insulin pump in a newborn with congenital protein C deficiency. *Blood Coagul Fibrinolysis Int J Haemost Thromb* – ;25:522 – 526 ([*Abstract*](#))
15. Mathias M, Khair K, Burgess C, Liesner R. Subcutaneous administration of protein C concentrate. *Pediatr Hematol Oncol* 2004;21:551 – 556 ([*Abstract*](#))
16. Lee MJ, Kim KM, Kim JS, Kim YJ, Lee YJ, Ghim TT. Long-term survival of a child with homozygous protein C deficiency successfully treated with living donor liver transplantation. *Pediatr Transplant* 2009;13:251 – 254 ([*Abstract*](#))

SUPPORTED BY  **Vifor Pharma**

CONTACT Swiss Society of Neonatology
www.neonet.ch
webmaster@neonet.ch