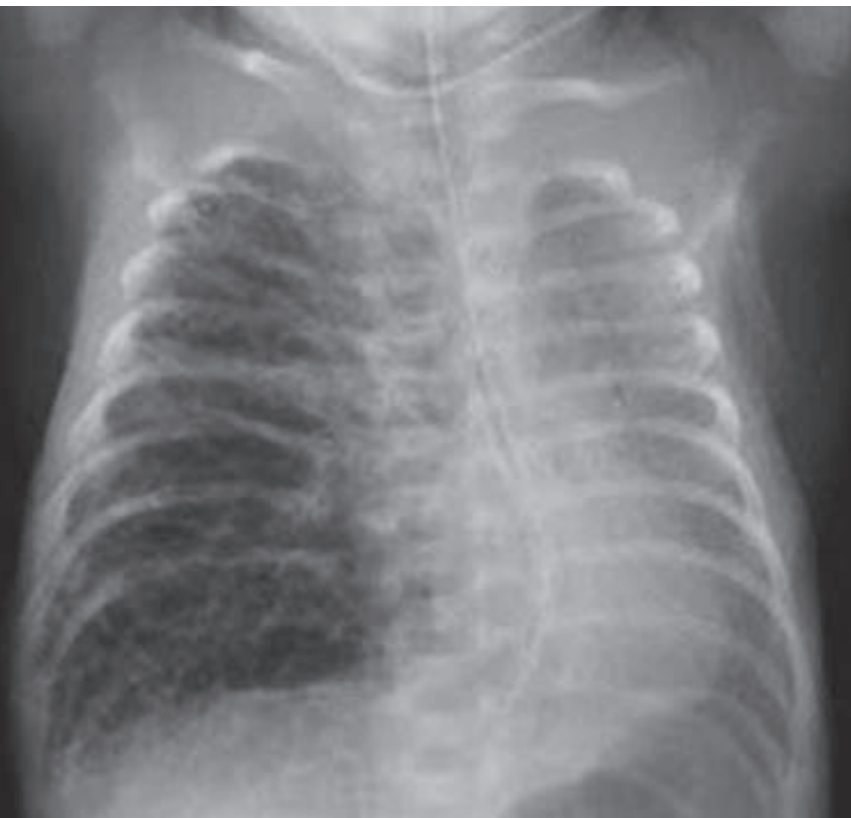

SWISS SOCIETY OF NEONATOLOGY

Selective bronchial intubation for unilateral PIE

October 2000



Berger TM, Jöhr M, Neonatal and Pediatric Intensive Care Unit
(BTM), Kinderspital Luzern, Department of Anesthesiology
(JM), Kantonsspital Luzern

A female preterm infant was delivered at 29 1/7 weeks of gestation by cesarean section secondary to maternal pre-eclampsia. Birth weight was 970 g. She was conventionally ventilated and received two doses of surfactant for hyaline membrane disease. On the 5th day of life, she was successfully extubated and required an FiO_2 of 25%. On the 11th day of life, she was noted to have increasing respiratory distress and an FiO_2 requirement of 35%. Chest x-ray (Fig. 1) showed marked unilateral pulmonary interstitial emphysema (PIE). Conservative positioning treatment failed and she continued to deteriorate over the next 48 hours (Fig. 2). On the 13th day of life, selective intubation of the left mainstem bronchus was performed under fiberoptic guidance. Because single lung ventilation with high frequency oscillatory ventilation was not successful, the patient was switched to conventional mechanical ventilation with low tidal volumes (3 ml/kg). Within 24 hours, large areas of the right lung had become atelectatic and most of the PIE had disappeared (Fig. 3). On the 15th day of life, the endotracheal tube was pulled back above the carina and the infant was extubated 3 days later (Fig. 4). There was no recurrence of PIE, and the infant no longer required supplemental oxygen.

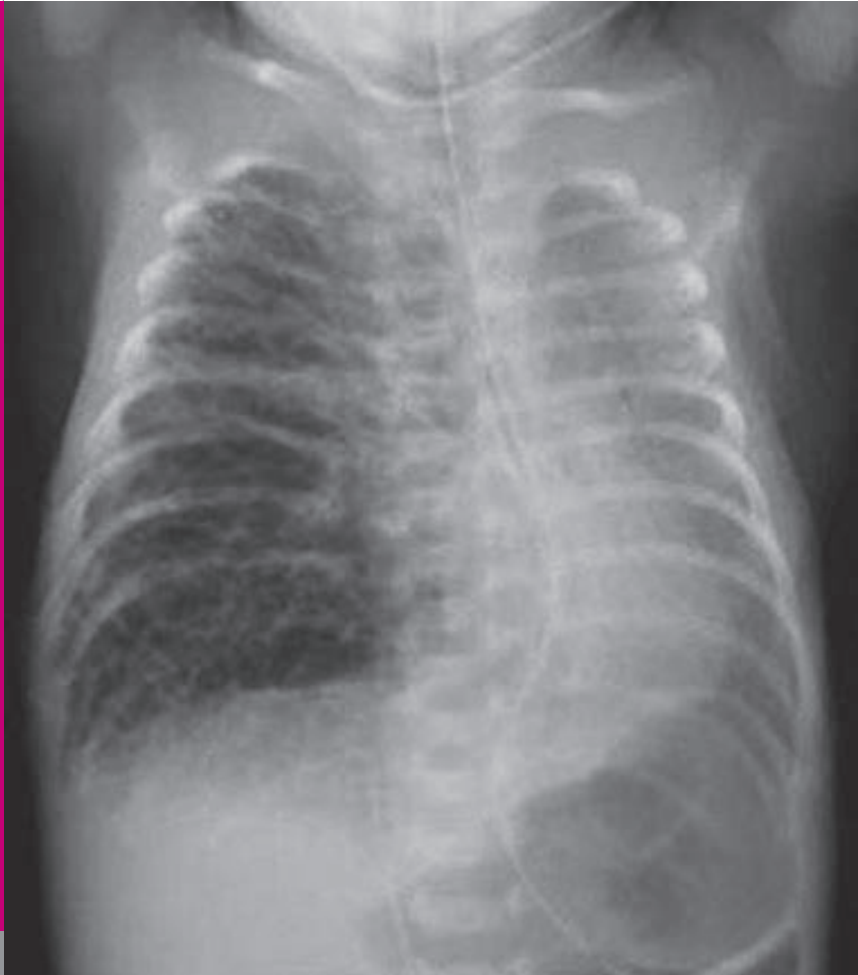

Fig. 1

CXR on DOL 11: marked PIE with mediastinal shift.

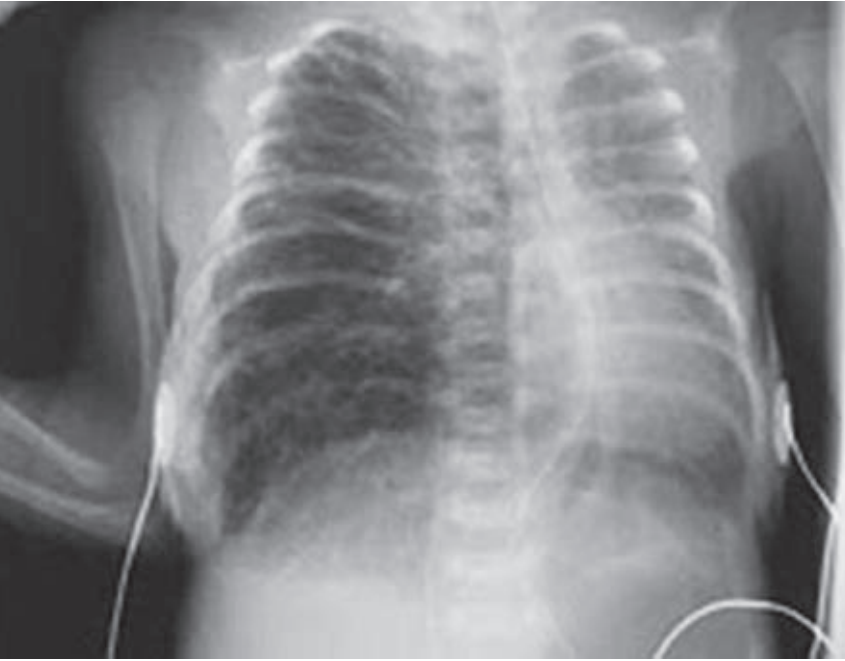

Fig. 2

CXR on DOL 12: worsening unilateral PIE.

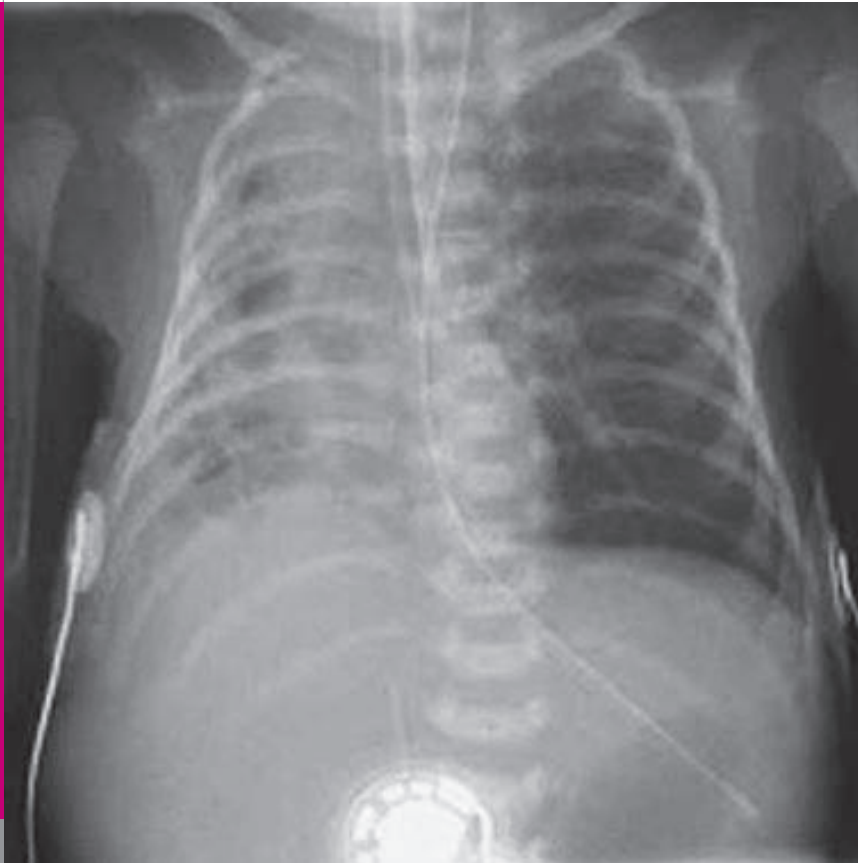


Fig. 3

CXR on DOL 14: after 24 hours of single lung ventilation, the right-sided PIE had regressed greatly.

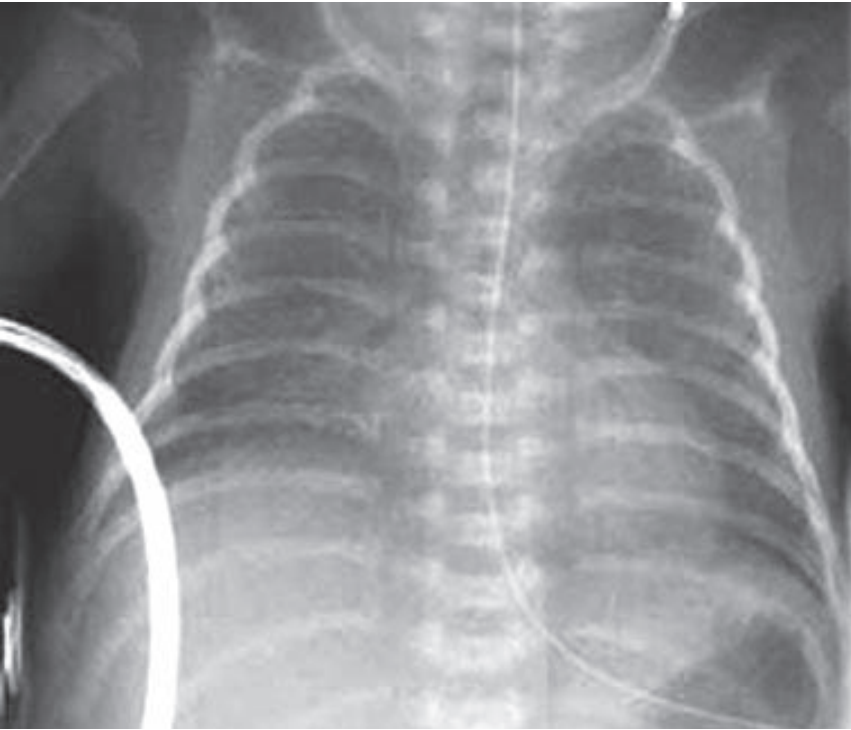


Fig. 4

CXR on DOL 18: follow-up CXR with no evidence of

DISCUSSION

PIE is a well-recognized form of air leak in the pre-term infant. Bilateral occurrence is more common, but unilateral presentations have also been described. Frequently, unilateral PIE is progressive leading to significant mediastinal shift and compression of the contralateral lung. Depending on the severity of respiratory and/or cardiovascular compromise, the following treatment options have been suggested in the literature:

1. Conservative treatment by positioning the affected side down
2. Single lung ventilation either by selective bronchial intubation (SBI) or selective bronchial obstruction with a balloon catheter (SBO)
3. Surgery (lobectomy, pneumonectomy)

It is interesting to note that the reported duration of successful single lung ventilation varied between 10 hours and 10 days. Potential complications of single lung ventilation include collapse of the upper lobes of the ventilated lungs, pneumothorax, infection and pressure necrosis of the intubated/occluded bronchus.

See also COTM 12/2002

1. Gortner L, Pohlandt F, Bartmann P. Treatment of unilateral space-occupying pulmonary interstitial emphysema with positioning measures and high-frequency ventilation. *Monatsschr Kinderheilkd* 1988; 136:432-435. (*Abstract*)
2. Leonidas JC, Hall RT, Rhodes PG. Conservative management of unilateral pulmonary interstitial emphysema under tension. *J Pediatr* 1975; 87:776-778. (*Abstract*)
3. Swingle HM, Eggert LD, Bucciarelli RL. New approach to management of unilateral tension pulmonary interstitial emphysema in premature infants. *Pediatrics* 1984; 74:354-357. (*Abstract*)
4. O'Donovan D, Wearden M, Adams J. Unilateral pulmonary interstitial emphysema following pneumonia in a preterm infant successfully treated with prolonged selective bronchial intubation. *Am J Perinatol* 1999; 16:327-331. (*Abstract*)
5. Weintraub Z, Oliven A, Weissman D, Sonis Z. A new method for selective left main bronchus intubation in premature infants. *J Pediatr Surg* 1990; 25:604-606. (*Abstract*)
6. Feldmann M, Parisot S, Masselot M, Klink Z, Marchal C. Selective bronchial occlusion in the treatment of unilateral interstitial emphysema in respiratory distress in premature infants. *Pediatric* 1993; 48:447-449. (*Abstract*)
7. Gourrier E, Phan F, Wood C, Mokhtari M, Chenel C. Value and limits of selective bronchial obstruction in neonatal unilateral interstitial emphysema. *Arch Pediatr* 1997; 4:751-754. (*Abstract*)
8. Levine DH, Trump DS, Waterkotte G. Unilateral pulmonary interstitial emphysema: a surgical (2 words) approach to treatment. *Pediatrics* 1981; 68:510-514. (*Abstract*)
9. Zerella JT, Trump DS. Surgical management of neonatal interstitial emphysema. *J Pediatr Surg* 1987; 22:34-37. (*Abstract*)

SUPPORTED BY



CONTACT

Swiss Society of Neonatology
www.neonet.ch
webmaster@neonet.ch