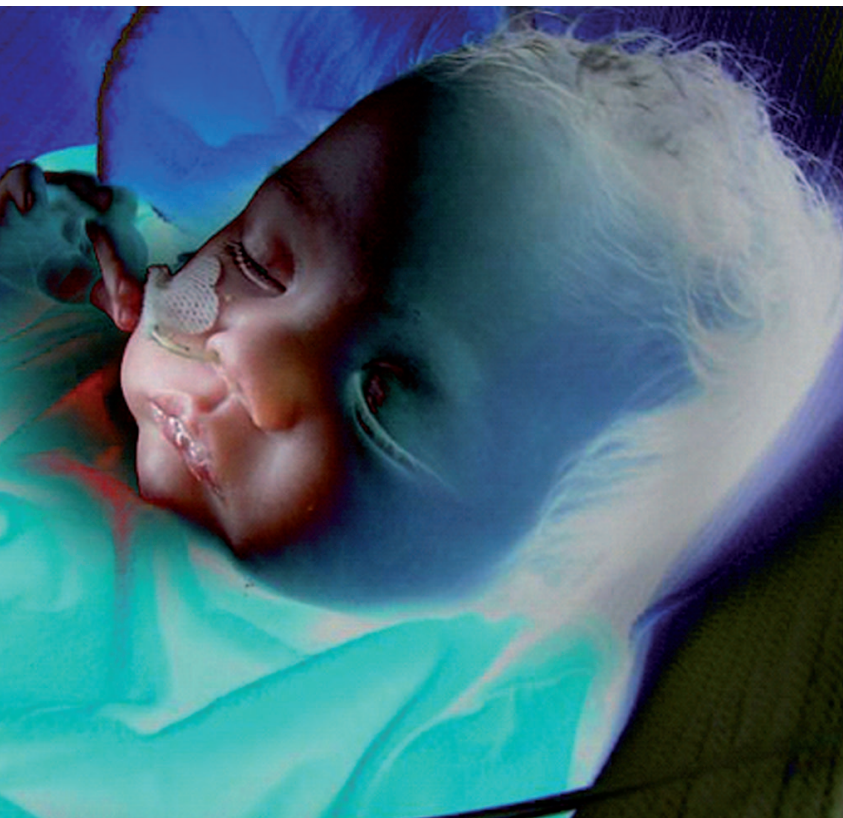

SWISS SOCIETY OF NEONATOLOGY

When a routine nursing
procedure goes wrong:
critical incident in a term
infant

JANUARY 2011



Berger TM, Fontana M, Caduff JH, Neonatal and Pediatric Intensive Care Unit (BTM, FM), Pediatric Radiology (CJH), Children's Hospital of Lucerne, Switzerland

This female infant was born to a 22-year-old G1/P1 who had a history of illicit drug use. Throughout this pregnancy she took 80 mg of methadone per day. No additional drug use was documented. The girl was delivered by Caesarean section. Umbilical cord pH values and Apgar scores were normal. Her birth weight was 3550 g. Within 24 hours, she developed symptoms of drug withdrawal with modified Finnigan scores exceeding 9. At this point, she was admitted to the intermediate care nursery for treatment of her neonatal abstinence syndrome. She was begun on tincture of opium at a dose of 0.04 mg/kg/dose every 4 hours.

On the third day of life, she developed poor feeding and a nasogastric feeding tube (NGT) was inserted both for gavage feeding and the administration of tincture of opium. Six hours later, the resident on call was informed that the nurse had aspirated 2 ml of grossly bloody fluid through the NGT prior to the planned administration of the next feeding. Clinical examination of the baby was unremarkable with the exception of a slightly increased respiratory rate (60-70 breaths per minute) without additional signs of distress.

Complete blood count (including platelets), C-reactive protein concentration and prothrombin time were all normal. Because of the infant's isolated tachypnea a chest X-ray was obtained. The study revealed malposition of the NGT which deviated from the mediastinum and projected over the lower part of the left hemithorax

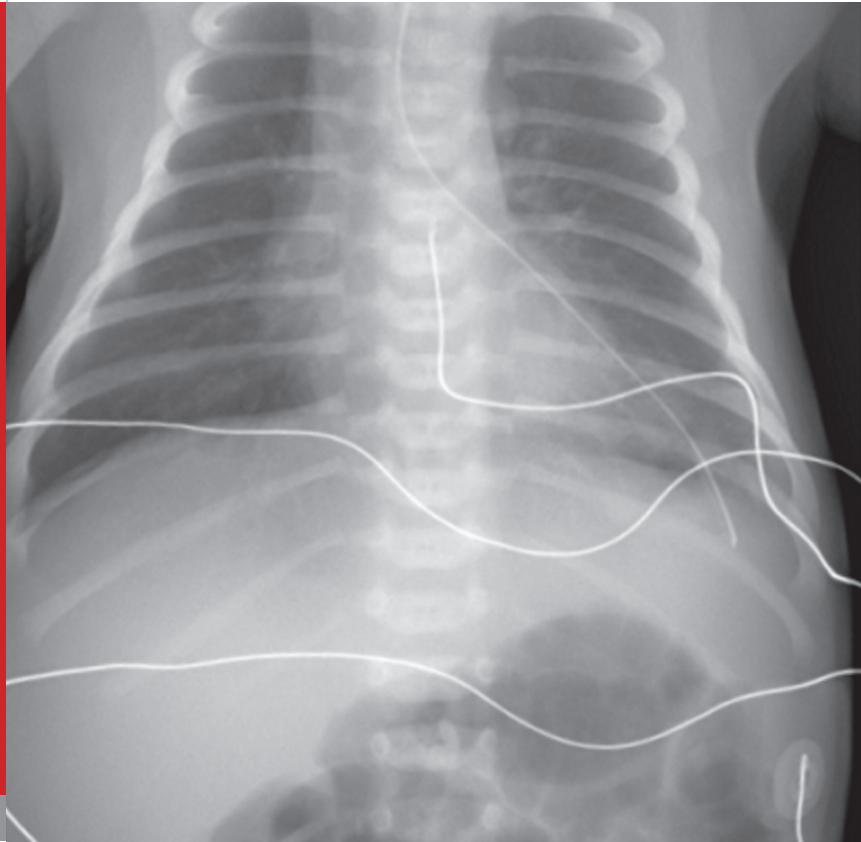


Fig. 1

Chest X-ray obtained on the 3rd day of life: NGT projecting over the left hemithorax and mild opacification of the lung adjacent to the left heart border

Horizontal

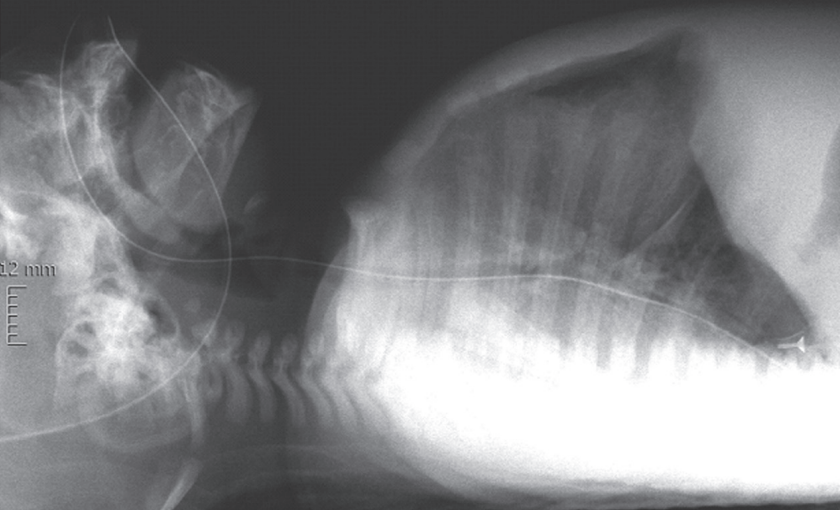


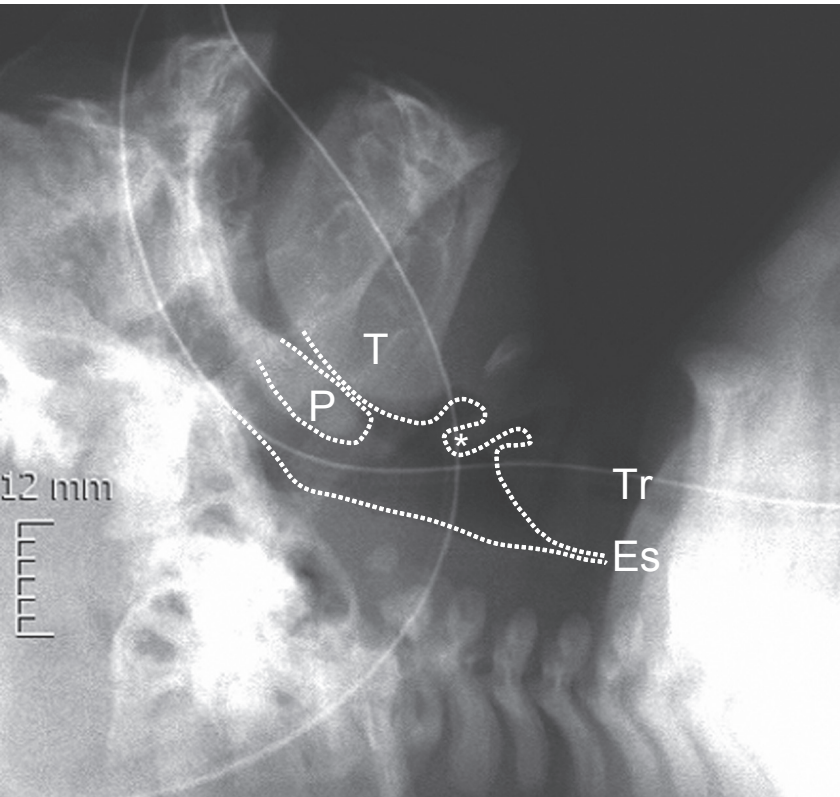
Fig. 2

Lateral chest X-ray using a horizontal beam technique: NGT enters the larynx and passes through the trachea and the left main bronchus (see also magnification in Fig. 3).

(Fig. 1). It appeared likely that the NGT had been advanced through the vocal cords and the trachea into the left bronchial system. However, even though there was no mediastinal air visible on the chest X-ray, esophageal perforation with the NGT entering the pleural space was also considered. To clarify this issue, the NGT was left in situ and a lateral chest X-ray using a horizontal beam technique was obtained. This imaging study unequivocally confirmed that the NGT had been placed into the bronchial system (Fig. 2, 3).

Prior to the removal of the NGT an aspirate was sent for bacterial culture and later grew *E. coli*. The infant was treated with amoxicillin and amikacin for seven days and recovered uneventfully.

The nurse who had placed the NGT later reported that the infant did not cough when the NGT was inserted. As usual, she injected 5 ml of air and thought that she heard air entering the stomach with her stethoscope. However, she also remembered that there was some retching when 10 ml of mother's milk was fed through the NGT.

**Fig. 3**

Magnification of the neck region: the NGT passes behind the epiglottis (asterisk) through the vocal cords into the trachea (Tr); the esophagus (Es) is located more posteriorly (P, palate; T, tongue).

DISCUSSION

Insertion of a NGT is one of the most frequent interventions performed in neonatal units. X-ray is probably the only certain way to verify NGT position, but routinely getting an X-ray following each NGT placement would be costly, impractical and associated with unacceptable radiation exposure. Most units do not routinely obtain X-rays to verify proper placement but rely on aspiration of gastric contents and auscultation of air insufflation over the abdomen. Measuring the pH of the NGT aspirate is another bed-side test that can easily be performed (1).

NGT misplacement into the lungs has been estimated to occur in as many as 5% of all NGT insertions in children (1). Coughing and cyanosis during insertion may indicate that the NGT has entered the lower respiratory tract. We speculate that a cough response may have been suppressed in our patient by the morphine she received to treat her neonatal abstinence syndrome. However, pulmonary symptoms may also only occur once tube feedings are begun. Patients will then develop signs and symptoms of aspiration pneumonia. A rarer, but significantly more serious complication of NGT insertion is pharyngoesophageal and esophageal perforation (2-6). Schuman et al. have observed 6 iatrogenic pharyngoesophageal perforation injuries among 5910 NICU patients, for an overall incidence of 0.10% (4). The more immature the infants, the higher the risk (0.30% at 27-32 weeks of gestation, 0.38% at less than 27 weeks of gestation). Once an NGT has

perforated the esophagus it can remain within the mediastinum (5), enter the pleural space (2), or even perforate the pericardial sac (7).

There is consensus that nearly all pharyngeal and most NGT-related esophageal injuries can be safely managed non-operatively with appropriate respiratory support and broad-spectrum antibiotic therapy (6). Infants with pharyngeal injuries can be safely fed through an appropriately placed NGT, while esophageal perforations require gastric drainage and parenteral nutrition. Su and colleagues have suggested that a second NGT should be inserted while the first one remains in place to prevent repeat passage through the iatrogenic injury site (5). Thoracotomy with primary esophageal repair is reserved for an intrathoracic leak not controlled by tube drainage, which suggests a large tear (6).

In summary, verification of NGT placement in neonates is important. If placement is difficult, accompanied by unusual symptoms or the results of bedside techniques for confirmation of proper NGT position are doubtful, a chest X-ray should be obtained. A high index of suspicion will lead to timely recognition of NGT malposition and allow for appropriate therapeutic interventions that almost always will lead to complete recovery of the patient.

REFERENCES

1. Farrington M, Lang S, Cullen L, Stewart S. Nasogastric tube placement verification in pediatric and neonatal patients. *Pediatr Nurs* 2009;35:17-24
2. Al-Sawan RMZ, Soni AL, Q A-S. Esophageal perforation in neonates: report of seven cases from Kuwait. *Kuwait Med J* 2005;37:203-206
3. Bader P, Goelz R, Drews K, Berger D, Speer CP. [Iatrogenic esophageal perforation-- severe complication in the care of premature infants]. *Z Geburtshilfe Neonatol* 1996;200:33-35
4. Schuman TA, Jacobs B, Walsh W, Goudy SL. Iatrogenic perinatal pharyngoesophageal injury: a disease of prematurity. *Int J Pediatr Otorhinolaryngol*;74:393-397
5. Su BH, Lin HY, Chiu HY, Lin HC. Esophageal perforation: a complication of nasogastric tube placement in premature infants. *J Pediatr* 2009;154:460, 460 e1
6. Sudhakaran N, Kirby CP. Pitfalls of gastric intubation in premature infants. *J Paediatr Child Health* 2001;37:195-197
7. Hanafy Eel D, Ashebu SD, Naqeeb NA, Nanda HB. Pericardial sac perforation: a rare complication of neonatal nasogastric tube feeding. *Pediatr Radiol* 2006;36:1096-1098

SUPPORTED BY



CONTACT

Swiss Society of Neonatology
www.neonet.ch
webmaster@neonet.ch