

SWISS SOCIETY OF NEONATOLOGY

Prenatal diagnosis and
postnatal management of
meconium pseudocysts

September 2007



At 31 5/7 weeks of gestation, a prenatal ultrasound examination revealed polyhydramnios and intraabdominal calcifications with hyperechogenic ascites. A provisional diagnosis of small bowel obstruction, perforation and meconium peritonitis was made. At 34 0/7 weeks of gestation, there was now a left-sided intraabdominal hyperechogenic cyst; the ascites had resolved but the previously recognized polyhydramnios had persisted. Nine days later, ultrasound examination revealed a hyperechogenic ring like structure with a hypoechoogenic centre measuring 2x3 cm in the left abdomen (Fig. 1-4).

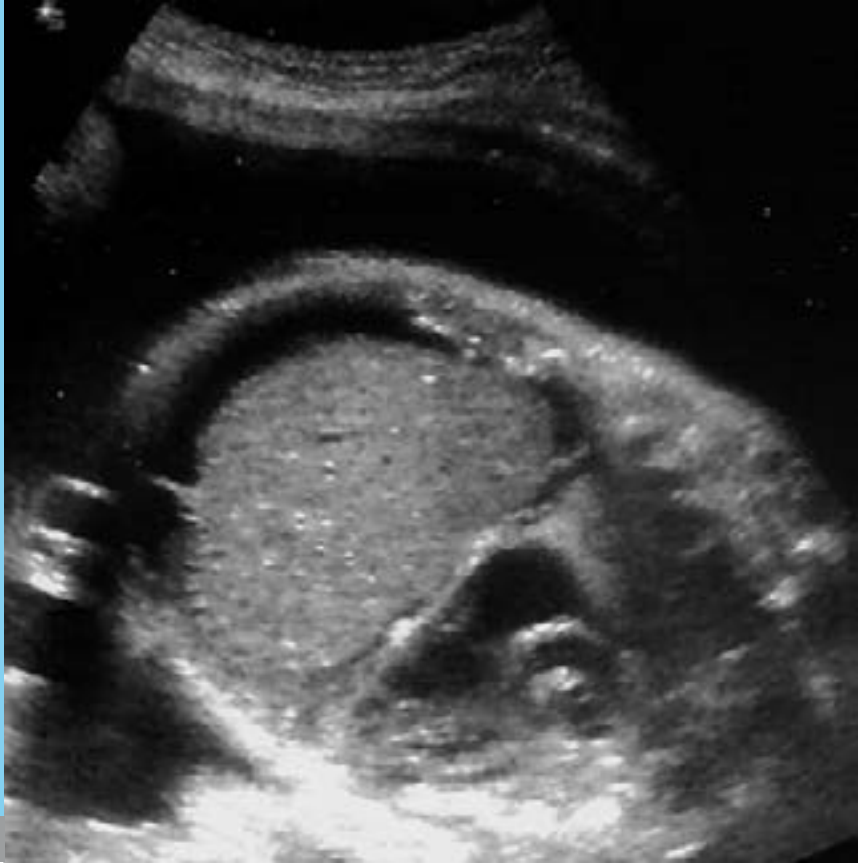

Fig. 1

Prenatal ultrasound at 31 5/7 weeks: ascites and polyhydramnion.

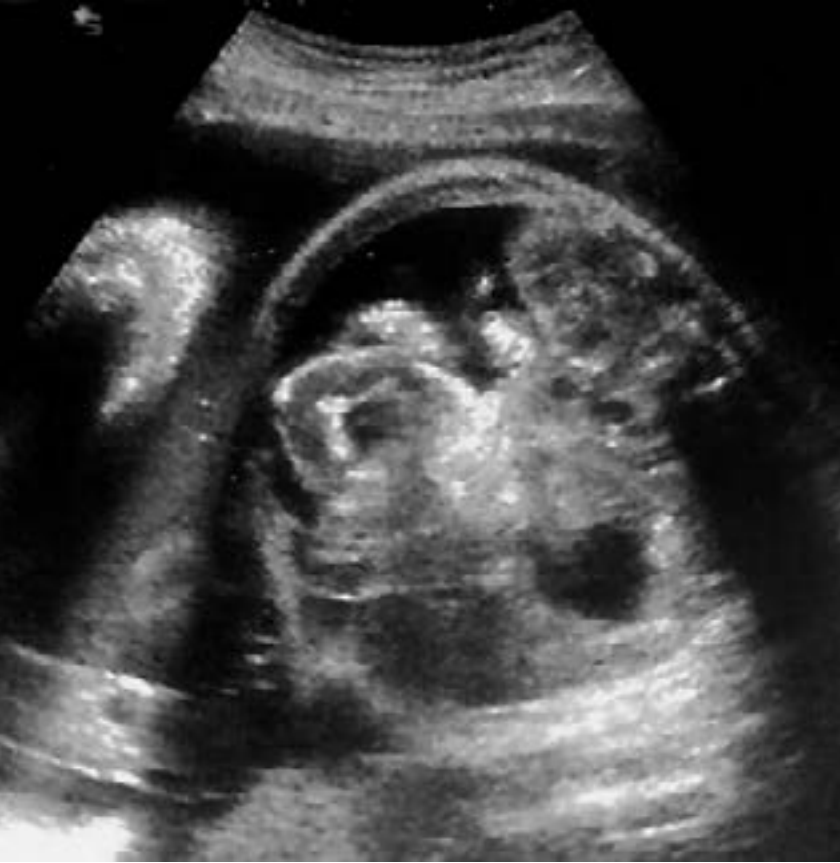

Fig. 2

Prenatal ultrasound at 31 5/7 weeks: ascites and thickened echogenic bowel loops.

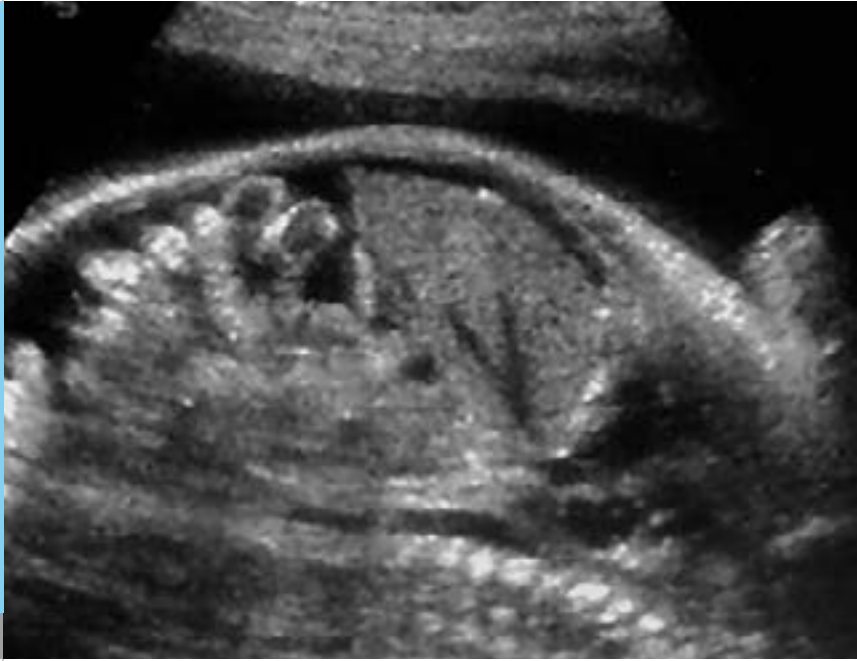

Fig. 3

Prenatal ultrasound at 31 5/7 weeks: ascites and thickened echogenic bowel loops.

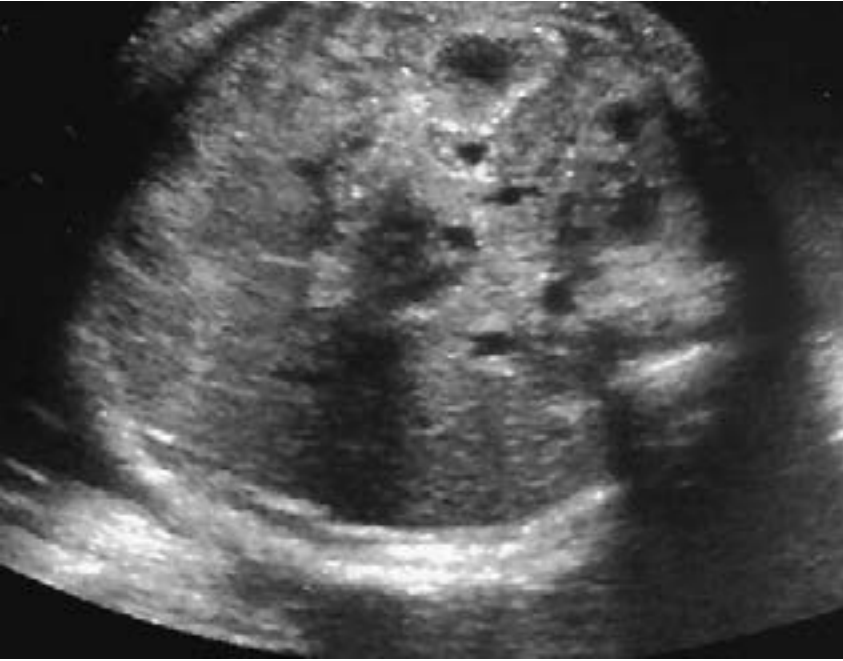


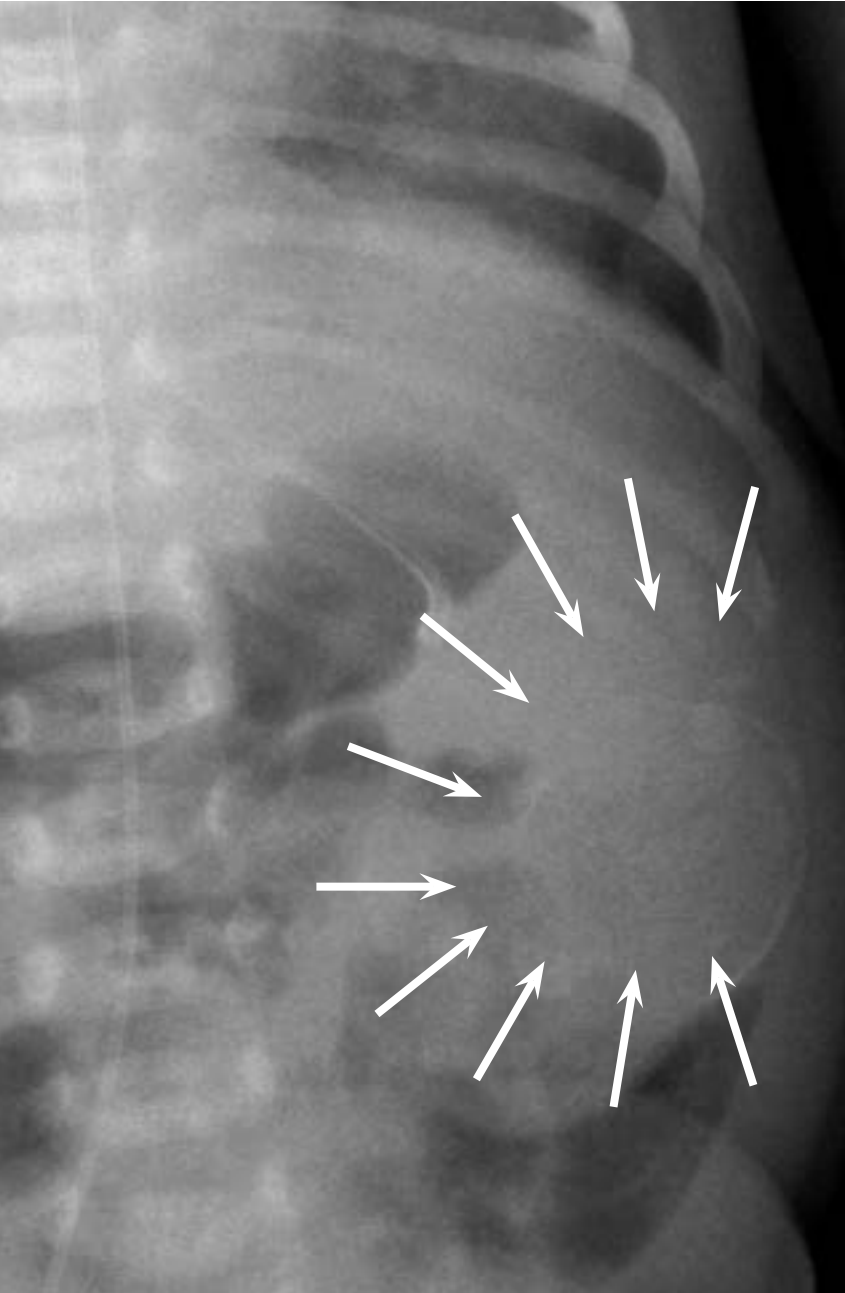
Fig. 4

Prenatal ultrasound at 34 0/7 weeks: ringlike cystic structure, persistent polyhydramnion.

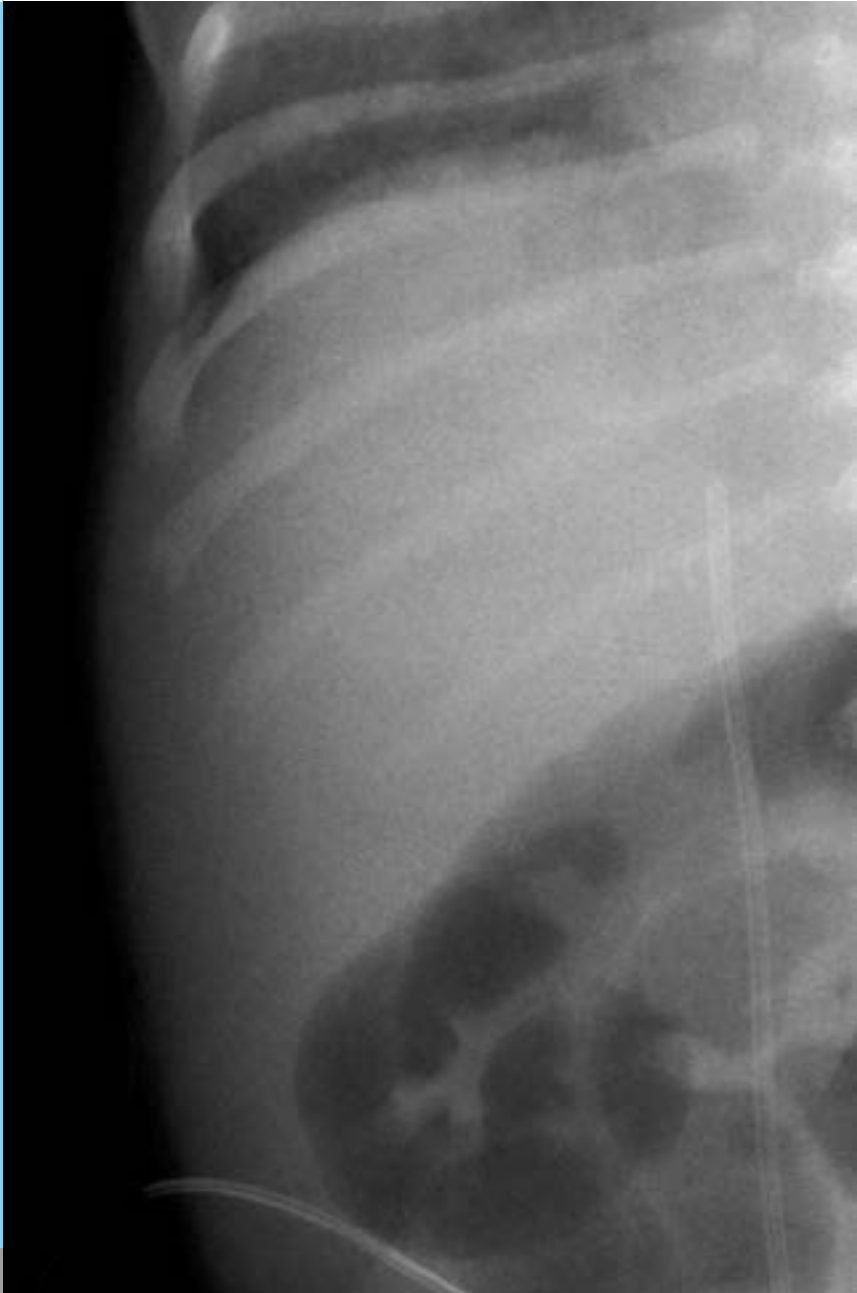

Fig. 5

Abdominal plain film: calcified border of cyst projecting over the left abdomen (arrow heads).



At 39 1/7 weeks of gestation, a 3300 g female infant was born by spontaneous vaginal delivery. There was thick meconium stained amniotic fluid. Her primary adaptation was mildly depressed with Apgar scores of 6, 7 and 8 at 1, 5 and 10 minutes, respectively. After birth, she developed respiratory distress with tachypnea and an oxygen requirement. She was intubated in the delivery room and put on conventional mechanical ventilation. Chest x-ray at 2 hours of life was consistent with retained fetal lung fluid and small atelectatic areas. She was successfully extubated within 24 hours.

Physical examination was unremarkable except for a palpable abdominal mass measuring 2x2 cm on the left. On plain abdominal X-rays scattered abnormal calcifications were seen (Fig. 5). On abdominal ultrasound multiple calcifications and a peritoneal pseudocyst were identified (Fig. 6, 7). In addition, there was a small fistula to the transverse colon (Fig. 8, 9). Contrast imaging showed a normal calibre of the colon and no leakage of contrast material into the peritoneal cavity.

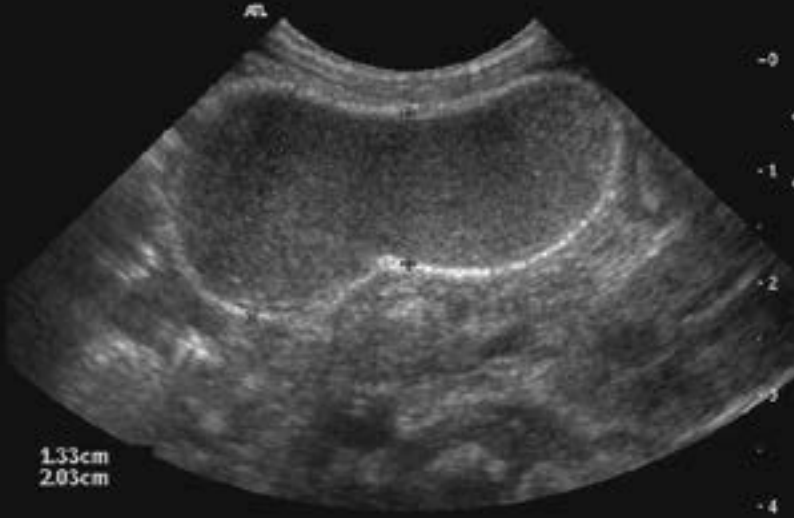


Fig. 6

Postnatal ultrasound: calcified cyst with echogenic contents.

Postnatal ultrasound: calcified cyst with posterior shadowing.

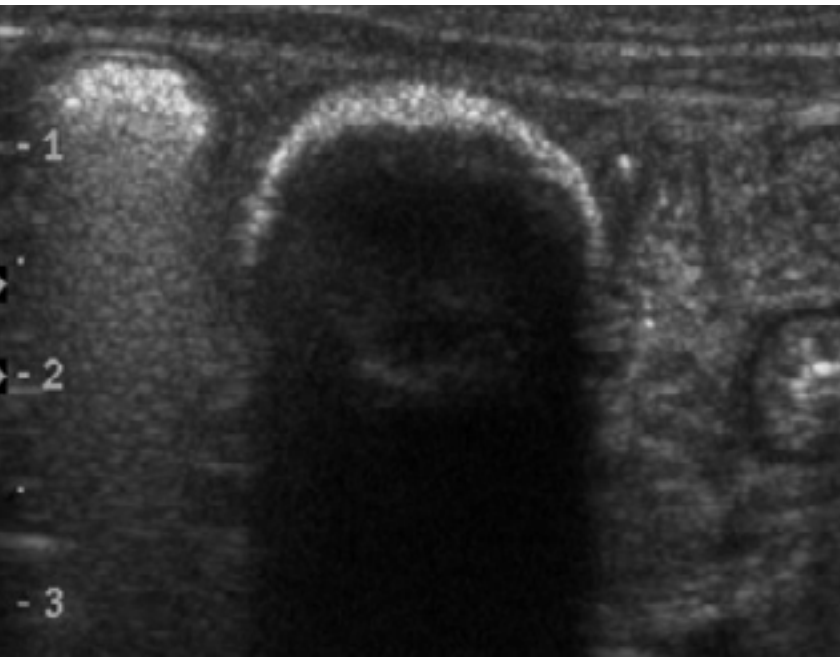


Fig. 7

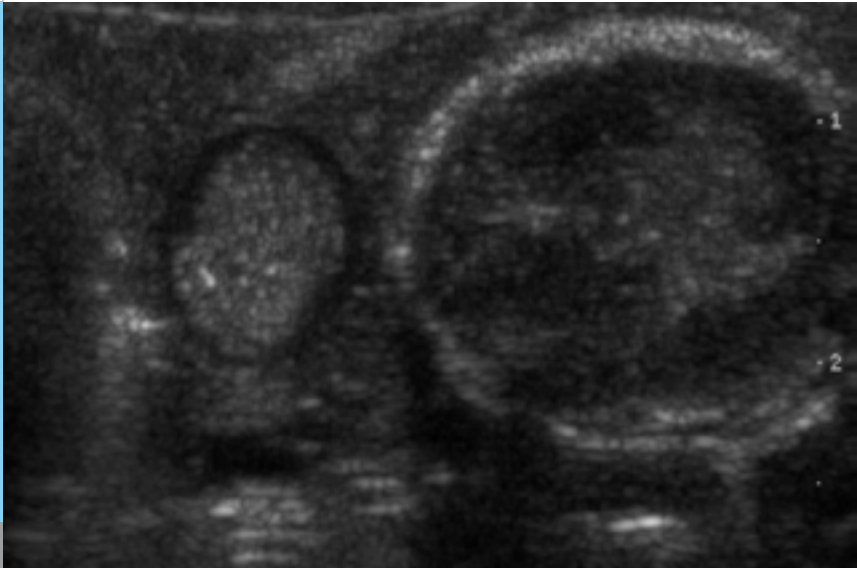
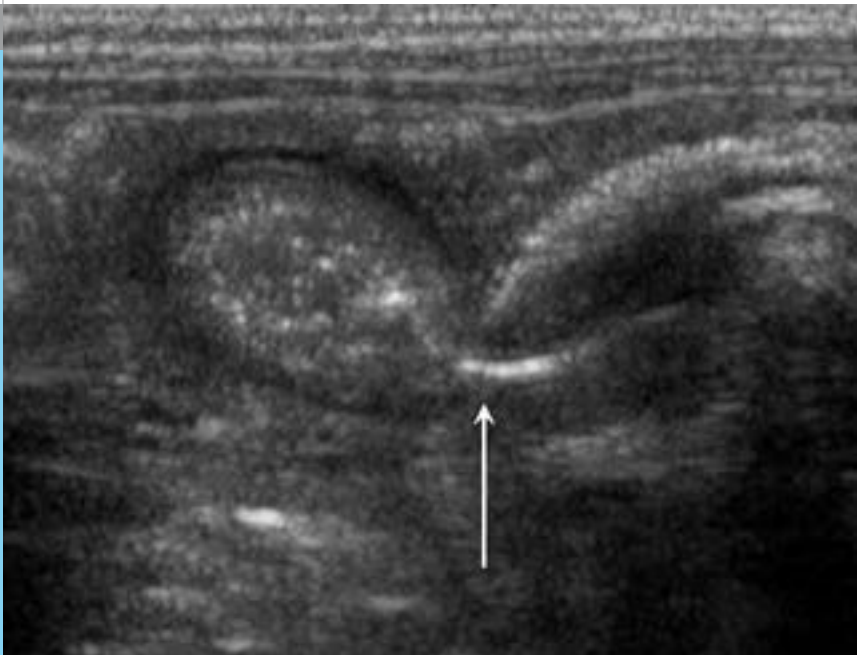

Fig. 8

Postnatal ultrasound: bowel loop (left) next to the cyst (right).

*Postnatal ultrasound:
air passing from bowel lumen to the cyst (arrow).*

Fig. 9



Enteral feedings were started on the first day of life and gradually increased without difficulties. Bowel movements were stimulated with rectal instillation of normal saline twice daily until the 4th day of life.

The diagnosis of cystic fibrosis was confirmed by an elevated sweat chloride concentration (222 mosmol/kg, normal value < 180 mosmol/kg) and a low pancreatic elastase-1 concentration in the stool (< 15 ug/g, normal value > 200 ug/g). Later, DNA analysis showed a DF508 mutation of the cystic fibrosis gene.

Meconium peritonitis is a rare complication with a suggested prevalence of 1 in 35'000 live births and a wide range of clinical presentations.

Meconium peritonitis is an inflammatory reaction induced by meconium extruding through a perforation of the fetal intestine into the peritoneal cavity. It is characterized by ascites, fibrosis, intraperitoneal calcifications and occasional cyst formation. Bowel perforations in utero are thought to be due to ischemic bowel lesions and have been associated with mechanical obstruction (intussusception, meconium ileus, anomalies of rotation and fixation, Meckel's diverticulum, internal hernia, atresia, volvulus), and viral infections (CMV or Parvovirus B 19). Meconium ileus is responsible for less than 25% of cases of meconium peritonitis.

DISCUSSION

Several obstructive bowel disorders are known to be correlated with cystic fibrosis. In one case series, cystic fibrosis was found in 100% (10/10) of patients with meconium ileus, in 43% (6/14) with meconium plug syndrome, but only in 7% (1/14) with meconium peritonitis (1). Nevertheless, all babies with meconium peritonitis should be tested to confirm or rule out cystic fibrosis.

Ultrasonographic features of meconium peritonitis (distended fetal bowel loops, meconium ascites, cystic masses, and polyhydramnios) may be seen as early as 13 weeks of gestation. Later, diffuse hyperechogenic punctuate echoes in the abdominal cavity, on the hepatic surface and in the scrotal sac are typical. If the inflammatory response remains localized a meconium pseudocyst with an irregular, calcified wall can be seen. Polyhydramnios occurs in approximately 50% of the patients. It thought to be caused by peristaltic deficiency and decreased swallowing activity.

Limited data from Dirkes et al. (3) suggest that only 20% of infants with meconium peritonitis will eventually require surgical management. Possible indications include: complex meconium peritonitis (meconium peritonitis associated with large meconium ascites), large pseudocysts, persistently dilated loops of bowel, postnatal bowel obstruction, persistent intestinal perforation and ileal atresia.

In our case, there were no clinical signs of peritonitis, passage of meconium was not delayed, and there was no bilious vomiting. Although there was some gas within the pseudocyst on ultrasonography suggesting some communication between the bowel lumen and the pseudocyst, this defect could not be demonstrated on a contrast study. Feedings were advanced at a normal rate without complications. Follow-up ultrasound examinations demonstrated progressive shrinking of the cyst and at the age of 12 months, the pseudocyst was no longer detectable.

1. Casaccia G, Trucchi A, Nahom A, Aite L, Lucidi V, Giorlandino C., Bagolan P. The impact of cystic fibrosis on neonatal intestinal obstruction: the need for prenatal/neonatal screening. *Pediatr Surg Int* 2003;19:75-78
2. Chan KL, Tang MH, Tse HY, Tang RY, Tam PK. Meconium peritonitis: prenatal diagnosis, postnatal management and outcome. *Prenat Diagn* 2005;25:676-682
3. Dirkes K, Crombleholme TM, CRAIG SD, Latchaw LA. The natural history of meconium peritonitis diagnosed in utero. *J Pediatr Surg* 1995;30:979-982

REFERENCES

SUPPORTED BY



CONTACT

Swiss Society of Neonatology

www.neonet.ch

webmaster@neonet.ch