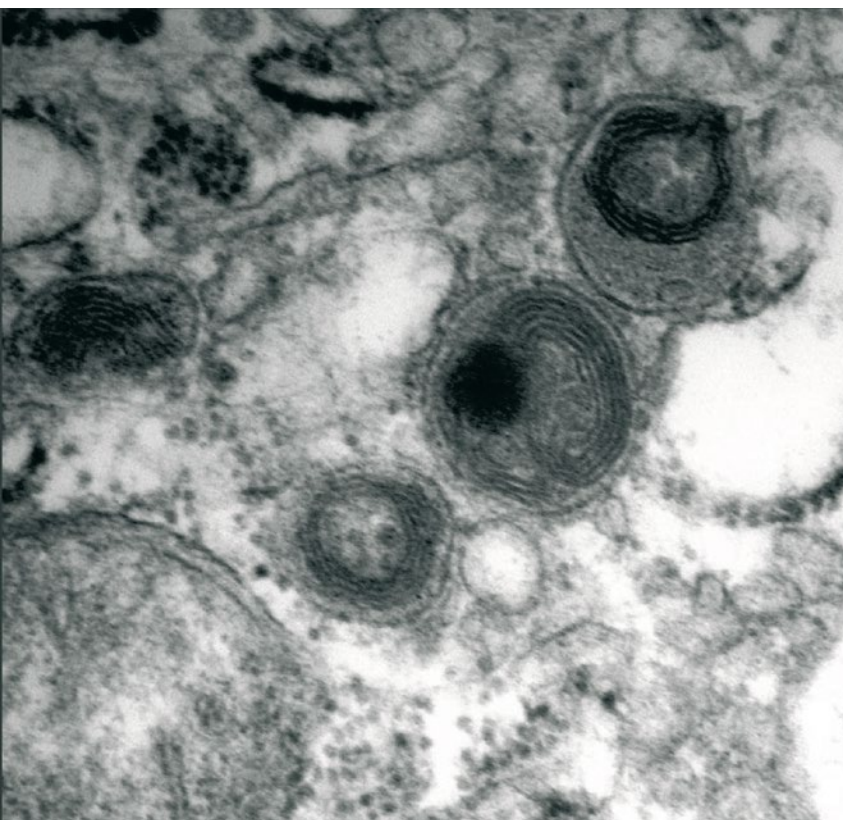


Fatal surfactant deficiency  
in two siblings caused by  
a novel *ABCA3* gene mutation

January 2008



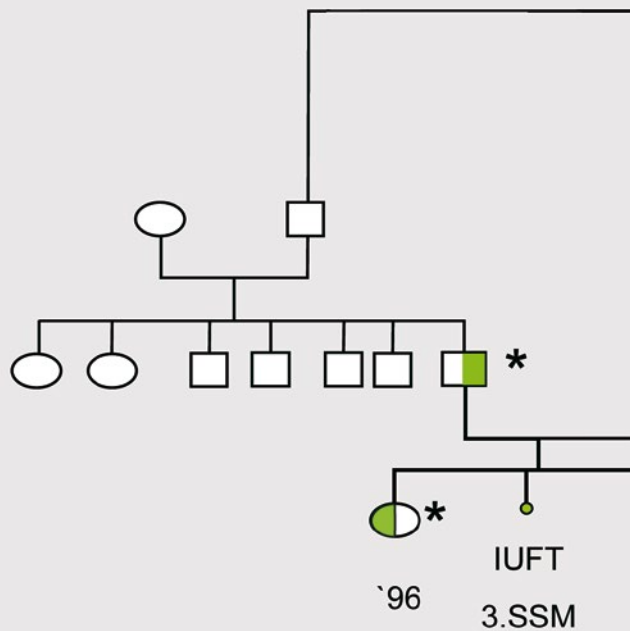
Hofmeister J, Bruder E, Aslanidis C, Hammer J, Schmitz G, Bühler C, Department of Neonatology (HJ, BC), University Children's Hospital of Basel, Institute of Pathology (BE), University Hospital of Basel, Institute for Clinical Chemistry (AC), Regensburg University Medical Center, Department of Pediatric Pneumonology (HJ), University Children's Hospital of Basel

Pulmonary surfactant lowers surface tension and prevents atelectasis at end-expiration. It is composed of phospholipids and proteins synthesized within type II cells. The mixture is packaged into specialized organelles called lamellar bodies which are extruded into the alveolar lumen by exocytosis.

A complex and tightly regulated cycle of synthesis, processing, transport, secretion, degradation, re-uptake or clearance and reprocessing involves both the phospholipids and protein components of pulmonary surfactant.

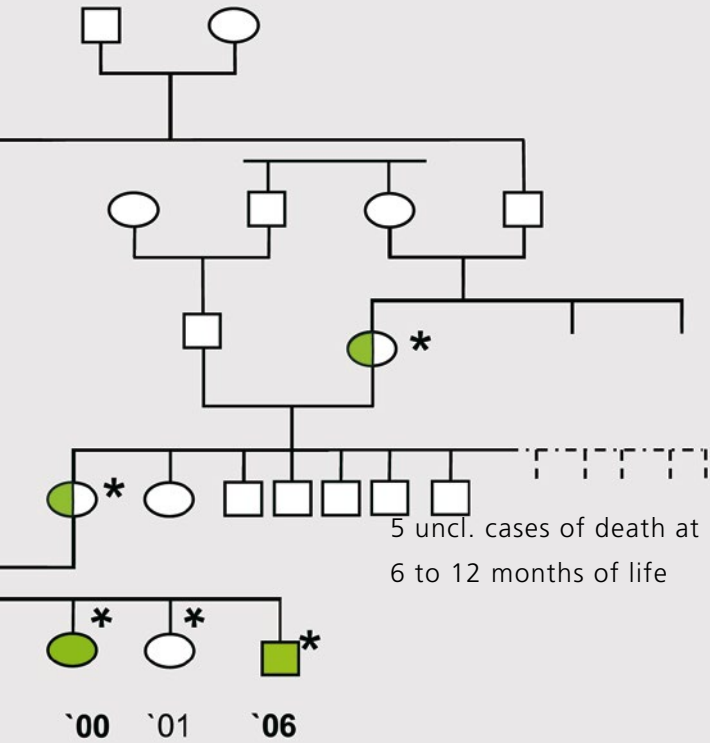
Defective synthesis of the essential surfactant component surfactant protein-B, or impaired lamellar body transport leads to fatal neonatal lung disease. At present, mutations in 2 genes, encoding surfactant protein-B (SP-B) or ATP binding cassette transporter family member ABCA3, have been shown to underlie fatal hereditary neonatal interstitial lung disease. While SP-B is indispensable for surfactant function, the lipid transporter ABCA3 targets surfactant phospholipids to the lamellar bodies and is necessary for lamellar body biogenesis, SP-B processing and lung development late in gestation (1). Here, we present the clinical course of two related infants who succumbed from severe hypoxemic respiratory failure caused by a novel mutation in the ABCA3 gene.

\* *ABCA3* gene was sequenced



**2000**, GA 41+1 weeks  
 weight 2620 g, Apgar 8/9/10  
 intubation on 4<sup>th</sup> day of life  
 died after 3 1/2 month

Fig. 1



**2006**, GA 40+6 weeks  
weight 3150 g, Apgar 9/9/8  
intubation on 3<sup>rd</sup> day of life  
died after 55 days

## CASE REPORTS

We report on two infants of an inbred Algerian family born after uneventful pregnancies in 2000 and 2006. There were also two healthy girls born to that family in 1996 and 2001 (Fig. 1).

The first case was a hypotrophic girl born after 41 weeks of gestation, birth weight 2620 g ( $P < 10$ ), height 45 cm ( $P < 10$ ) and head circumference 33 cm ( $P < 10$ ). She was born by secondary caesarean section because of decelerations and anhydramnios. The Apgar scores were 8, 9, 10 after 1, 5 and 10 minutes.

Respiratory distress became apparent a few hours after birth, and the baby was admitted to our neonatal intensive care unit. She first received nasal continuous positive airway pressure (CPAP), followed by mechanical ventilation via an endotracheal tube at 4 days of life by spontaneous intermittent mandatory ventilation (SIMV) or high frequency oscillatory (HFO) ventilation. In response to progressive respiratory failure,  $FiO_2$  was increased to 1.0. Inhaled nitric oxide (iNO), surfactant administration, prolonged steroid treatment and intravenous prostacyclin were all to no avail, and her pulmonary gas exchange worsened. On day 104 of life, she died of hypoxemic respiratory failure.

Chest X-rays revealed increasing diffuse reticular opacity of both lungs, mimicking respiratory distress syndrome (RDS) of premature infants with diffuse haziness and air bronchograms. A high resolution computed tomography in week 6 of life showed a diffuse interstitial

pneumopathy with reticular fibrosis and honeycombing on both sides. In week 7 of life an open lung biopsy was performed, revealing the histopathological hallmarks of alveolar proteinosis. Bronchioalveolar lavage (BAL) fluid contained immunologically reactive SP-B. Six years later, the family had another affected infant born spontaneously after 40 weeks of gestation. Birth weight was 3150 g (P10-50), height 50 cm (P10-50) and head circumference 34.5 cm (P10-50). Apgar scores were 9, 9, 8 after 1, 5 and 10 minutes. Within ten minutes of life, respiratory distress and cyanosis developed, and the boy was given supplementary oxygen and admitted to the NICU. As his deceased sister, he first received CPAP, then mechanical ventilation by endotracheal tube (day 3 of life). There was only temporary relieve following surfactant administration and inhaled NO. He died at 55 days of life of respiratory failure (Fig. 2A-E).

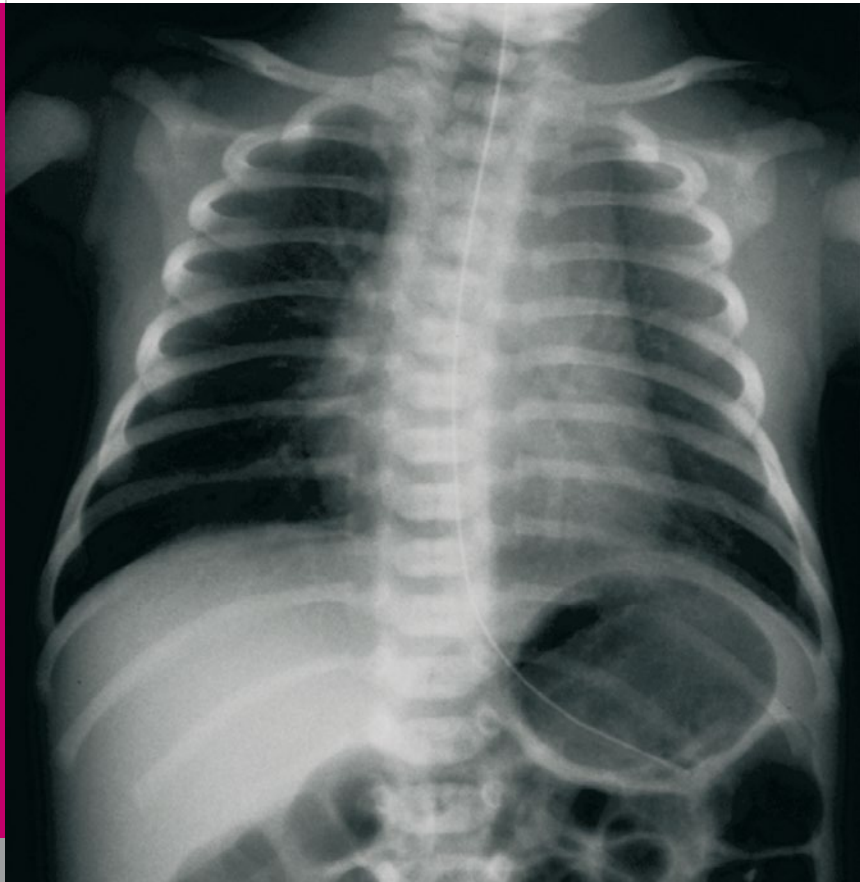


Fig. 2A

*Chest X-ray of the affected boy born in 2006: day 1 of life*



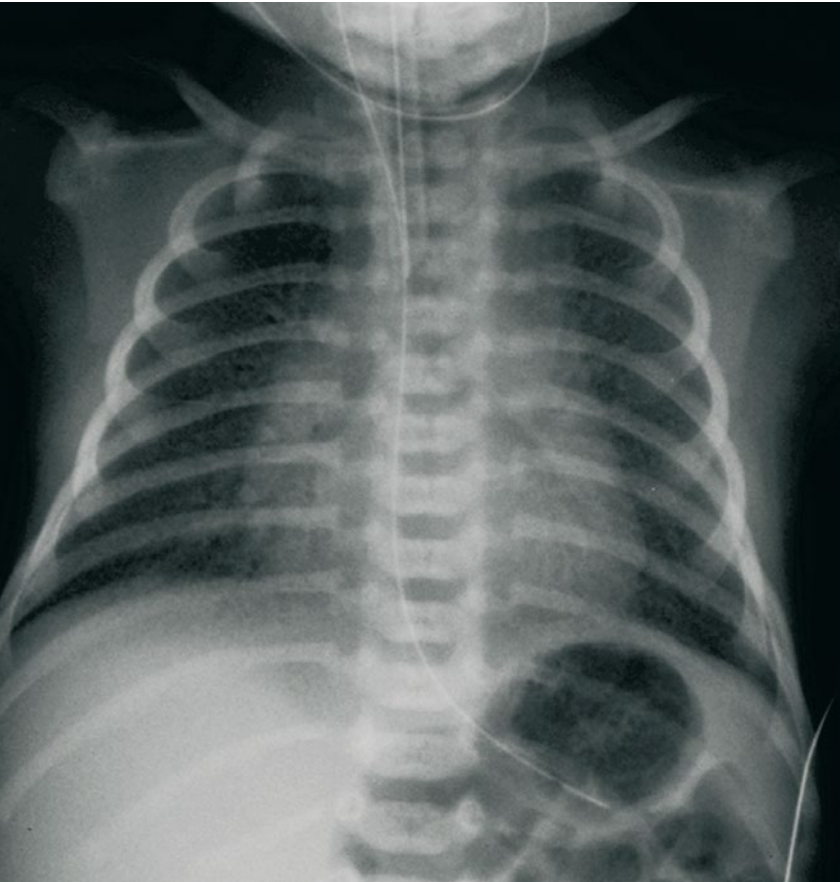


Fig. 2B

*Chest X-ray of the affected boy born in 2006: day 3 of life*

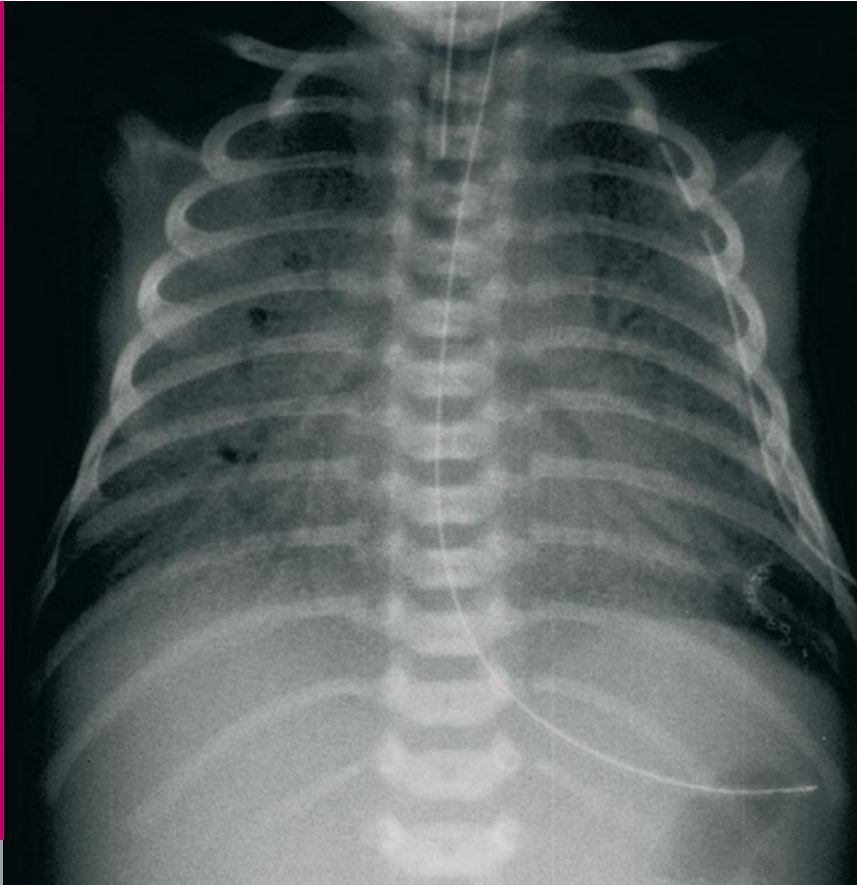


Fig. 2C

*Chest X-ray of the affected boy born in 2006: day 11 of life*

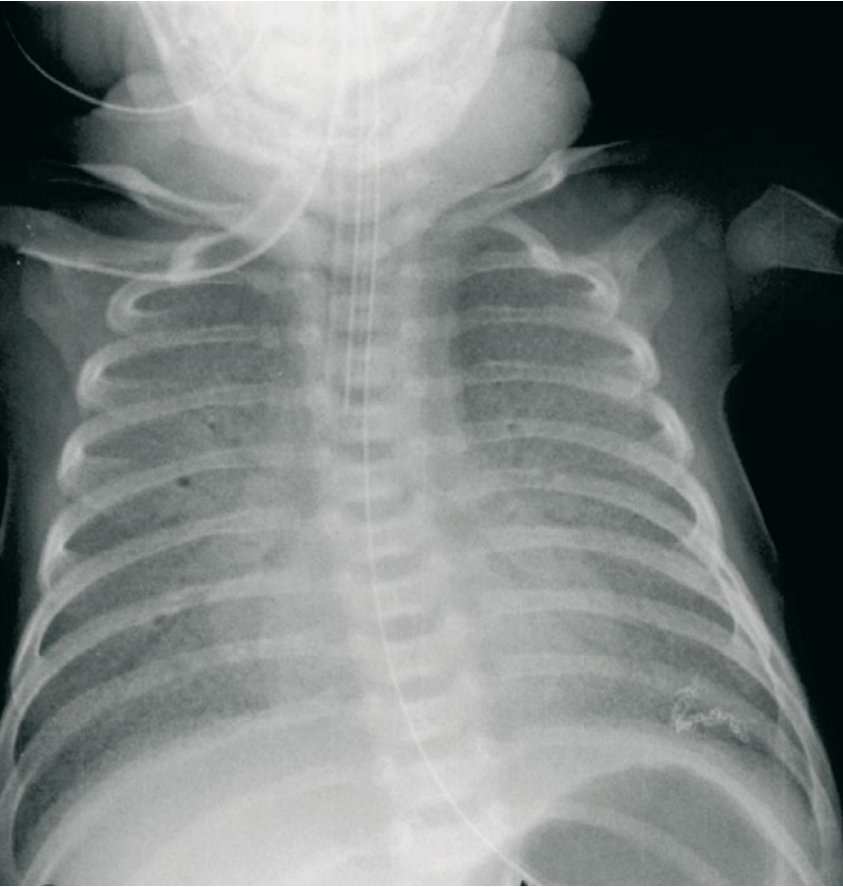


Fig. 2D

*Chest X-ray of the affected boy born in 2006: day 33 of life*

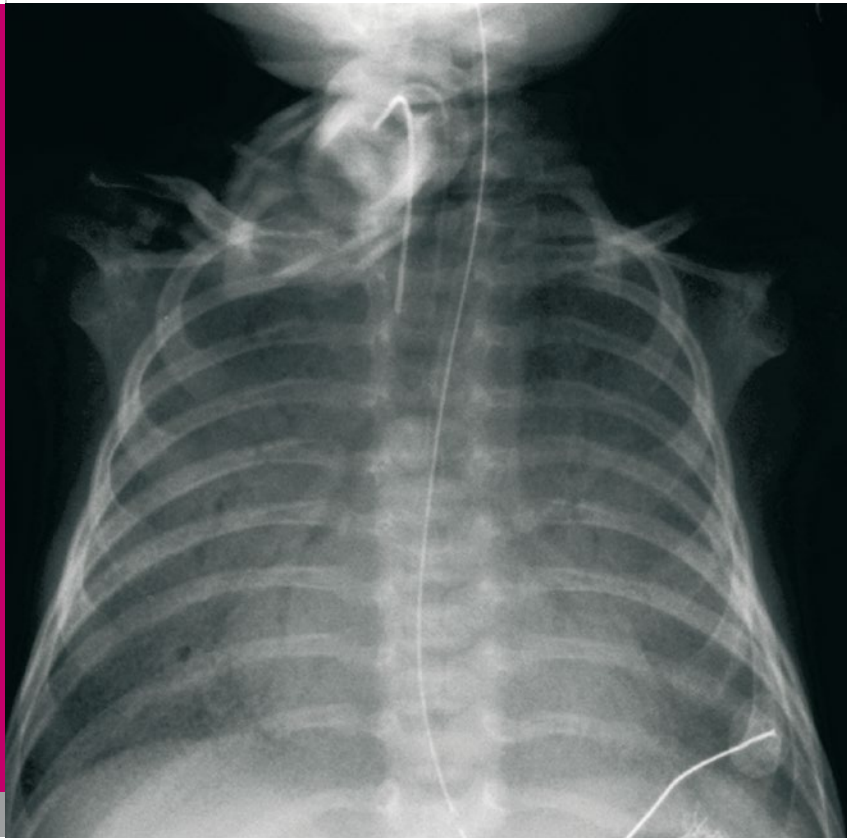


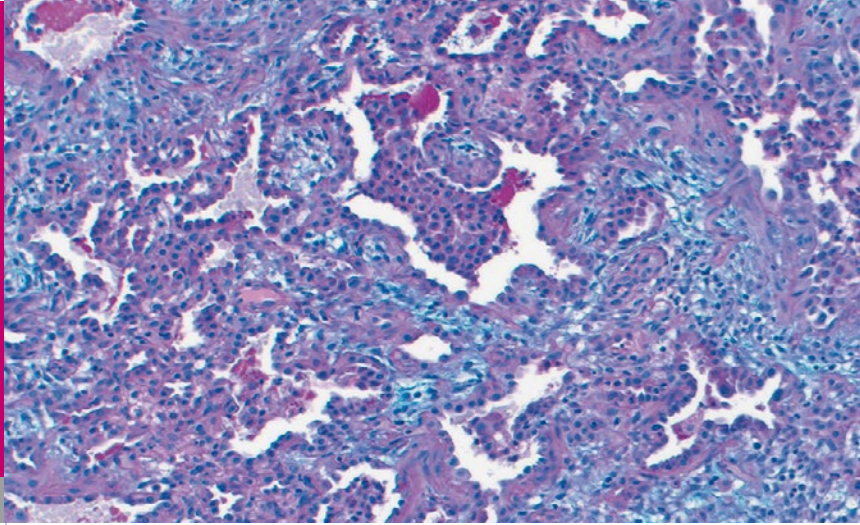
Fig. 2E

*Chest X-ray of the affected boy born in 2006: day 55 of life*

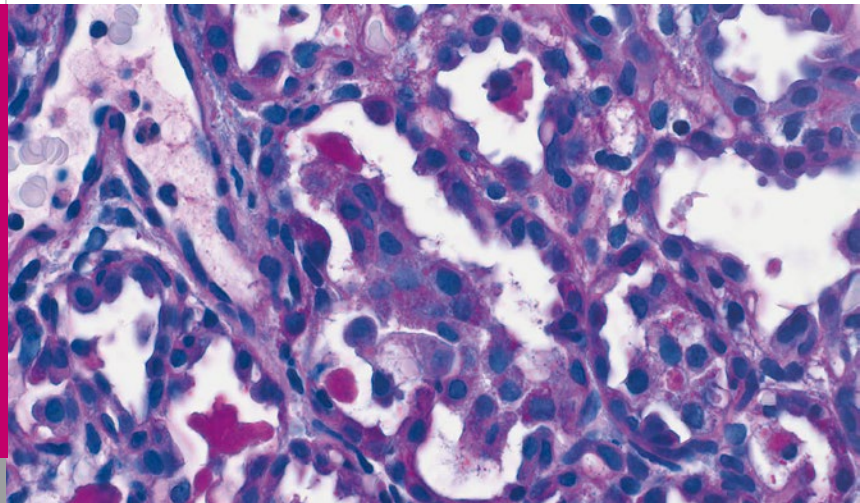
On day 11 of life, an open lung biopsy was done and the material went through histological, ultrastructural and histochemical examinations (Fig. 3, 4). On conventional light microscopy, there was marked interstitial fibrosis with widened interalveolar septa (Fig. 3A), type II pneumocyte hyperplasia and PAS-positive material in the alveoli (Fig. 3B).

Transmission electron microscopy showed rare cytoplasmic inclusions with concentric membranes and eccentrically placed electron-dense aggregates (Fig. 4). These „fried-egg“-appearing lamellar bodies differed both from normal lamellar bodies and the larger, poorly formed composite bodies with multiple vesicular inclusions observed in surfactant protein-B deficiency. Details of the ultrastructural findings are being described elsewhere (2).

Prompted by the ultrastructural finding, the ABCA3 gene was sequenced, which revealed a novel mutation in the 7th exon (578C>G) leading to an exchange of 193prolin to 193arginine. The patient was homozygous for this mutation, while both his parents, one of his phenotypical healthy sisters and one maternal grandmother were heterozygous. DNA extracted from paraffin-embedded tissue of his dead sister showed her to have been homozygous for the same mutation (Fig. 1).

**Fig. 3A**

*Histology of open lung biopsy specimen shows interstitial fibroplasia with widened interalveolar septa and collapsed alveoli.*

**Fig. 3B**

*Alcian Blue PAS stain demonstrates alveolar proteinosis (intraalveolar PAS-positive deposits) and type II pneumocyte hyperplasia.*

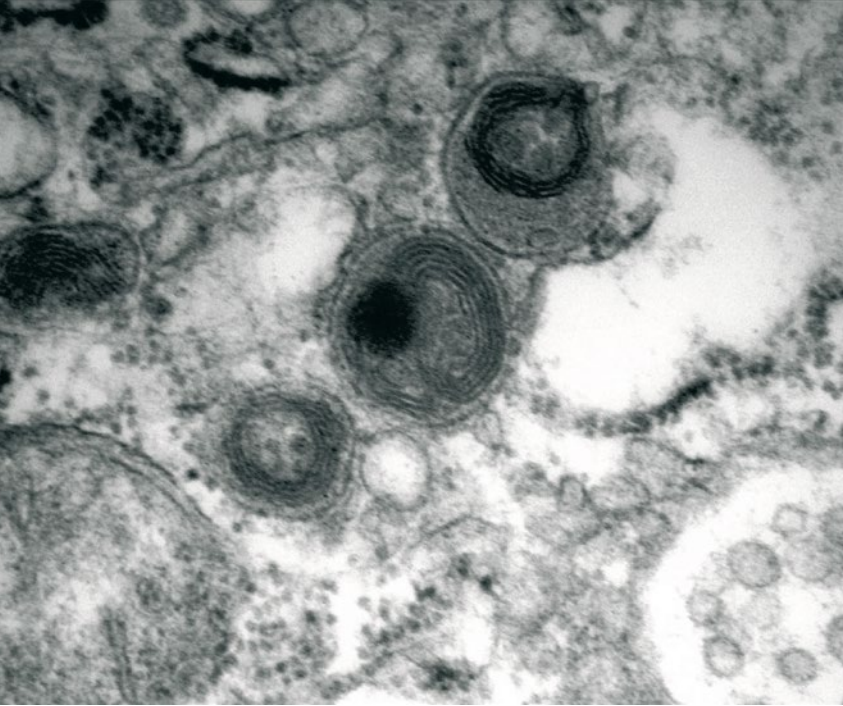


Fig. 4

*Transmission electron microscopy showing lamellar bodies with «fried egg» appearance*

## DISCUSSION

The clinical presentations of our two patients are typical for infants with loss-of-function mutations in SFTP-B or ABCA3 genes (3, 4). Because there is significant overlap in the clinical presentation of these inherited disorders of surfactant metabolism, a combined tissue-based and genetic approach to diagnosis is warranted.

Term newborns with unexplained respiratory distress syndrome who require mechanical ventilation for more than 5–7 days without apparent signs of improvement should be considered for evaluation, sooner if extracorporeal membrane oxygenation (ECMO) is used or if there is a family history of lung disease.

A lung biopsy helps to distinguish disorders of surfactant metabolism from other structural causes of lung disease such as alveolar capillary dysplasia (5). At the time of biopsy, tissue should be processed for electron microscopy to evaluate lamellar body morphology, and tissue should also be frozen in liquid nitrogen to be preserved for future molecular and proteomic analyses as new mechanisms of lung disease are identified.

Using electron microscopy with its ultrastructural hallmarks provides an important branch point in directing a more focused genetic evaluation. Disorganized or unrecognizable lamellar bodies and an accumulation of abnormal-appearing multivesicular bodies suggest SPB deficiency, while small lamellar bodies with electron-dense inclusions («fried-eggs») suggest ABCA3 de-



ficiency. ABCA3 deficiency, first described in 2004 as a cause of fatal interstitial lung disease in newborn infants (6), now appears to account for the majority of cases of hereditary fatal neonatal lung disease (7), and new disease-causing mutations continue to be discovered (8).

The availability of molecular diagnosis also permits genetic counseling for affected families in order to discuss the risks for future pregnancies and to convey the risks for other family members. In families in which a mutation has been previously identified, antenatal diagnosis can be established and permits advanced planning of a palliative regimen.

## REFERENCES

1. Cheong N, Zhang H, Muniswamy M, Zhao M, Yu K, Dodia C, Fisher AB, Savani RC, Shuman H. ABCA3 is critical for lamellar body biogenesis in vivo. *J Biol Chem* 2007 [Epub ahead of print]
2. Bruder E, Hofmeister J, Aslanidis C, Hammer J, Bubendorf L, Schmitz G, Rufle A, Bühner C. Ultrastructural and molecular analysis in fatal neonatal interstitial pneumonia caused by a novel ABCA3 mutation. *Mod Pathol* 2007 [in press]
3. Hamvas A, Cole FS, Noguee LM: Genetic disorders of surfactant proteins. *Neonatology* 2007;91:311-317
4. Noguee LM. Genetics of pediatric interstitial lung disease. *Current Opinion in Pediatrics* 2006;18:287-292
5. Brasch F, Brasch F, Schimanski S, Mühlfeld C, Barlage S, Langmann T, Aslanidis C, Boettcher A, Dada A, Schroten H, Mildnerberger E, Pruetter E, Ballmann M, Ochs M, Johnen G, Griese M, Schmitz G. Alteration of the pulmonary surfactant system in full-term infants with hereditary ABCA3 deficiency. *Am J Respir Crit Care Med* 2006;174:571-580
6. Shulenin S, Noguee LM, Annilo T, Wert SE, Whitsett JA, Dean M. ABCA3 gene mutations in newborns with fatal surfactant deficiency. *N Engl J Med* 2004;350:1296-1303
7. Somaschini M, Noguee LM, Sassi I, Danhaive O, Presi S, Boldrini R, Montrasio C, Ferrari M, Wert SE, Carrera P. Unexplained neonatal respiratory distress due to congenital surfactant deficiency. *J Pediatr* 2007;150:649-653
8. Saugstad OD, Hansen TW, Rønnestad A, Nakstad B, Tølløfsrud PA, Reinholt F, Hamvas A, Coles FS, Dean M, Wert SE, Whitsett JA, Noguee LM. Novel mutations in the gene encoding ATP binding cassette protein member A3 (ABCA3) resulting in fatal neonatal lung disease. *Acta Pædiatr* 2007;96:185-190



SUPPORTED BY



CONTACT

Swiss Society of Neonatology

[www.neonet.ch](http://www.neonet.ch)

[webmaster@neonet.ch](mailto:webmaster@neonet.ch)